

Case Reports

Stroke and Seizures as the Presenting Signs of Pediatric HIV Infection

Anannit Visudtibhan, MD*,
Pongsakdi Visudhiphan, MD*, and
Surang Chiemchanya, MD*

The authors report two pediatric patients with definite human immunodeficiency virus infection whose initial presentation was stroke and seizure. The first patient was a 3-year-old female who developed acute hemiparesis as the first manifestation. The other, a 2-month-old infant, had focal seizures secondary to cerebral infarction. Investigations revealed ischemic infarction of the thalamus, hypothalamus, and internal capsule in the first patient and cerebral cortex in the second. Further investigations failed to demonstrate any other causes of these cerebral infarctions. Opportunistic infection of the central nervous system was not documented. The authors emphasize that cerebrovascular accident may be the initial presentation in human immunodeficiency virus infection in children. Human immunodeficiency virus infection must be included in the differential diagnosis, and testing for the disease is mandatory in the investigation of stroke in any child who is at risk of having this infection. © 1999 by Elsevier Science Inc. All rights reserved.

Visudtibhan A, Visudhiphan P, Chiemchanya S. Stroke and seizures as the presenting signs of HIV infection. *Pediatr Neurol* 1999;20:53-56.

Introduction

Human immunodeficiency virus (HIV) infection is a devastating viral infection. It involves multiple organs and

clinical manifestations vary [1-4]. Neurologic manifestation may be caused either by direct infection of neural tissue by HIV or other opportunistic organisms [4-6] or by other pathophysiologic mechanisms, such as cytokine production [7]. Progressive encephalopathy consisting of seizures, microcephaly, and spasticity is usually the most common neurologic manifestation in children [3,5]. In Thailand, at Chiang Mai University, neurologic manifestation was found in 6.2% of children infected with HIV [8]. Acute stroke, caused by isolated or multiple ischemic infarcts, was found to be an infrequent complication in children infected with HIV [9-13]. However, none of these patients had stroke as the first presentation of the illness. The authors report two children infected with HIV who had stroke and seizure as the presenting signs.

Case Report

Patient 1. A 2-year-old female was referred to the authors' institution with a complaint of recurrent focal seizures. One month before the referral, she had developed weakness of the left arm and leg without associated signs. She was brought to a local hospital where conservative treatment was given. The motor function improved a few days later. She was able to ambulate independently, but the left foot dragged. One day before the referral, she had 3-4 episodes of focal seizures involving the left side of her face and left arm and leg, followed by a loss of consciousness lasting a few minutes. Her mother, the housewife of a truck driver, noticed that she had a low-grade fever, with mild upper respiratory symptoms, for a few days before this seizure. No significant change in her mental status had occurred until the onset of seizures. Her perinatal, past medical, and developmental histories were unremarkable.

The initial examination revealed a child with good consciousness, temperature 37.8-38.3°C, and blood pressure 130-140/90-100 mm Hg in all extremities. Her body weight, height, and head circumference were 15 kg, 96 cm, and 50 cm, respectively, all above the fiftieth percentile. Liver and spleen were within normal size ranges. No abdominal mass was palpated. Her lymph nodes were not enlarged. Neurologic examination disclosed mild weakness of the left side of her face, weakness of grade 3/5, with hyperreflexia and mild spasticity of the left arm and leg, sustained ankle clonus, and the presence of Babinski's sign bilaterally. No definite meningeal irritation sign was present.

The complete blood count revealed hemoglobin of 9.0 gm/dL, with 5,100 leukocytes (polymorphonuclear cells 81%, lymphocytes 18%, monocytes 1%). Peripheral blood smear demonstrated microcytic hypochromic red blood cells with an adequate amount of platelets. Normal hemoglobin typing was demonstrated by hemoglobin electrophoresis. Blood chemistry and liver function tests were within normal limits. Urinalysis was normal. Erythrocyte sedimentation rate was 117 mm/hr. Antinuclear antibodies, rheumatoid factor, and lupus cell preparation were all normal. Coagulation and protein C, protein S, and antithrombin

From the *Division of Pediatric Neurology; Department of Pediatrics; Faculty of Medicine; Ramathibodi Hospital; Mahidol University; Bangkok, Thailand.

Communications should be addressed to:
Dr. Visudtibhan; Department of Pediatrics; Faculty of Medicine;
Ramathibodi Hospital; Mahidol University; Bangkok 10400, Thailand.
Received April 27, 1998; accepted June 29, 1998.

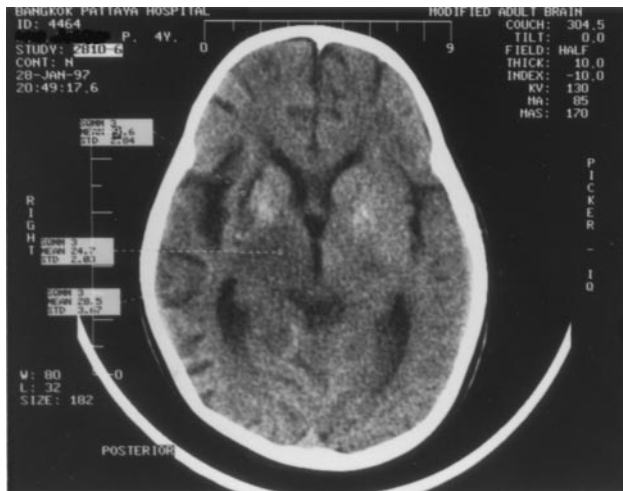


Figure 1. Computed tomography scan without contrast of the first patient demonstrated hypodensity of the right thalamus, hypothalamus, and the posterior limb of the right internal capsule, compatible with an acute infarction. Old infarction with calcification was evident at the bilateral basal ganglia. Diffuse cerebral atrophy was also present.

III levels were within normal limits. Antiphospholipid antibodies, including lupus anticoagulant and cardiolipin antibody, were negative. Multiple urinalyses were performed, which were unremarkable. The 24-hour urine vanillylmandelic acid was within the normal range. No abdominal mass was demonstrated by computed tomography (CT) scan, excluding neural tumor causing hypertension. IgM antibody to *Mycoplasma pneumoniae* was negative.

The lumbar puncture revealed clear cerebrospinal fluid (CSF), with normal open pressure, two mononuclear leukocytes, 270 erythrocytes, glucose 49 mg/dL, serum glucose 96 mg/dL, and protein 109 mg/dL. Routine Gram stain of CSF and bacteria culture were negative. HIV antibody was positive in this patient, as well as her mother.

CT of the brain, performed before the referral, demonstrated acute infarction of the right thalamus, right hypothalamus, and the posterior limb of the right internal capsule, old infarction, with calcification of bilateral basal ganglia, and cerebral atrophy (Fig 1).

Magnetic resonance angiography of the brain demonstrated irregularity and smaller size of the horizontal branch of the right middle cerebral artery (Fig 2).

Patient 2. A 2-month-old male infant with a history of multiple episodes of focal seizure affecting his right arm and leg and a loss of consciousness 1 week earlier, was referred from a provincial hospital. He was found to be irritable with icteric sclera and hepatosplenomegaly. A lumbar puncture was performed, which was unremarkable. He was then given phenobarbital along with other symptomatic treatment.

He was the only son of a 23-year-old housewife and a 30-year-old laborer who worked in a firearm factory—both parents declared a healthy medical history. He was born prematurely with a birth weight of 2,100 gm at the gestational age of 7 months. His perinatal history was unremarkable and he was discharged home a few days after birth.

On admission, his initial examination revealed a 2,800-gm male infant with normal vital signs who was awake. His head circumference and length were 37 cm and 50 cm, respectively. The anterior fontanel was open and slightly bulging with a measurement of 4 by 5 cm. He had pale conjunctiva and icteric sclera. His heart and lungs were normal. His liver was 5 cm below the right costal margin, with a span of 7 cm. His spleen was 4 cm below the left costal margin. His neurologic examination revealed an inactive child, without definite Moro reflex. Movements of the left upper and lower extremities were slightly less than the right. The rest of the examinations were unremarkable.

CT scan revealed hemorrhagic infarction of the right cerebral hemisphere, with acute intraparenchymal bleeding. Magnetic resonance imaging of the brain was done 6 days later and demonstrated subacute

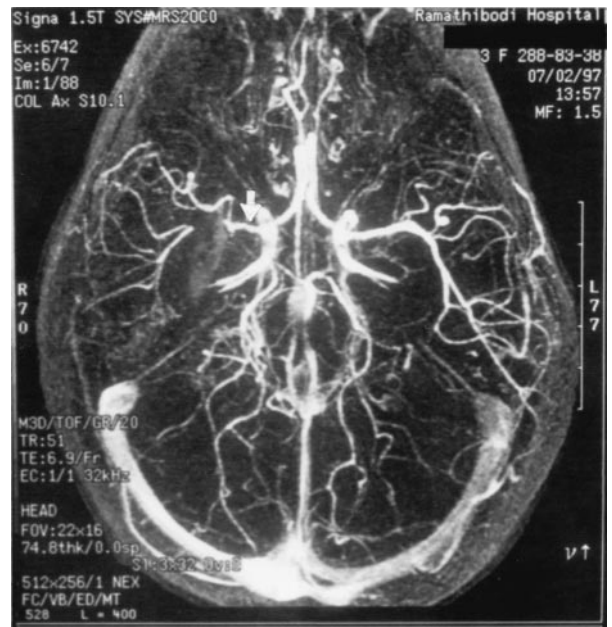

Figure 2. Magnetic resonance angiography of the brain of the first patient (TR = 51 ms, TE = 6.9/Fr) demonstrated irregularity and smaller size of the horizontal branch of the right middle cerebral artery (arrow).

hemorrhagic infarction of the area supplied by the right middle cerebral artery. Magnetic resonance angiography revealed a smaller size right middle cerebral artery and branches (Fig 3). The right internal carotid artery was also smaller than the left.

His blood tests (including complete blood count, blood chemistry, ethrocyte sedimentation rate), thyroid function tests, and coagulogram (including antithrombin III, protein C, and protein S levels) were all within normal limits.

His serologic tests revealed positive HIV antibody, as did polymerase chain reaction for HIV, 1:16 Venereal Disease Research Laboratory (VDRL) titer and reactive *Treponema pallidum* hemagglutination (TPHA). His CSF analysis disclosed open pressure of 23 cm H₂O, 4,080

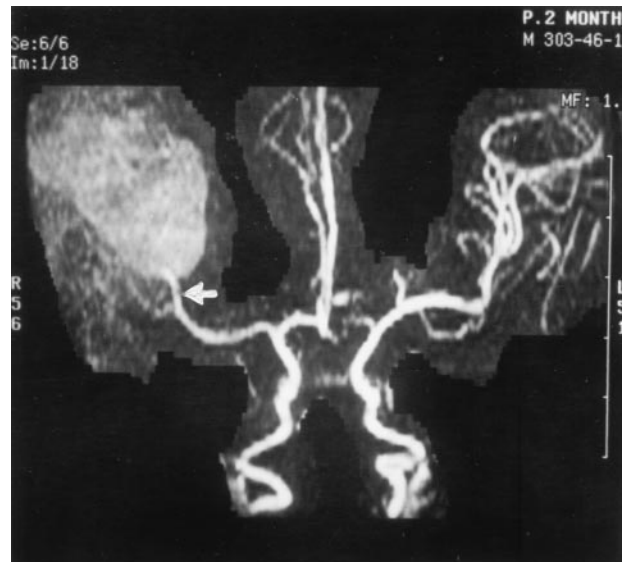


Figure 3. Magnetic resonance angiography of the brain of the second patient (TR = 51 ms, TE = 6.9/Fr) demonstrated smaller size of the right middle cerebral artery and its branches (arrow) compared with the left side. Hemorrhagic infarction was evident distally.

erythrocytes, 40 mononuclear leukocytes, protein 112 mg/dL, and normal CSF to serum glucose level and ratio. CSF VDRL was negative. His mother had a positive HIV test and 1:16 VDRL test. His father had a negative result for both tests.

Discussion

Neurologic manifestation of HIV infection caused either by complications of an opportunistic organism or direct HIV infection is an infrequent finding in children [1,2,4,14,15]. Progressive encephalopathy characterized by the presence of developmental delay, cognitive impairment, acquired microcephaly, and bilateral corticospinal tract signs was present in most patients studied [1,3-5,8, 14,16]. The clinical course was either rapidly progressive and fatal or indolent with plateaus [14,16]. Children with HIV infection appear to have an increased incidence of ischemic and hemorrhagic strokes [10,17]. An estimate of the clinical incidence of stroke in a clinical series noted a 1.3% per year incidence of symptomatic cerebrovascular disorders in children [12]. Ischemic infarction was present more frequently than hemorrhagic stroke and was reported in few studies [10,12,17]. Few instances of stroke have been reported in children with acquired immunodeficiency syndrome [12,13,16]. Acute hemiplegia in association with HIV infection was previously reported in a 15-month-old male who was known to be HIV positive since 5 months of age [11]. However, no patient with stroke as the first presentation was included in these reports [4,9, 10,12,13,16].

HIV infection was not documented in either of the authors' patients before the onset of neurologic manifestations. Their initial presenting signs were not typically found in studies of children with HIV previously reported. The mother of the first patient had not observed any delayed developmental milestones. No clue indicating impaired immune function was evident up to the onset of hemiparesis. Because of the unexplained hemiparesis, an extensive evaluation concerning causes of stroke was performed. Neither coagulopathy nor other possible cardiovascular causes of stroke, such as coarctation of aorta or cardiac embolism, was documented. Investigation for systemic vasculitis and autoimmune diseases were negative. No underlying metabolic disorder was found. Her urine vanillylmandelic acid was within normal limits, excluding certain neoplasms, such as neuroblastoma. Central nervous system infection by any other common and opportunistic organisms was not evident.

The second patient who had focal with secondarily generalized seizures and a bulging anterior fontanel was found to have extensive infarction of the brain. This infarction was a subacute lesion according to magnetic resonance imaging findings. However the imaging was performed more than 2 weeks after the onset of seizure. It is most likely that infarction occurred around the onset of seizure. No clue indicating other causes of stroke was present in this infant. Because of the nonreactive VDRL in

his CSF, cerebral infarction caused by treponema was unlikely.

The authors therefore conclude that stroke in both patients was most likely caused by HIV. However, it was not possible for the authors to postulate a specific pathogenesis for this ischemic infarction. The authors presume that it may be due to secondary vasculopathy caused by HIV. Multiple cerebral infarctions as a result of intimal proliferation or fibroplasia in cerebral arteries, suggesting a previous vasculitis caused by an opportunistic organism or varicella zoster virus, were demonstrated in other reported children [13] but not in the authors' patients. The authors were not able to demonstrate any evidence indicating direct infection caused by any opportunistic infection of the nervous system. Primary vascular abnormalities, such as aneurysmal arteriopathy characterized by aneurysmal dilatation and focal thrombosis of the arteries of the circle of Willis, was described in association with ischemic injury in an HIV-infected patient [17] but was not documented in these two patients. With the available tests, no evidence was present of an inflammation or infection that might be responsible for these ischemic events. Global hypoxic-ischemic encephalopathy [12] or emboli from foci of nonbacterial thrombotic endocarditis [17], the other two mechanisms of ischemic infarcts found in children infected by HIV, was not demonstrated in these patients. A direct involvement of the HIV causing arteriopathy of the vessel secondary to the infection may be one possible mechanism [18].

These two patients document that stroke may be the first clinical manifestation of HIV infection. Because HIV infection is a worrisome situation in endemic areas it is necessary to be aware of the existence of acute stroke as the first neurologic manifestation of HIV infection in children. The authors therefore emphasize that an HIV screening test is indicated and mandatory in every child who is at risk of having HIV infection and has a cerebrovascular accident without an explained cause.

References

- [1] **Belman AL.** AIDS and pediatric neurology. *Neurol Clin* 1990; 8:571-603.
- [2] **Epstein LG, Sharer L, Oleske J, et al.** Neurologic manifestations of human immunodeficiency virus infection in children. *Pediatrics* 1986;78:678-87.
- [3] **Indacochea FJ, Scott GB.** HIV-1 infection and the acquired immunodeficiency syndrome in children. *Curr Probl Pediatr* 1992;22: 166-204.
- [4] **Sirisanthana V.** Opportunistic infections in HIV-infected children at Chiang Mai University Hospital, Chiang Mai, Thailand. *J Infect Dis Antimicrob Agents* 1995;12:59-62.
- [5] **Epstein LG, Sharer LR, Goudsmit J.** Neurological and neuropathological features of human immunodeficiency virus infection in children. *Ann Neurol* 1988;23(Suppl):S19-23.
- [6] **Belman AL, Ultmann MH, Horoupian D, et al.** Neurologic complications in infants and children with acquired immune deficiency syndrome. *Ann Neurol* 1985;18:560-6.

- [7] **Gelbard HA**, Epstein LG. HIV-1 encephalopathy in children. *Curr Opin Pediatr* 1995;7:655-62.
- [8] **Sirisanthana V**. Demographic and clinical characteristic of symptomatic vertical HIV-infected children at Chiang Mai University Hospital. *J Infect Dis Antimicrob Agents* 1996;13:89-93.
- [9] **Mintz M**, Epstein LG, Koenigsberger MR. Neurological manifestations of acquired immunodeficiency syndrome in children. *Int Pediatr* 1989;4:161-71.
- [10] **Mintz M**, Epstein LG. Neurologic manifestations of pediatric acquired immunodeficiency syndrome: Clinical features and therapeutic approaches. *Semin Neurol* 1992;12:51-6.
- [11] **Kugler SJ**, Barzilai A, Hodes DS, et al. Acute hemiplegia associated with HIV infection. *Pediatr Neurol* 1991;7:207-10.
- [12] **Park YD**, Belman AL, Kim TS, et al. Stroke in pediatric acquired immunodeficiency syndrome. *Ann Neurol* 1990;28:303-11.
- [13] **Frank Y**, Lim W, Kahn E, Farmer P, Gorey M, Pahwa S. Multiple ischemic infarcts in a child with AIDS, varicella zoster infection, and cerebral vasculitis. *Pediatr Neurol* 1989;5:64-7.
- [14] **Walker AR**. HIV infections in children. *Emerg Med Clin North Am* 1995;13:147-62.
- [15] **Mintz M**. Clinical comparison of an adult and pediatric neuroAIDS. *Adv Neuroimmunol* 1994;4:207-21.
- [16] **Belman AL**, Diamond G, Dickson D, et al. Pediatric acquired immunodeficiency syndrome, neurologic syndromes. *Am J Dis Child* 1988;142:29-35.
- [17] **Burns DK**. The neuropathology of pediatric acquired immunodeficiency syndrome. *J Child Neurol* 1992;7:332-46.
- [18] **Joshi VV**, Pawel B, Conner E, et al. Arteriopathy in children with acquired immune deficiency syndrome. *Pediatr Pathol* 1987;7:261-75.