

### References

1. Branthwaite MA: Neurological damage related to open-heart surgery: A clinical survey. *Thorax* 27: 748-753 (Nov) 1972
2. Tufo HM, Ostfeld AM, Shekelle R: Central nervous system dysfunction following open-heart surgery. *JAMA* 212: 1333-1340 (May) 1970
3. Assad-Morell JL, Frye RL, Connolly DC, et al: Aorta-coronary artery saphenous vein bypass surgery: Clinical and angiographic results. *Mayo Clin Proc* 50: 379-386 (Jul) 1975
4. Sheldon WC, Grinfeld L: Direct myocardial revascularization: Venous autograft technique; postoperative assessment. *Surg Clin North Am* 51: 1043-1049 (Oct) 1971
5. Vukov J, Wayne E: Ocular complications after coronary bypass surgery. Presented at the meeting of the American Medical Association, Section on Ophthalmology, Atlantic City, New Jersey, June 14 to 19, 1975
6. Gutman FA, Zegarra H: Ocular complications in cardiac surgery. *Surg Clin North Am* 51: 1095-1103 (Oct) 1971
7. Branthwaite MA: Prevention of neurological damage during open-heart surgery. *Thorax* 30: 258-261 (Jun) 1975
8. Grondin CM, Lespérance J, Bourassa MG, et al: Serial angiographic evaluation in 60 consecutive patients with aorto-coronary artery vein grafts 2 weeks, 1 year, and 3 years after operation. *J Thorac Cardiovasc Surg* 67: 1-6 (Jan) 1974

## Angiographical Extravasation of Contrast Medium in Hemorrhagic Infarction

### Case Report

TADAYOSHI IRINO, M.D., MAMORU TANEDA, M.D., TAKAO MINAMI, M.D.,  
AND YOSHIO MURATA, M.D.\*

**SUMMARY** Leakage of the contrast medium was noted on angiograms of a patient whose autopsied brain disclosed typical pathological findings of hemorrhagic infarction. The case was a 63-year-old woman with mitral valve failure, who suddenly had loss of consciousness and right-sided hemiplegia. The left carotid angiography performed six hours after onset demonstrated middle cerebral arterial axis occlusion, and the second angiography performed three days after onset displayed recanalization of the initially occluded

artery as well as extravasation of the contrast medium. Fourteen days after onset the patient died and an autopsy was performed. The brain demonstrated perivascular punctate hemorrhages in the area supplied by the middle cerebral artery, and neither hematoma nor microaneurysm was disclosed pathologically.

A short discussion is given on the possible relationship between recanalization and hemorrhagic infarction. The clinical assessment of hemorrhagic infarction has not been established successfully.

**ANGIOGRAPHICAL EXTRAVASATION** of the contrast medium in various kinds of intracranial hemorrhagic lesions has been reported previously by many authors regarding cases of hypertensive intracerebral hemorrhage,<sup>1</sup> ruptured aneurysm,<sup>2</sup> or arteriovenous malformation,<sup>3</sup> and epidural hematoma.<sup>4</sup> However, as yet, no cases have been described concerning angiographical extravasation in patients with occlusive cerebrovascular diseases, in spite of the fact that hemorrhagic infarction develops frequently in the clinical course of such patients.<sup>5</sup> The present case demonstrated leakage of the contrast medium on the angiograms obtained after spontaneous recanalization of the occluded middle cerebral arterial axis, and the autopsied brain displayed typical hemorrhagic infarction in the infarcted area. We believe this case represents the first angiographical demonstration of extravasation in hemorrhagic infarction.

### Case Report

A 63-year-old woman had a history of chronic heart disease associated with mitral valve failure for more than ten years previously. She was doing fairly well until she suddenly lost the use of her right arm and leg and within 30 minutes had some confusion. On arrival at the hospital by ambulance three hours after the onset, she was somnolent and somewhat restless, with motor and sensory aphasia and right-sided hemiplegia. Her blood pressure was 140/90 mm Hg and her pulse was 68 and irregular. External evaluation showed no injuries. Physical examination revealed a complete right hemiplegia with a central facial palsy and aphasia and positive Babinski sign. The arm and leg were equally paralyzed, and only a slight degree of motion was preserved in the shoulder and the hip joints. Pinprick sensation was diminished on the right, but other sensory modalities seemed to be intact. Auscultation of the heart disclosed diastolic rumbling and the ECG showed atrial fibrillation, suggesting the presence of mitral stenosis. The ocular fundi showed no papilledema. Lumbar puncture showed colorless CSF and the pressure was 140 mm H<sub>2</sub>O. Serial left carotid arteriography, using 7 ml of 60% Amidotrizoate, demonstrated occlusion of the middle cerebral artery of its proximal por-

Division of Cerebrovascular Diseases, Hanwa Hospital, 3-95, Minami-sumiyoshi-cho, Sumiyoshi-ku, Osaka, 558, Japan.

\*Division of Pathology, Osaka Prefectural Hospital, 4-25, Mandai-higashi, Sumiyoshi-ku, Osaka, 558, Japan.

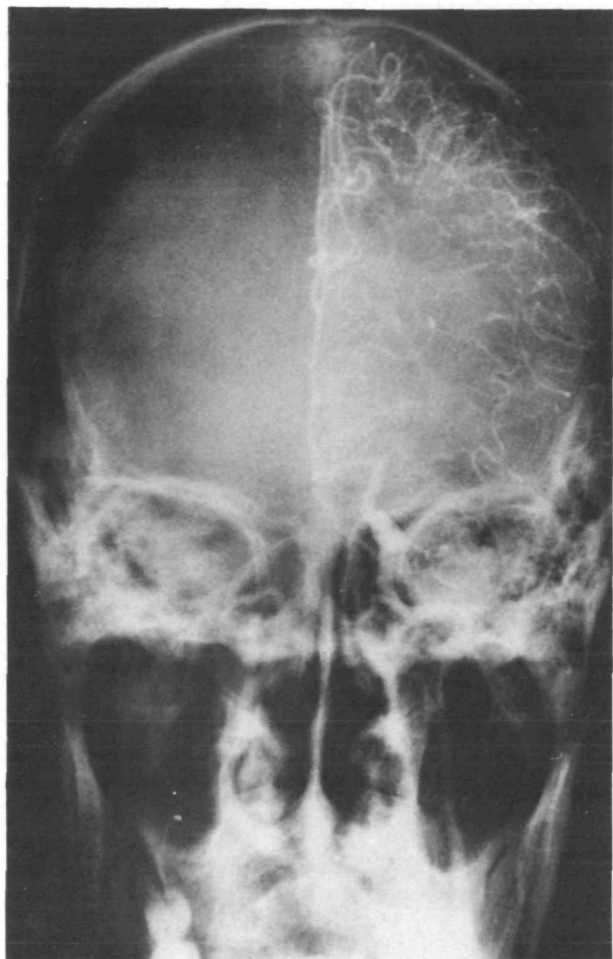


FIGURE 1. Left carotid angiogram (AP view) at six hours after ictus shows occlusion of the middle cerebral artery of its proximal portion.

tion (fig. 1). The diagnosis of embolism of the middle cerebral artery originating from the heart was made. She was treated conservatively, and fibrinolytic agents were not used.

On the third day, lumbar puncture and left carotid angiography were repeated. The pressure of the CSF was 120 mm H<sub>2</sub>O and the appearance was sanguinous. The angiograms demonstrated recanalization of the middle cerebral artery and widespread narrowing of the caliber (fig. 2a). Moreover, leakage of the contrast medium from a lenticulostriate artery (shown in figs. 2b and c) was noted. A capillary blush also was demonstrated in the territory of the lenticulostriate arteries and cortical branches of the middle cerebral artery (fig. 2d). Shift of the midline structures was noted at this time. On the lateral view obtained about ten minutes after AP angiography, the extravasation was poorly demonstrated (fig. 3).

During her life, the neurological deficits did not show remarkable improvement, while consciousness gradually improved day by day. Cardiac failure developed progressively and she died of heart failure on the fourteenth day after onset.

A complete autopsy was performed. Examination of the brain disclosed the presence of perivascular miliary punctate hemorrhages in the distribution of the middle cerebral artery, especially in the basal ganglia. No solid hematoma as seen in cases of hypertensive hemorrhage was present. Neither microaneurysms nor arteriovenous malformations were demonstrated pathologically. The autopsied brain is shown in figure 4. The heart displayed mitral stenosis and a large thrombus was found on the left atrial wall.

### Discussion

It is a well-known fact that spontaneous recanalization of an occluded artery, as shown in this case, frequently occurs in cerebral infarction, especially in cases of cerebral embolism associated with atrial fibrillation.<sup>6, 7</sup> However, as yet, the influence of recanalization on the prognosis has not been discussed thoroughly in the literature. On the other hand, some circumstances favoring the development of hemorrhagic infarction are known by experimental and pathological observations, and it has been said that this pathological change develops after complete ischemia, when circulation is restored before the tissues become completely necrotic.<sup>5, 8</sup> Therefore, it might be reasonable to presume that the angiographically demonstrated circulatory restoration after recanalization in the present case participated in the development of hemorrhagic infarction.

The pathological findings of hemorrhagic infarction differ from other types of intracerebral hemorrhages by fine, punctate hemorrhages of the infarcted cortex or gray nuclei.<sup>9</sup> This autopsied brain displayed typical findings of hemorrhagic infarction, and neither hematoma nor microaneurysm (which were not infrequently seen in cases of intracerebral hemorrhage) was noted.<sup>10</sup> Thus, the cause of the present extravasation would have been damaged endothelium, allowing a diapedesis of erythrocytes as well as leakage of contrast medium.

In the present case, leakage of the contrast medium was much more apparent in AP views than in lateral views. It might be because AP and lateral views were not obtained at the same time, or because the detection of the extravasation was easier in the AP views especially in the present case. Anyway, it is assumed that the extravasation of the present case with hemorrhagic infarction was less notable than those of the reported cases of hypertensive intracerebral hemorrhage.<sup>1</sup>

Although hemorrhagic infarction has been surveyed through a large number of experimental and pathological investigations, the clinical assessment of hemorrhagic infarction has not been established successfully. Angiographical demonstration of the extravasation in hemorrhagic infarction has never been reported previously.

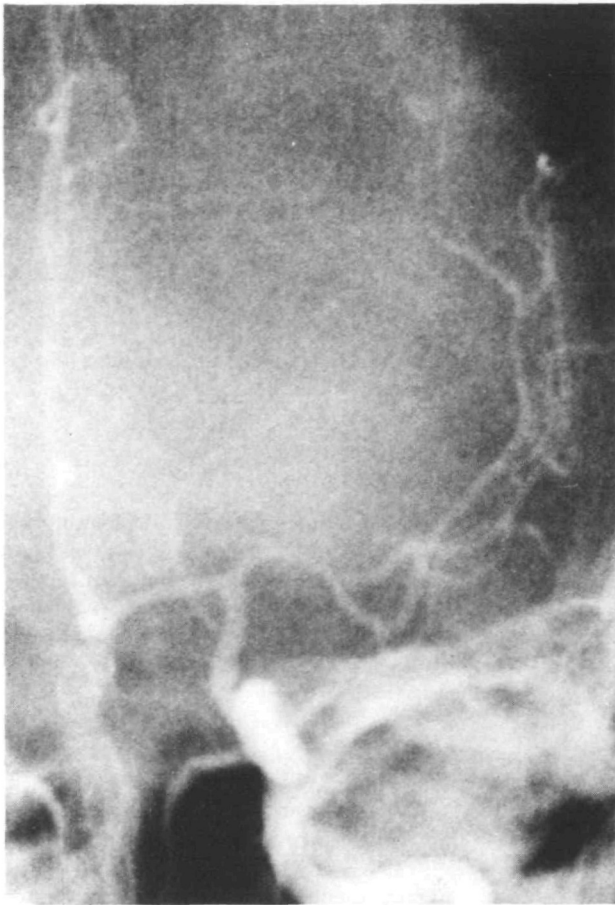

FIGURE 2a

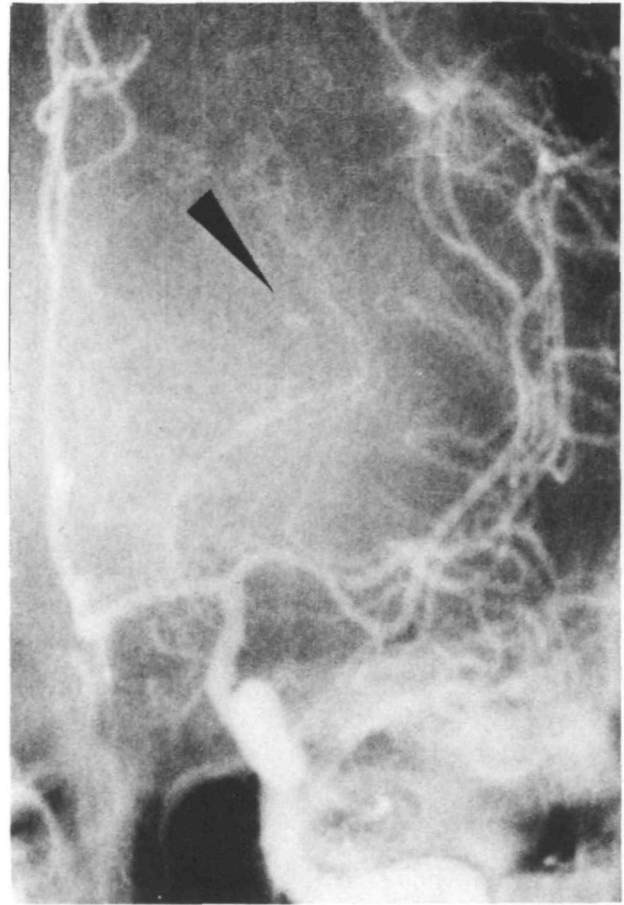


FIGURE 2b

FIGURE 2. Serial left carotid angiograms on the third day after ictus (AP view) demonstrated recanalization. Pictures taken two seconds (a), three seconds (b), five seconds (c), and seven seconds (d) after injection of contrast medium are illustrated. Figures 2b and c demonstrate extravasation (arrow) of contrast medium from a lenticulostriate artery.

#### Acknowledgment

We wish to express our thanks to Kazuo Hara, M.D., Masahiro Mizukami, M.D., and Koichi Yamaguchi, M.D., for much guidance in this report.

#### References

1. Mizukami M, Araki G, Mihara H, et al: Arteriographically visualized extravasation in hypertensive intracerebral hemorrhage. *Stroke* 3: 527-537, 1972
2. Murphy DJ, Goldberg RJ: Extravasation from an intracranial aneurysm during carotid angiography. Case report. *J Neurosurg* 27: 456-461, 1967
3. McLennan JE, Rosebaum AE, Hedley-Whyte ET, et al: Angiographic visualization of fatal hemorrhage from a cerebral arteriovenous malformation. Case report. *J Neurosurg* 41: 622-626, 1974
4. Helmer FA, Sukoff MH, Plaut MR: Angiographic extravasation of contrast medium in an epidural hematoma. Case report. *J Neurosurg* 29: 652-654, 1968
5. Fisher M, Adams RD: Observations on brain embolism with special reference to the mechanism of hemorrhagic infarction. *J Neuropath Exp Neurol* 10: 92-94, 1951
6. Bladin PF: Radiologic and pathologic study of embolism of the internal-middle cerebral arterial axis. *Radiology* 82: 615-625, 1965
7. Irino T, Taneda M, Minami T: Positive scans in angiographically proved cases of recanalized cerebral infarction. *Stroke* 6: 132-135, 1975
8. Harvey J, Rasmussen T: Occlusion of the middle cerebral artery. An experimental study. *Arch Neurol Psychiat* 66: 20-29, 1951
9. Zülch KJ: Hemorrhage, thrombosis, embolism. In Minckler J (ed): *Pathology of the Nervous System*. New York, McGraw-Hill, vol 2, 1971
10. Cole FM, Yates PO: Intracerebral microaneurysms and small cerebrovascular lesions. *Brain* 90: 759-768, 1967

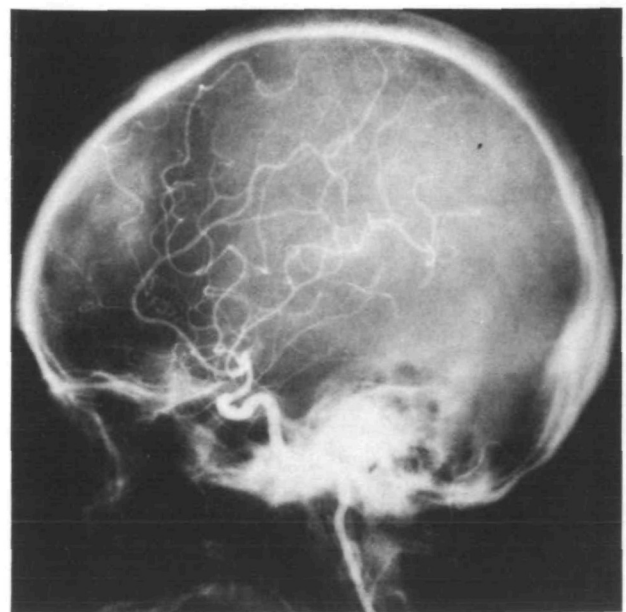


FIGURE 3. The lateral view obtained about ten minutes after AP angiography. The extravasation was poorly demonstrated.

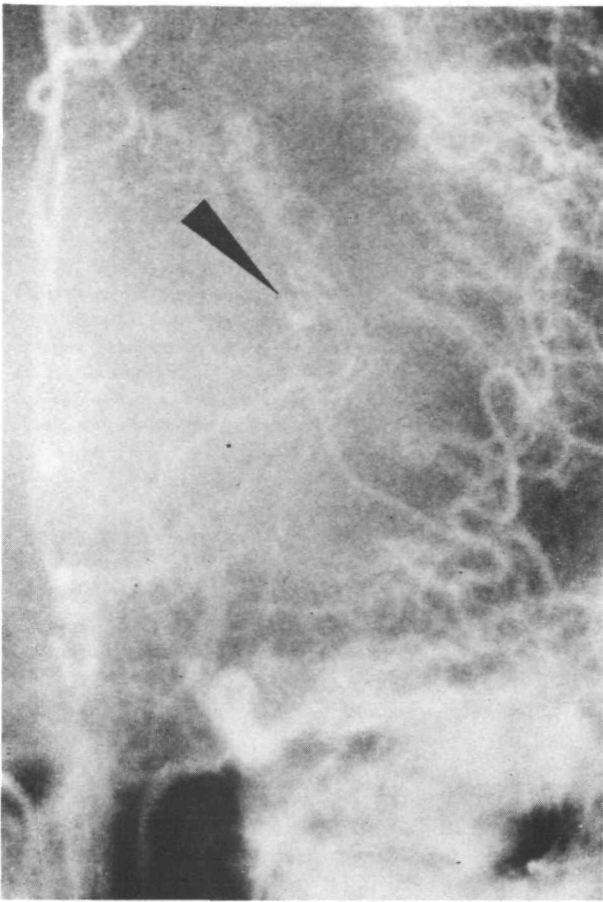


FIGURE 2c

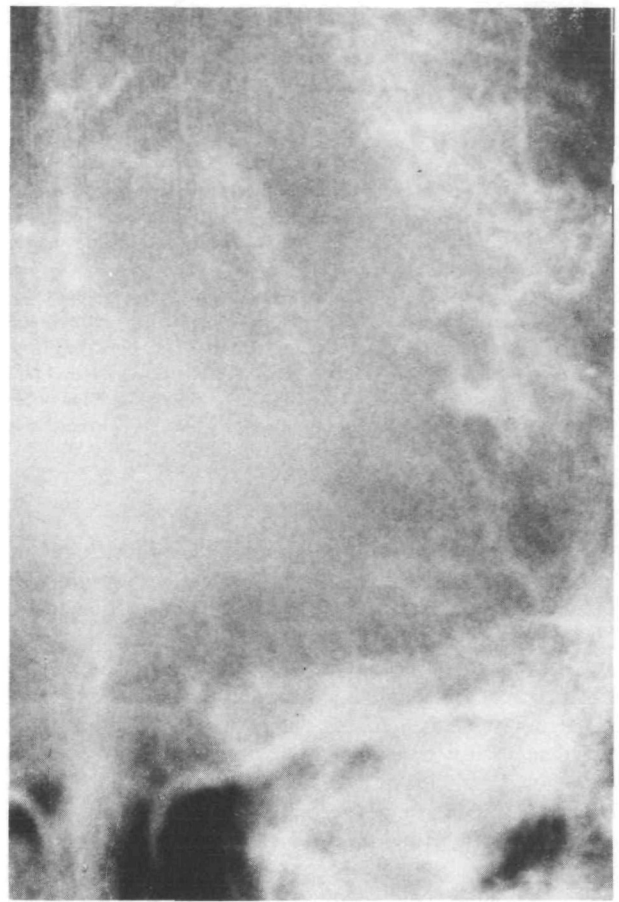
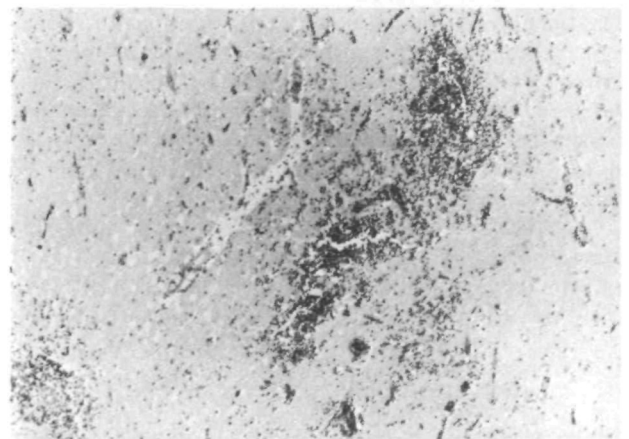
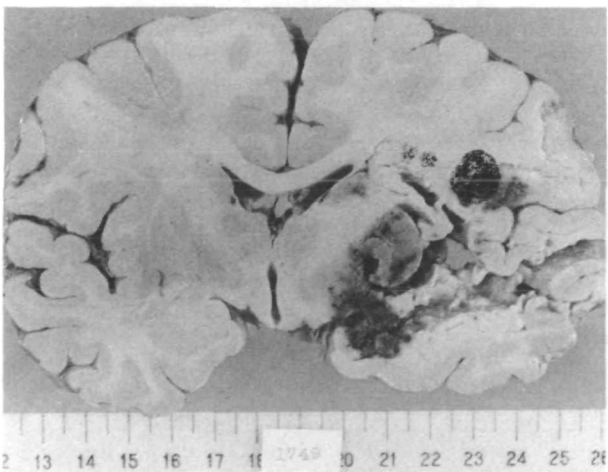


FIGURE 2d



FIGURES 4a and b. *The autopsied brain: medium-sized hemorrhagic infarction was demonstrated in figure 4a. Figure 4b shows the perivascular punctuate hemorrhages in the area supplied by lenticulostriate and anterior choroidal arteries. X40, H & E stain.*