

Subcortical Arteriosclerotic Encephalopathy (Binswanger's Disease)

A Vascular Etiology of Dementia

PETER C. BURGER, M.D., J. GORDON BURCH, M.D., AND ULF KUNZE, M.D.

SUMMARY A 51-year-old man with moderate intermittent hypertension had a rapidly progressive, profound dementia in the absence of significant localizing neurological signs. Postmortem examination disclosed the vascular alterations and diffuse white matter degeneration

which characterize subcortical arteriosclerotic encephalopathy (SAE) or Binswanger's disease. The case underscores the need to consider vascular disease as an etiology of dementia — even in the absence of focal neurological deficit.

BEDSIDE CONSIDERATION of cerebrovascular disease as an etiology of dementia has been deemphasized somewhat in recent years in favor of disorders such as Alzheimer's disease, slow virus infections, and normal pressure hydrocephalus. Cerebrovascular disease, nevertheless, is common and may be responsible for clinical conditions in which dementia is a leading aspect. Vascular dementias are usually engendered by extensive cortical softenings,^{1, 2} but on occasion are derived from the diffuse white matter degeneration of subcortical arteriosclerotic encephalopathy (SAE) or Binswanger's disease.³⁻¹² This report documents the clinical and pathological features of a patient with this unusual cerebrovascular disorder, and emphasizes that vascular disease must be included in the differential diagnosis of dementia, even in the absence of localizing neurological signs.

Case Presentation

Clinical History

A 51-year-old man (accountant) was hospitalized at the Durham Veterans Administration Hospital on six occasions in one year because of progressive dementia.

The patient's initial neurological difficulties were noted by his wife in June, 1971, as the gradual onset of personality change characterized by apathy, easy fatigability, decreased recent and remote memory, and difficulty in business judgments. These mental aberrations were reported to be accompanied by episodic ataxia, intermittent dysarthria, deterioration of handwriting, and decreased right-sided coordination. Two hospitalizations at other institutions revealed a left frontal slow-wave EEG focus, an elevated CSF protein (65 mg/dl), and unremarkable left carotid arteriography.

At the patient's first Durham VA hospitalization in March, 1972, a state of psychomotor retardation was noticed and, although there were positive snout and suck reflexes, the clinical impression was depression as supported by psychological testing. A lumbar tap was unremarkable; the opening pressure was 150 mm H₂O.

The patient's second admission seven days later was prompted by a 48-hour period of confusion, incontinence, ataxia, and agitated delirium with disorientation and incoherent speech. There were no focal or lateralizing neuro-

logical deficits. The opening pressure at lumbar puncture was 160 mm H₂O and the CSF protein was 57 mg/dl. An extensive investigation was undertaken to elucidate the etiology of the patient's dementia. Negative examinations included the following: chest x-ray, ECG, blood and CSF chemistries, urine porphyrin screen, bone marrow aspirate, gastric aspirate for pH and cytology, LE prep and anti-nuclear factor, toxic screen for hypnotic and tranquilizing agents, upper GI series, barium enema, intravenous pyelography, liver scan, skull x-ray, two brain scans, and CSF studies for serologic evidence of fungi and viruses, cytological abnormalities, and the presence of infectious agents. Sequential EEGs revealed diffuse deterioration of the background activity (fig. 1), while radioactive serum albumin (RISA) cisternography showed ventricular reflux, delayed clearance, and absence of sagittal activity after 24 and 48 hours (fig. 2). Pneumoencephalography demonstrated marked ventricular dilatation and minimal free-convexity air (fig. 3). There were minor irregularities of the siphon and proximal anterior cerebral arteries on left carotid arteriography, but the study was otherwise unremarkable. Repeated CSF drainage by lumbar puncture appeared to improve the patient's condition somewhat, although there was no further improvement after the insertion of a ventriculovenous shunt. The opening pressures at the time of these taps were within normal limits. Light and electron microscopic examination of a cortical biopsy containing gray matter and 1 mm of subcortical white matter from the right parieto-occipital region revealed no abnormalities of the parenchyma or vasculature.

The patient's blood pressure was intermittently elevated during the first two hospitalizations with diastolic recordings up to 150 mm Hg, although there were no clinical or radiographical manifestations of hypertensive disease or historical documentation of hypertension. Serial serum electrolytes were normal. The plasma renin level was low, while vanilmandelic acid and catecholamine determinations were normal. The patient's hypertension was initially treated with alpha-methyldopa while hydrochlorothiazide alone later provided adequate control.

During the two months following discharge there was a progressive deterioration as the patient became incontinent and increasingly dependent on others for his daily care.

On his third admission in August, 1972, he was completely disoriented, mumbled incoherently in a low voice, and exhibited frontal release signs, ataxia, bilateral plantar extensor responses, and a mild left hemiparesis. Concern

From the Department of Pathology, and Division of Neurology, Duke University Medical Center, Durham, North Carolina 27710; and Plk Reichenau Post Fach 3000, Germany.

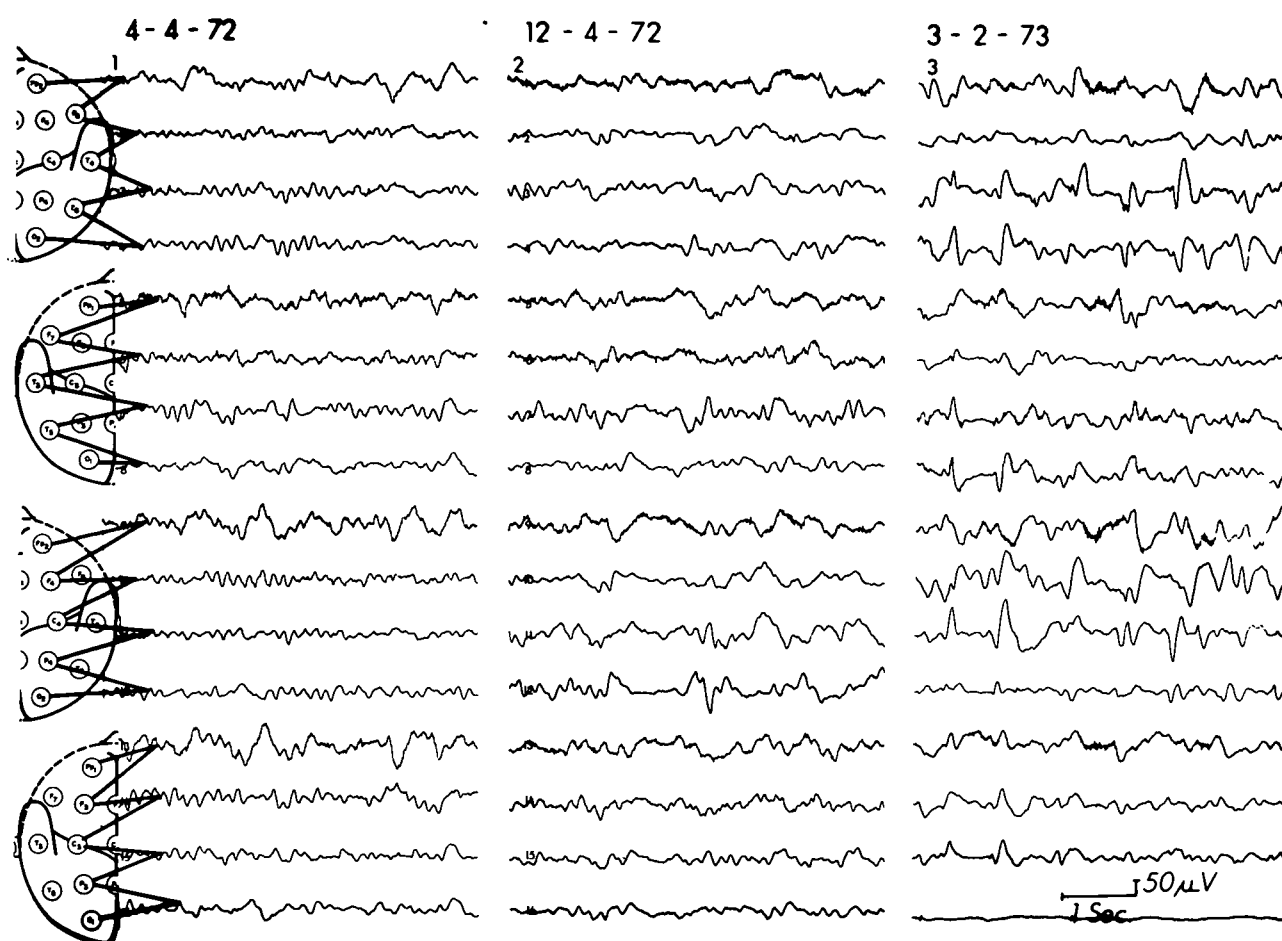


FIGURE 1. Serial EEGs depict a progressive deterioration of the background activity and, in the last tracing in March, 1973, the appearance of triphasic potentials. All tracings were obtained with a 16-channel Grass Model VI calibrated at 50 microvolts/7.5 mm.

that the patient's deterioration was due to shunt malfunction prompted efforts at ventricular tapping which were unsuccessful. A CO_2 pneumoencephalogram demonstrated normal ventricular size (fig. 3), although a midline shift from right to left was present. A right carotid arteriogram disclosed a 1.5-cm peripheral veneer compatible with a subdural hemorrhage. Following evacuation of the hematoma, the hemiparesis cleared and the patient was discharged, although there had been no improvement in his mental status.

Several subsequent short hospitalizations were necessitated by a subdural empyema at the site of the craniotomy which was treated successfully by drainage and antibiotics. During the last months of his life the patient had myoclonic jerks, mutism, and lethargy. An EEG revealed triphasic waves with progression of the background deterioration when compared with previous recordings 3 and 11 months earlier (fig. 1). Marked obtundation and bilateral bronchopneumonia immediately preceded his death in March, 1973. Permission for autopsy was limited to the brain.

Autopsy Findings

The 1,320-gm brain was not atrophic. A plastic shunt tube terminated in the body of the right lateral ventricle. A firm,

flat, fibrotic mass 1.5 cm in thickness tenaciously adhered to the dura over the right frontal lobe. There was moderate to severe atherosclerosis of the large vessels at the base of the brain, as well as the more peripheral branches of the middle cerebral arteries emerging from the sylvian fissures and in the pericallosal branches of the anterior cerebral arteries (fig. 4). A $2.0 \times 3.0 \times 2.0$ cm cystic infarct was positioned in the right frontal lobe and a similar lesion was superficially situated in the left parietal lobe.

Coronal sections revealed that, with the exception of the two infarcts and the cavity at the biopsy site in the right occipital lobe, the cortical ribbon was of normal thickness, configuration, and color throughout. The ventricles were of normal size. Lacunar infarcts were scattered throughout the basal ganglia, internal capsules, corpus callosum, cerebral hemispheric white matter, pons, and cerebellum (fig. 4).

Microscopically, the flat mass over the right frontal lobe was composed of dense fibrous tissue containing scattered foci of chronic inflammatory cells and was consistent with an organized subdural empyema. The lacunar infarcts were variable in age — most were old but a few were recent.

Marked vascular changes were present throughout the brain. The large vessels at the base as well as the more peripheral vessels over the convexities were atherosclerotic (fig. 4), while the intraparenchymal arteries of the basal

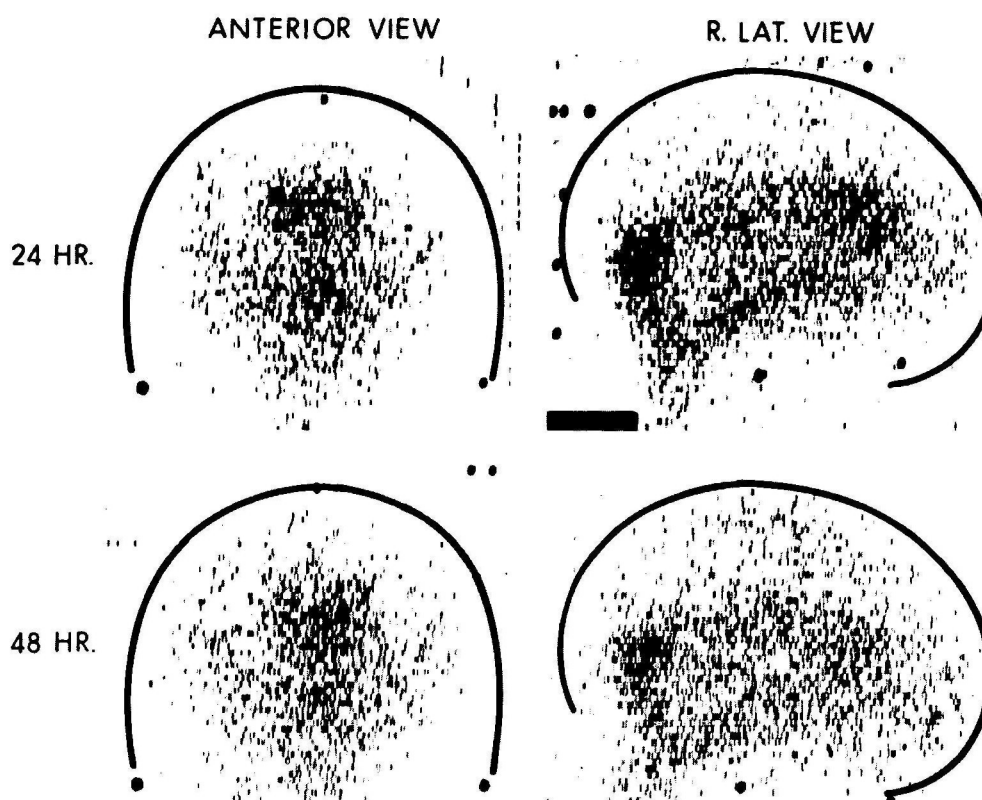


FIGURE 2. A RISA cisternogram in April, 1972, shows ventricular reflux, delayed clearance, and absence of sagittal activity at 24 and 48 hours.

ganglia, centrum semiovale, cerebellum, and pontine base were hyalinized and contained intramural deposition of lipid (lipohyalinosis) (fig. 5). Arterioles demonstrated focal medial thickening and hyalinization (fig. 6). In the pons, this hyalinization of small arterioles was often brightly eosinophilic and surrounded by a collar of necrotic

parenchyma (fig. 7). Veins showed slight fibrous thickening. Widely scattered small petechiae dotted the centrum semiovale and brain stem. There was no evidence of a vasculitis.

A most striking change affecting the parenchyma of the brain was the bilateral presence of large confluent areas of

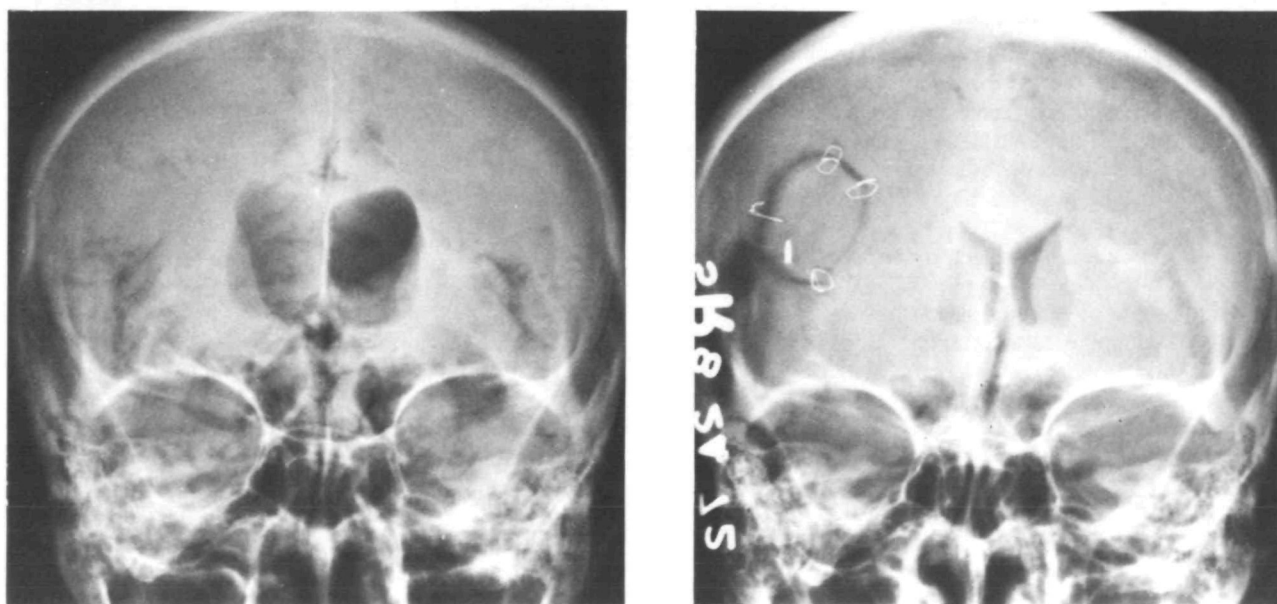


FIGURE 3. In a pneumoencephalogram from April, 1972 (left), there is diffuse ventricular enlargement and very little free-convexity air. In August, 1972 (right), the ventricles are of normal size and displaced to the left by a right subdural hematoma.

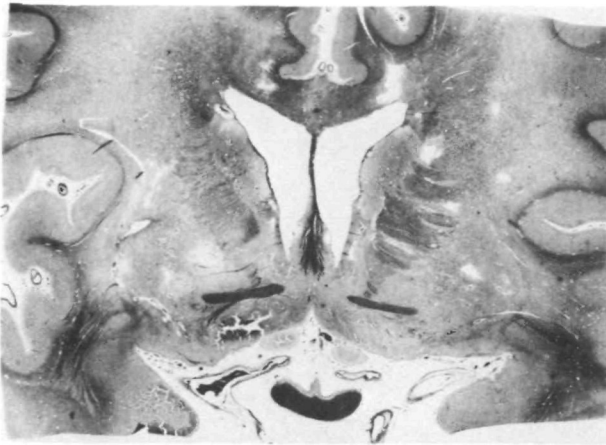

FIGURE 4. A whole mount histological section at the level of the optic chiasm reveals a diffuse pallor of the centrum semiovale which spares the subcortical arcuate zone. The cortex is intact; lacunar infarcts are scattered throughout the basal ganglia, the deep white matter, the internal capsules and the corpus callosum. There is marked atherosclerosis of the basilar vessels as well as the peripheral anterior and middle cerebral arteries. Hematoxylin and eosin/luxol fast blue, $\times 1.4$.

white matter pallor in the centrum semiovale and cerebellar white matter and brain stem (fig. 4). The intensity of this alteration varied somewhat from area to area and consistently spared the cerebral subcortical arcuate fibers (figs. 4 and 8). In the least involved regions there was simply a decreased density of axons and their myelin sheaths and a prominence of reactive astrocytes, while in more advanced areas a further decrease in axon density was accompanied by the presence of small, clear, empty spaces. In the most severely involved zones there was a loose meshwork of widely separated myelinated fibers enmeshed in a matrix of granular eosinophilic material (fig. 9). Fragmenting axis cylinders and degenerating myelin were both present, but comparison of adjacent sections stained for myelin (H&E/LFB) and axis cylinders (Holmes) suggested a greater loss of myelin than axis cylinders. This apparent preferential loss of myelin could also be appreciated in H&E/LFB sections where large demyelinated axons were observed (fig. 9). Scattered small cystic areas of frank infarction were noted which merged focally with the more diffuse form of tissue loss. For the most part it was not possible to correlate a specific local vascular alteration with the presence or absence of the diffuse white matter loss.

The diffuse white matter disease was reflected distally as Wallerian pallor of the internal capsules, cerebral peduncles, pontine base, and medullary pyramids. With the exception of the old parietal and frontal infarcts, the cerebral and cerebellar cortices were conspicuously intact (fig. 8).

Bielschowsky stains on sections of the frontal and hippocampal cortices revealed a few senile plaques but no neurofibrillary change, granulovacuolar degeneration, Pick bodies, or cortical status spongiosus.

Discussion

The diagnosis of SAE or Binswanger's disease in this patient rests on the association of hypertension and dementia with a diffuse white matter degeneration accompanied by

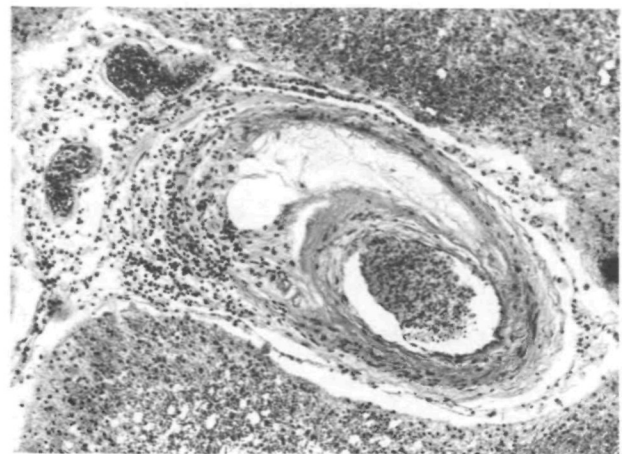


FIGURE 5. An artery in the caudate nucleus shows the medial thickening and deposition of a bubbly lipid characteristic of lipohyalinosis. Hematoxylin and eosin/luxol fast blue, $\times 70$.

vascular alterations of severe atherosclerosis, lipohyalinosis, and arterial and arteriolar hypertrophy and hyalinization. It is unlikely that the senile plaques, which have been encountered in other cases of SAE,¹⁰ contributed significantly to the patient's dementia as they were few in number and not associated with either neurofibrillary change or granulovacuolar degeneration.

The present case is one of the more thoroughly clinically studied examples of SAE and is a dramatic example of the progressive dementia in this disorder. The age of onset (49 years) is atypical, as most cases have presented between 55 and 70 years of age.^{3,8} The neurological examination revealed only transient, mild, focal lateralizing findings which contrasted with the striking evidence of diffuse cerebral dysfunction including disturbances of emotion and memory, disorders of gait and speech, snout and suck reflexes, incontinence, and finally a state of akinetic mutism with generalized increase in muscle tone. The patient's progressive deterioration could be correlated with changes in serial EEG tracings which showed progressive deterioration

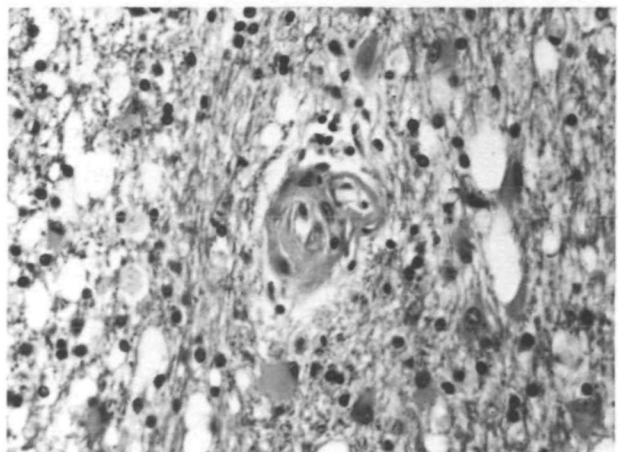


FIGURE 6. An arteriole in the centrum semiovale is markedly thickened. The white matter is pale and contains small cystic spaces and reactive astrocytes. Hematoxylin and eosin/luxol fast blue, $\times 225$.

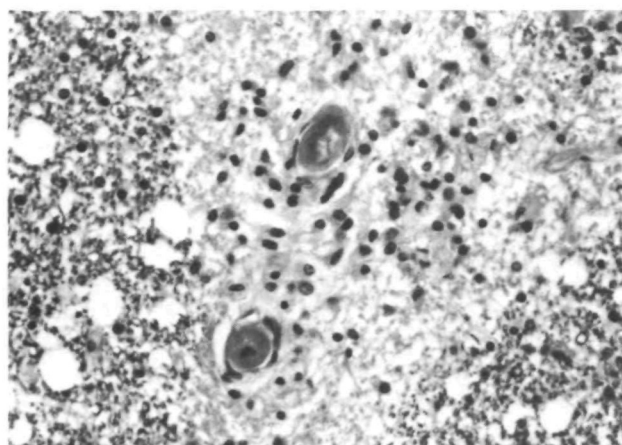


FIGURE 7. Two small arterioles in the pons are hyalinized and brightly eosinophilic. Unlike the other vascular alterations, this change was usually associated with a well-defined local breakdown of myelin and axis cylinders. Here, the vessels are surrounded by a zone of pallor which contains many macrophages. Hematoxylin and eosin/luxol fast blue, $\times 225$.

of the background with increasing irregular slow wave activity. In the last months of life, infrequent myoclonic jerks, primarily of truncal musculature, were seen, but could not be correlated with EEG activity. In addition to the diffuse slowing which has been documented in other reports,^{8, 9-12} this patient manifested triphasic waves which, in company with myoclonic jerks, drew attention to the possibility of Jakob-Creutzfeldt disease.

The patient had labile hypertension without systemic manifestations. In most case descriptions of SAE, severe hypertension has been documented, but there has been no reported beneficial effect on the progression of the illness with antihypertensive therapy, and no explanation why hypertension expresses itself in this unique fashion in a small group of cases. Cerebral angiography in our patient showed mild arteriosclerotic changes in the large basal vessels, but other large and small vessels were unremarkable. In two

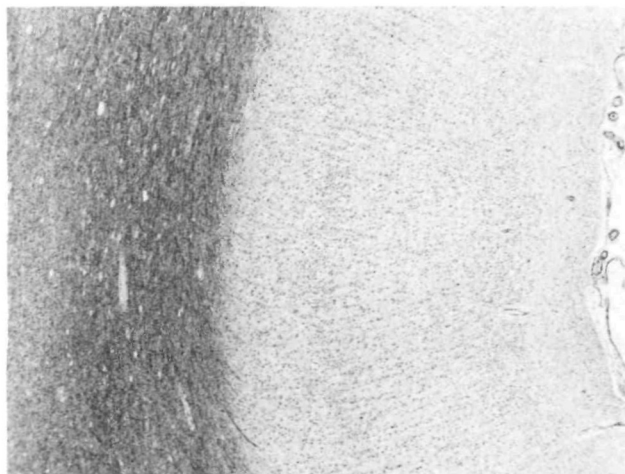


FIGURE 8. A section from the left parietal lobe emphasizes the preservation of the cortex and subcortical arcuate fibers, and, at the far left, the pallor of the deep white matter. Hematoxylin and eosin/luxol fast blue, $\times 25$.

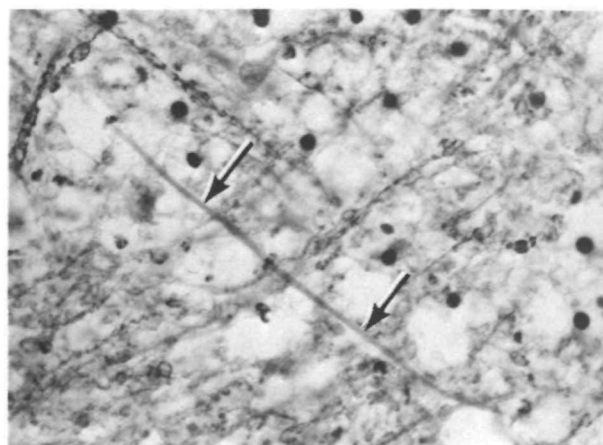


FIGURE 9. A hematoxylin and eosin/luxol fast blue preparation reveals a large axon (arrows) that has lost its myelin sheath. $\times 300$.

previously reported cases of SAE, cerebral angiography was unremarkable.^{9, 12}

An informative aspect of the present case was the evaluation by pneumoencephalography and radioactive serum albumin (RISA) cisternography. Both studies demonstrated changes compatible with normal pressure hydrocephalus (NPH) (figs. 2 and 3), although such alterations are increasingly recognized as nonspecific.¹³ Because the patient's clinical picture was consistent with the NPH syndrome, and because repeated lumbar punctures led to an apparent improvement in clinical status, shunting seemed indicated. Following a ventriculovenous shunt, the ventricular size returned to normal (fig. 3), but unfortunately did not alter the progression of the patient's dementia. The abnormal RISA study and the effect of the shunt in reducing ventricular size, the latter finding confirmed at postmortem examination, document an abnormality in CSF dynamics, although this did not appear to contribute significantly to the clinical symptomatology as it is presumed to do in the NPH syndrome.

In light of the cortical preservation, dementia is one of the most curious facets of SAE and is usually attributed to the white matter lesions. The pathogenesis of this white matter disease has been difficult to explain. Ischemia secondary to the usually severe cerebrovascular disease is an obvious candidate, and is incriminated in our case by the gradations between the diffuse form of white matter degeneration and the frankly infarctive cystic foci. Some authors, however, feel that the severe vascular changes are independent or secondary alterations,¹⁴ and it remains to be explained why ischemia's effect should be so largely directed at the white matter.

One explanation utilizes the concept that the parenchyma supplied by the most distal branches of the major cerebral vessels is the most susceptible to a reduction in cerebral blood flow. This "watershed" or "borderzone" phenomenon is usually most apparent in the setting of severe hypotension as parasagittal infarcts which straddle the terminal distributions of the anterior and middle cerebral arteries, but has also been advocated for the white matter degeneration in SAE.^{8, 15}

In the present case the white matter lesions were ubiq-

uitous and clearly exceeded the watershed regions, but certainly could have begun there. In a sense, one might consider the entire centrum semiovale as a watershed zone, as the supplying vessels are most distal from the large arteries in the subarachnoid space. Cerebral blood flow studies in baboons confirm this precarious supply to the white matter by the demonstration that progressive reduction of arterial pressure can produce a state of zero blood flow in the centrum semiovale at a time when the cortical gray matter is still being perfused.¹⁶ Experimental hypotension in dogs, furthermore, in some animals, produces selective necrosis of the cerebral white matter.¹⁷

A modification of this approach has suggested that the long perforating vessels which supply the centrum semiovale overreact to the hypertension to become fibrotic, dilated, and unable to shield the more distal white matter vasculature from the effects of the elevated pressure. It is further postulated that this situation is aggravated by a shunting of blood from the cortex.⁶

Others have noted that the deep cerebral white matter forms an anatomic unit distinct from the cortex because of the former's drainage into the deep or galenic system of veins. These authors have suggested that congestion and stasis within these veins, secondary to right-sided heart failure, are pathogenetic factors in the white matter degeneration of SAE.^{15, 18}

Still others have implicated cerebral edema, since it occurs in the brains of hypertensives and shows a similar distribution (deep white matter with sparing of the gray matter and subcortical arcuate zone) as that of the white matter degeneration of SAE.^{14, 19} The apparent combination of edema (induced by hypoxia) and ischemia has been associated in some patients with cerebral lesions positioned predominantly in the white matter.^{20, 21}

Whatever its pathogenesis, SAE remains a curious expression of hypertension and cerebrovascular disease which appears unpredictably among the population of hypertensive individuals. The present case underscores the importance of its consideration in the genesis of dementia, even in the presence of normal arteriography and in the absence of sustained hypertension and significant localizing neurological signs. It also indicates that altered CSF dynamics identical to those of the normal pressure hydrocephalus syndrome may occur in disease states in which shunting is ineffective in altering the progression of the dementia.

References

1. Hachinski VC, Lassen NA, Marshall J: Multi-infarct dementia. A cause of mental deterioration in the elderly. *Lancet* 2: 207-210, 1974
2. Tomlinson BE, Blessed G, Roth M: Observations on the brains of demented old people. *J Neurol Sci* 11: 205-242, 1970
3. Olszewski J: Subcortical arteriosclerotic encephalopathy. Review of the literature on the so-called Binswanger's disease and presentation of two cases. *World Neurology* 3: 359-375, 1962
4. Iglesias-Rozas JR, Ebhardt G: Alterations of microvasculature in progressive subcortical encephalopathy (Binswanger). In Cervos-Navarro J (ed): *Pathology of Cerebral Microcirculation*. Berlin, De Gruyter, pp 454-461, 1974
5. Jellgersma HC: A case of encephalopathia subcorticalis chronica (Binswanger's disease). *Psychiatr Neurol (Basel)* 147: 81-89, 1964
6. Okeda R: Morphometrische Vergleichsuntersuchungen an Hirnarterien bei Binswangerscher Encephalopathie und Hochdruckencephalopathie. *Acta Neuropathol* 26: 23-43, 1973
7. Davison C: Progressive subcortical encephalopathy (Binswanger's disease). *J Neuropath Exp Neurol* 1: 42-48, 1942
8. Jellinger K, Neumayer E: Progressive subcortical vasculäre Encephalopathie Binswanger. Eine klinisch-neuropathologische Studie. *Arch Psychiatr Nervenkr* 205: 523-554, 1964
9. Biemond A: On Binswanger's subcortical arteriosclerotic encephalopathy and the possibility of its clinical recognition. *Psychiatr Neurol Neurochir* 73: 413-417, 1970
10. Ishino H, Higashi H, Hayahara T, et al: A case of subcortical arteriosclerotic encephalopathy (Binswanger's disease). *Folia Psychiatr Neurol Jap* 26: 39-44, 1972
11. Pilleri von G, Risso M: Das klinische Bild und die pathologischen Veränderungen eines Falles von schwerem subkortikalen Markabbau auf arteriosklerotischer Grundlage (Encephalopathia subcorticalis chronica, Binswanger). *Psychiatr Neurol (Basel)* 137: 209-224, 1959
12. Garcin R, Lapresle J, Lyon G: Encéphalopathie souscorticale chronique de Binswanger. Étude anatomoclinique de trois observations. *Rev Neurol* 102: 423-440, 1960
13. Coblenz JM, Mattis S, Zingesser LH, et al: Presenile dementia. Clinical aspects and evaluation of cerebrospinal fluid dynamics. *Arch Neurol* 29: 299-308, 1973
14. Feigin I, Budzilovich G, Weinberg S, et al: Degeneration of white matter in hypoxia, acidosis and edema. *J Neuropath Exp Neurol* 32: 125-143, 1973
15. Lindenberg R: Patterns of CNS vulnerability in acute hypoxaemia, including anesthesia accidents. In Schade JP, McMenemy WH (eds): *Selective Vulnerability of the Brain in Hypoxaemia*. Oxford, Blackwell, pp 189-209, 1963
16. Symon L, Pasztor E, Dorsch NWC, et al: Physiological responses of local areas of the cerebral circulation in experimental primates determined by the method of hydrogen clearance. *Stroke* 4: 632-642, 1973
17. Lewis AJ, Zingg W: Experimental brain damage in dogs due to systemic, induced hypotension and head-up tilt for short periods. *Angiology* 17: 800-818, 1966
18. Preziosi TJ, Lindenberg R, Levy D, et al: An experimental investigation in animals of the functional and morphologic effects of single and repeated exposures to high and low concentrations of carbon monoxide. *Ann NY Acad Sci* 174: 369-384, 1970
19. Feigin I, Popoff N: Neuropathological changes late in cerebral edema: The relationship to trauma, hypertensive disease and Binswanger's encephalopathy. *J Neuropath Exp Neurol* 22: 500-511, 1963
20. Ginsberg MD, Hedley-Whyte ET, Richardson EP Jr: Hypoxic-ischemic leukoencephalopathy in man. *Arch Neurol* 33: 5-14, 1976
21. Burger PC, Vogel FS: Hemorrhagic white matter infarction in three critically ill patients. *Human Pathol* (in press)