

A case of amnesic syndrome caused by a subcortical haematoma in the right occipital lobe

OSAMU MASUO,
SHINICHIRO MAESHIMA,
KENJI KUBO, TOMOAKI TERADA,
KUNIO NAKAI, TORU ITAKURA and
NORIIHIKO KOMAI

Department of Neurological Surgery, Wakayama Medical College, Wakayama, Japan

(Received 21 August 1998; accepted 13 October 1998)

A case of an amnesic syndrome caused by a subcortical haematoma in the right occipital lobe is reported. A 62-year-old right-handed man presented with a sudden onset of headache to the hospital. On admission, he had a left homonymous hemianopsia, disorientation and recent memory disturbance, but had normal remote memory and digit span. Computed tomography (CT) and magnetic resonance imaging (MRI) revealed a subcortical haematoma in the right occipital lobe. These findings suggest that the patient's amnesia was caused by a lesion of the retrosplenial region in the non-dominant hemisphere.

Introduction

In 1987, Valenstein described a patient with amnesia associated with an arterio-venous malformation located between the splenium of the corpus callosum and the trigone of the left lateral ventricle [1]. He called this syndrome retrosplenial amnesia and suggested that this memory deficit was due to an interruption of an alternative pathway from the hippocampus to the anterior thalamus. Following that initial description, additional cases have been reported [2–4]. However, in the prior reports, retrosplenial amnesia was caused by a retrosplenial lesion in the dominant hemisphere. Here, the first case of retrosplenial amnesia caused by a non-dominant hemisphere lesion is reported.

Case report

A 62-year-old right-handed man was admitted as an emergency to hospital because of the sudden onset of headache on the morning of 6 March, 1994. On admission, the patient was alert. Neurologic examination revealed a left homonymous hemianopsia. He had neither motor paresis nor sensory disturbance. A CT scan performed on admission demonstrated a subcortical haematoma in the right occipital

Correspondence to: Dr Osamu Masuo, Department of Neurological Surgery, Wakayama Medical College, 7-27 Wakayama 640, Japan.

lobe with ventricular penetration (figure 1a). An angiogram did not reveal any abnormal blood vessels. Therefore, on the 4th hospital day, a stereotactic evacuation of the haematoma was performed. A post-operative CT scan demonstrated total removal of the haematoma (figure 1b). MRI 6 months following the haemorrhage revealed the cyst cavity in the right medial occipital lobe (figure 1c). A sagittal MRI section showed destruction of the right lateral corpus callosum.

Neuropsychologic examinations

On the 10th postoperative day, neuropsychologic testing was performed (table 1).

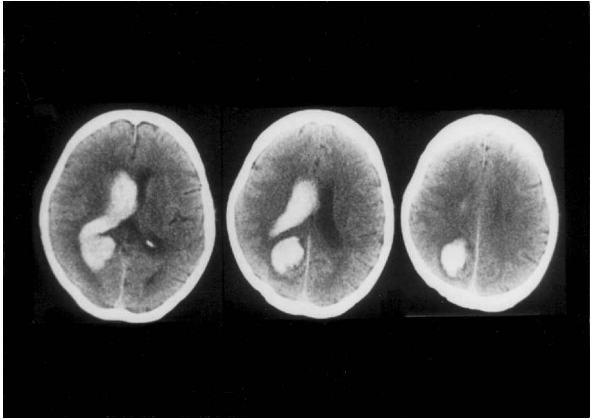
The mini-mental status examination scale was 16/30. Digit span was performed successfully for up to seven digits, and word fluency (animal names) was 10 per minute. Aphasia, ideomotor, or ideational apraxia were not observed. Tactile naming in the left hand was normal. Neglect of the left side was seen in line bisection, line cancellation, and figure copying tests.

On the Wechsler Adult Intelligence Scale-Revised (WAIS-R), the patient's verbal IQ was 92 and his performance IQ was 70. His full IQ was 75. These results demonstrated a mild impairment of intelligence, especially in performance.

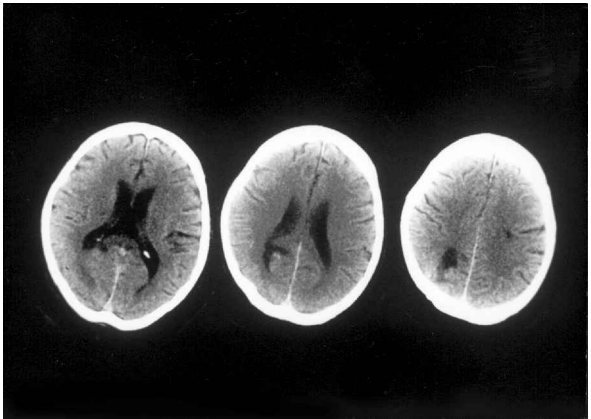
His memory function was impaired. On the Wechsler memory scale, all tasks were impaired, and his memory quotient was 75. On the Benton visual recognition test and auditory verbal learning test, both verbal and non-verbal tasks were disturbed.

Table 1. Neuropsychological examination

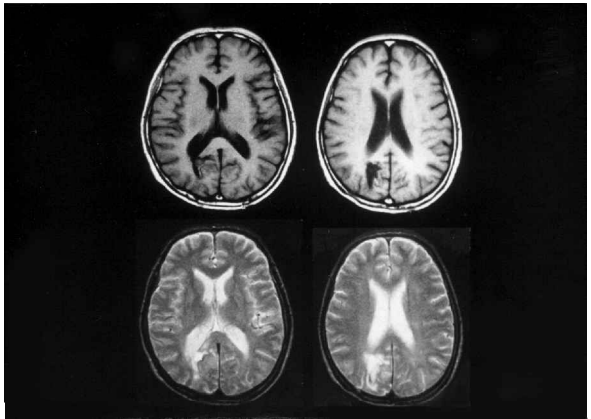
Mini-mental state (/30)	13	22	26
Word fluency (/min)	7	8	8
Raven's CPM (/36)	13	29	29
WAIS-R			
Verbal IQ	92	94	94
Performance IQ	70	78	81
Full scale	75	90	88
Wechsler memory scale (MQ)	67	76	88
Information	3/6	4/6	3/6
Orientation	0/5	4/5	4/5
Mental control	6/9	6/9	7/9
Logical memory	2/24	2/24	3.5/24
Digit span	8/15	9/15	10/15
Visual reproduction	5/14	5/14	6/14
Associative learning	3/21	3.5/21	8/21
Benton Visual Retention Test			
Immediate recall	4/10	4/10	3/10
Delayed recall	2/10	2/10	3/10
Auditory Verbal Learning Test			
Immediate recall	5, 6, 5, 3, 4/15	2, 0, 5, 5, 6/15	4, 6, 4, 6, 5/15
Delayed recall	1/15	0/15	5/15
Recognition	10/15	9/15	10/15
Miyake's Associate Learning Test			
Meaningful (/10)	2-4-5	5-7-7	5-8-8
Meaningless (/10)	0-0-0	0-0-0	1-2-1



(a)



(b)



(c)

Figure 1. (a) A CT scan on admission demonstrated a subcortical haematoma in the right occipital lobe with ventricular penetration. (b) A post-operative CT scan demonstrated total removal of the haematoma. (c) MRI after 6 months revealed the cystic cavity in the right medial occipital lobe.

Clinical course

Serial neuropsychologic tests were performed for 6 months. The patient's minimal status score and IQ gradually improved. Neglect of the left side also resolved within a few weeks. However, all evaluations of memory function did not show remarkable improvement.

Discussion

Valenstein [1] hypothesized that retrosplenial amnesia was caused by a lesion in the pathway between the hippocampus and anterior thalamus. Patients with retrosplenial amnesia present with anterograde amnesia more frequently than retrograde. In fact, all previously reported cases demonstrated anterograde amnesia, and three cases also had retrograde amnesia [2–4]. Recent reports suggest that the retrosplenial region plays an important role in processing information involved in memory and learning [3]. Unlike the previously reported cases, this patient had a non-dominant retrosplenial lesion. Generally the destruction of the non-dominant retrosplenial region leads to topographic disorientation without amnesia. In this case, a topographic disturbance was not clearly present. This case represents the first report of a non-dominant retrosplenial amnesia. The authors hypothesize that a right retrosplenial lesion causes amnesia by a disruption between the hippocampus and anterior thalamus.

A lesion of the pathway from the hippocampus to the anterior thalamus in the dominant hemisphere impairs verbal memory. The interruption of this pathway in the right hemisphere also leads to a disturbance of visual memory. Likewise, Milner *et al.* [4] suggested, from a retrospective analysis of temporal lobectomy cases, that a left temporal lobectomy could cause a disturbance of verbal memory, but a right temporal lobectomy disrupts visual memory. However, the present case of a non-dominant lesion demonstrated a disturbance of both the verbal and visual memory. This observation suggests the existence of a close interaction between the right and left hemispheres in memory function.

References

1. VALENSTEIN, E., BOWER, D., VERFAELLIE, M. *et al.*: Retrosplenial amnesia. *Brain*, 11: 1631–1646, 1987.
2. VAN, G. T. and WYSS, J. M.: Connection of the retrosplenial granular cortex in the rat. *Journal of Comparative Neurology*, 315: 200, 1992.
3. MORI, E., YAMADORI, A. and MITANI, Y.: Left thalamic infarction and disturbance of verbal memory. *Annals of Neurology*, 20: 671–676, 1986.
4. MILNER, B., COKIN, S. and TEUBER, H.: Further analysis of the hippocampal amnesic amnesia syndrome. A 14-year follow up study of HM. *Neuropsychologia*, 6: 215–234, 1968.