

Abrupt Exacerbation of Acute Subdural Hematoma Mimicking Benign Acute Epidural Hematoma on Computed Tomography

—Case Report—

Kunihiko KATO, Osamu WATANABE, and Yoshinori OZAWA

Department of Neurosurgery, Chiba Rosai Hospital, Ichihara, Chiba

Abstract

A 75-year-old male was hit by a car, when riding a bicycle. The diagnosis of acute epidural hematoma was made based on computed tomography (CT) findings of lentiform hematoma in the left temporal region. On admission he had only moderate occipitalgia and amnesia of the accident, so conservative therapy was administered. Thirty-three hours later, he suddenly developed severe headache, vomiting, and anisocoria just after a positional change. CT revealed typical acute subdural hematoma (ASDH), which was confirmed by emergent decompressive craniectomy. He was vegetative postoperatively and died of pneumonia one month later. Emergent surgical exploration is recommended for this type of ASDH even if the symptoms are mild due to aged atrophic brain.

Key words: acute subdural hematoma, lentiform hematoma, acute epidural hematoma, abrupt exacerbation, computed tomography

Introduction

Acute epidural hematoma (AEDH) generally appears on computed tomography (CT) as a lentiform and homogeneous high density lesion with or without associated lesions of the overlying skull and soft tissues.^{3,14,15} In contrast, acute subdural hematoma (ASDH) has a crescent shape, often accompanied by cerebral contusion.^{4,9,15} The clinical presentations are also quite different, as patients with AEDH may appear totally alert during the lucid interval, whereas patients with ASDH are usually comatose because of severe parenchymal brain damage.

We describe a case of atypical lentiform ASDH in an aged person with atrophic brain, in whom the symptoms exacerbated abruptly after 33 hours of lucid interval.

Case Report

A 75-year-old male was the victim of a hit and run accident, when riding a bicycle. He was found lying in the road, and was taken to the nearest clinic by

ambulance. He had total amnesia about the accident. He had signs of blows on the left side of the body but could talk and walk normally. CT one hour after the accident revealed an intracranial clot, which prompted emergency transfer to our hospital.

On admission, he had only moderate occipitalgia and amnesia about the accident. The initial CT at the previous clinic showed a lentiform, homogeneous hematoma, 2 cm in thickness, in the left temporal extracerebral region. Additionally, his atrophic brain had an old infarction in the corona radiata (Fig. 1). Laboratory studies including the coagulation function showed no remarkable abnormality. The tentative diagnosis of AEDH was based on the CT findings and clinical features. Conservative therapy was selected considering his mild symptoms and age.

Repeat CT at 7 hours and 24 hours after the accident showed no remarkable change. However, careful observation of the hematoma disclosed a low density area with a niveau (Fig. 2). Conservative therapy was continued.

Thirty-three hours after the accident, he suddenly

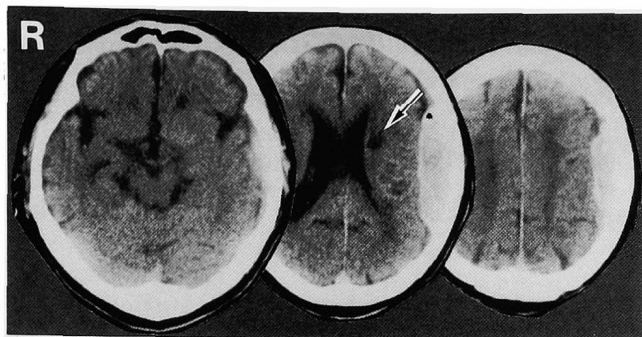


Fig. 1 Initial computed tomography scans 1 hour after the accident revealing a lentiform, homogeneous hematoma in the left temporal extracerebral region. Note the atrophic brain with old infarction in the corona radiata (arrow).

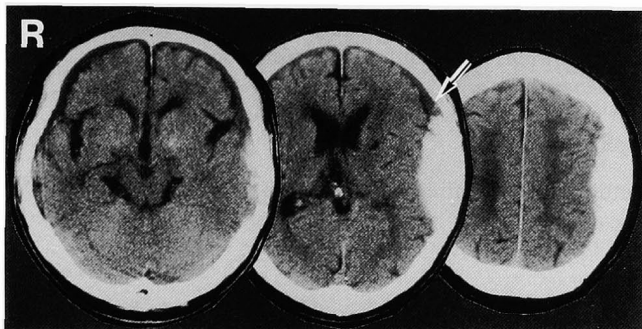


Fig. 2 Computed tomography scans 24 hours after the accident showing no remarkable change. Note the low density area above the hematoma with a niveau (arrow).

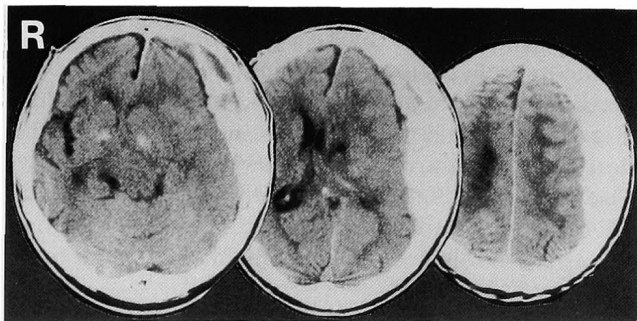

Fig. 3 Emergent computed tomography scans 33 hours after the accident showing a typical acute subdural hematoma with brain herniation.

complained of severe headache and vomited just after sitting up to get into a wheelchair. Neurological examination revealed dilatation of the left pupil. Immediate CT showed a typical ASDH (Fig. 3) which was confirmed by emergent decompressive craniectomy and hematoma evacuation. Multiple bleeding points from the cortical artery and bridging vein were seen but no AEDH. Expansion of the brain was poor even after hematoma removal. He did not recover well postoperatively and died of pneumonia one month later.

Discussion

ASDH is generally considered to appear as a crescentic high density area on CT. However, CT has revealed many atypical hematoma types, 8–14% of ASDH appeared as the lentiform shape.^{1,5,11)} The appearance of ASDH on CT can be classified into three types: concave (crescent), straight, and convex (lentiform).⁵⁾ About 13% of high density subdural hematomas (including rebleeding in chronic subdural hematoma) had convex margins. CT shows some differences between lentiform ASDH and AEDH: The round inner border of lentiform ASDH is hyperconvex and forms an angle of almost 90 degrees with the skull, and it is heterogeneous.¹⁾ The low density area of it is superiorly separated by a niveau from an inferior hyperdense area, possibly due to an influx of the cerebrospinal fluid through tears in the arachnoid membrane. This special heterogeneity, called the “sedimentation effect,”⁶⁾ may be related to the coagulopathy.¹⁾ Another difference is that the margin of lentiform ASDH increasingly regains its characteristic crescentic shape at the periphery. However, only the characteristic of the heterogeneity was seen in our case. Coronal magnetic resonance (MR) imaging might be helpful in such a case to clarify the relationship between the hematoma, subarachnoid space, bridging veins, etc.

The cause of the lentiform appearance of ASDH is unclear, but may have resulted from blockage of the subdural space by adhesions.¹⁾ Acute cerebral swelling may have prevented expansion of the hematoma, which became lentiform as a result. However, acute cerebral swelling did not occur till 33 hours after the accident in our case.

Another problem in this case was the cause of the abrupt exacerbation 33 hours after the accident. Second impact syndrome^{2,8)} might have influenced this catastrophic change. Second impact syndrome is defined as diffuse cerebral swelling after repeated concussive brain injury received in sports.⁷⁾ The pathology is thought to involve loss of autoregula-

tion of the brain blood supply,²⁾ which leads to vascular engorgement, which markedly increases intracranial pressure. Additionally, the shift of the hematoma by a positional change and/or damage to the arterial twig, which is responsible for acute spontaneous subdural hematoma,^{7,10,12,13)} may have been involved in the exacerbation.

Special attention must be given when CT shows lentiform hematoma adjoining aged atrophic brain. If ASDH is confirmed by differential diagnosis using CT and MR imaging, emergent surgery is recommended even if the patient is in good condition.

References

- 1) Braun J, Borovich B, Guilburd JN, Zaaroor M, Feinsod M, Grushkiewicz I: Acute subdural hematoma mimicking epidural hematoma on CT. *AJNR Am J Neuroradiol* 8: 171-173, 1987
- 2) Cantu RC: Second-impact syndrome. *Clin Sports Med* 17: 37-44, 1998
- 3) Dolinskas CA, Zimmerman RA, Bilaniuk LT, Gennarelli TA: Computed tomography of post-traumatic extracerebral hematomas: comparison to pathophysiology and responses to therapy. *J Trauma* 19: 163-169, 1979
- 4) Dubin AB, French BN, Rennick JM: Computed tomography in head trauma. *Radiology* 122: 365-369, 1977
- 5) Forbes GS, Sheedy PF, Piepgras DG, Houser OW: Computed tomography in the evaluation of subdural hematomas. *Radiology* 126: 143-148, 1978
- 6) Kao MC: Sedimentation level in chronic subdural hematoma visible on computerized tomography. *J Neurosurg* 58: 246-251, 1983
- 7) Komatsu Y, Uemura K, Yasuda S, Shibata T, Kobayashi E, Maki Y, Nose T: [Acute subdural hemorrhage of arterial origin: report of three cases]. *No Shinkei Geka* 25: 841-845, 1997 (Jpn, with Eng abstract)
- 8) McCrory PR, Berkovic SF: Second impact syndrome. *Neurology* 50: 677-683, 1998
- 9) Merino-de Villasante J, Taveras JM: Computerized tomography (CT) in acute head trauma. *AJR Am J Roentgenol* 126: 765-778, 1976
- 10) O'Brien PK, Norris JW, Tator CH: Acute subdural hematomas of arterial origin. *J Neurosurg* 41: 435-439, 1974
- 11) Reed D, Robertson WD, Graeb DA, Lapointe JS, Nugent RA, Woodhurst WB: Acute subdural hematomas: Atypical CT findings. *AJNR Am J Neuroradiol* 7: 417-421, 1986
- 12) Talalla A, McKissock W: Acute "spontaneous" subdural hemorrhage. *Neurology* 21: 19-25, 1971
- 13) Yagi T, Suzuki T, Nagata Y, Naruse H, Nakagawa O: [The cases of acute spontaneous subdural hematoma]. *No Shinkei Geka* 24: 665-669, 1996 (Jpn, with Eng abstract)
- 14) Zimmerman RA, Bilaniuk LT: Computed tomographic staging of traumatic epidural bleeding. *Radiology* 144: 809-812, 1982
- 15) Zimmerman RA, Bilaniuk LT, Gennarelli T, Bruce D, Dolinskas C, Uzzell B: Cranial computed tomography in diagnosis and management of acute head trauma. *AJR Am J Roentgenol* 131: 27-34, 1978

Address reprint requests to: K. Kato, M.D., Chiba Neurosurgical Clinic, 408 Naganumahara-cho, Inage-ku, Chiba 263-0001, Japan.