



Callosal disconnection syndrome in a left-handed patient due to infarction of the total length of the corpus callosum

H. Lausberg^{a,*}, R. Göttert^b, U. Münßinger^b, F. Boegner^a, P. Marx^a

^a *Neurologische Klinik und Poliklinik, Universitätsklinikum Benjamin Franklin, der Freien Universität, Berlin*

^b *Neuropsychologische Abteilung, der Klinik München Bogenhausen*

Received 12 September 1997; accepted 2 July 1998

Abstract

We report on a left-handed patient with an ischemic infarction affecting exclusively the total length of the corpus callosum. This lesion clinically correlated with an almost complete callosal disconnection syndrome as described in callosotomy subjects, including unilateral verbal anosmia, hemialexia, unilateral ideomotor apraxia, unilateral agraphia, unilateral tactile anomia, unilateral constructional apraxia, lack of somesthetic transfer and dissociative phenomena. Despite the patient's left-handedness, his pattern of deficits was similar to the disconnection syndrome found in right-handers. Our report focusses on motor dominance and praxis. We followed-up the improvement in left apraxia and investigated the ability to initiate and learn a new visuo-motor skill. The results permit two tentative assumptions: (1) that the improvement in left apraxia was due to a compensatory increase in ipsilateral proximal muscle control, and (2) that motor dominance, i.e. the competence to initiate and learn a new movement pattern, was hemispherically dissociable from manual dominance in the sense of praxis control. © 1999 Elsevier Science Ltd. All rights reserved.

Keywords: Callosal disconnection syndrome; Left-handedness; Motor dominance; Callosal apraxia; Pericallosal artery

1. Introduction

The description of callosal syndromes in the current literature is for the most part based on studies of patients who have undergone callosotomy. It is common to suspect that the majority of these patients have atypical patterns of neural connection caused by primary defects or long lasting disease [16]. In contrast, spontaneous callosal syndromes permit the study of disconnection signs in patients with primarily normal neural conditions.

In spontaneous callosal syndromes caused by tumor or aneurysm rupture, lesions are not restricted to the structure of the corpus callosum. In most cases of ischemic infarction only partial callosal lesions were reported [18, 53, 59] or there was co-occurrence of extended pericallosal lesions [17, 58].

To our knowledge, this is the first case of an ischemic infarction affecting the entire length of the corpus callosum with almost no concomitant damage. Only one more small lesion in the left parietal white matter was detected. As damage to neighboring structures barely modified the callosal disconnection syndrome, our patient

offered us the opportunity of investigating an almost complete and purely callosal disconnection syndrome. Except for microangiopathy there were no previous brain lesions. This case shows that the previous data on callosal syndromes, that are gained mainly by investigation of callosotomy subjects, are really due to the disconnection and not caused by factors such as surgery, perioperative conditions or preexisting epilepsy.

Another uniqueness of the case was the patient's left-handedness. Most of the callosal syndromes described in the current literature refer to right-handers. The few case reports of callosal disconnection syndromes in left-handers show that their organization of hemisphere functions is not merely a simple reversal of the right-handers' organization and has a high degree of variability [1, 5, 22, 33, 53]. Hence, our neuropsychological investigation focussed on aspects of hemisphere specialization that refer to handedness.

All investigations were carried out as part of the normal clinical rehabilitation procedure and performed with the available routine diagnostic tools. Since we could follow up the patient over a period of nine months, we had the opportunity to analyse his improvement after callosal disconnection. Further follow-up was limited by the patient's death on March 30, 1995 due to dilated cardiomyopathy.

* Corresponding author. Tel.: 0049-30-8445-2061; Fax: 0049-30-8445-4141

2. Case report

The patient was a 54-year-old left-handed engineer, who had previously been healthy except for a long-standing insulin-dependent diabetes mellitus type II. On November 4, 1993, he suddenly noticed ‘co-ordination problems’ on the left side of his body while dressing and slurred speech.

On admission the patient was alert and oriented. The cranial nerves were normal. There was no paresis nor ataxia. Tendon reflexes were symmetrically weak, pathological reflexes were absent. Except for a deficit in sensation to vibration in both legs, there was no sensory deficit.

The patient was left-handed. He preferred the left hand for all manual activities except for writing which he had been trained to do with the right hand in school and for drawing for which he used either hand depending on the task. According to the Edinburgh Handedness Inventory [39] his laterality quotient was -64 . He had a non-inverted writing posture for both hands. The patient’s maternal grandmother was also left-handed.

Spontaneous speech production and comprehension were intact with no aphasic symptoms. Memory was normal in memory-span tasks and verbal learning tasks; however, the patient showed some slight difficulties in retrieving information from memory. This was evident for remote memory as well as for newly learned information. Basic perceptual functions were normal. There was no indication of a general cognitive slowing or general reduction in selective or divided attention. The vigilance was markedly reduced, often the patient’s concentration was exhausted after half an hour of therapy. Intelligence in verbal tests was within the normal range, but the patient had difficulties with spatial-constructive tasks, spatial-transformation and planning problems. There seemed to be an impairment in the ability to mentally interpret and organize complex information and to develop, hold and execute complex action plans.

The patient had an almost complete callosal disconnection syndrome [3] including right verbal anosmia, left hemialexia, left apraxia, left agraphia, left tactile anomia, predominantly right constructional apraxia, lack of somesthetic transfer and dissociative phenomena such as intermanual conflict. Special neuropsychological investigations are described in detail below.

The clinical course fluctuated. The cranial MR images shown in Figs. 1–2 were carried out a few weeks after the onset of symptoms. They revealed a lesion in the anterior four-fifths of the left side of the corpus callosum and the left and right side of the splenium as well as a small lesion in the left parietal white matter.

In the sagittal view, there is complete callosal disconnection of right and left hemisphere except for some fibers in the middle of the splenium that might have been

spared. The lesion suggests an infarction in the territory of the left pericallosal artery which originates from the anterior cerebral artery and supplies the first four-fifths of the corpus callosum. In some cases a terminal branch supplies the contralateral splenium. This explains the extension of the infarcted area to the right side of the splenium. The small lesion in the left parietal white matter comprises the territory of the left parietal internal superior artery which is often the strongest branch of the pericallosal artery.

Angiography showed complete left internal carotid occlusion as well as delay and rarification of filling of the left pericallosal artery. Transesophageal echocardiography revealed dilated cardiomyopathy with an 18% reduction of the ejection fraction. There was no evidence of intracavitary thrombi. Further risk factors consisted of long-standing diabetes mellitus with severe retinopathy and microalbuminuria as well as peripheral arterial occlusive disease.

3. Special neuropsychological investigations

3.1. Left alexia and visual anomia

To test the patient’s ability to identify and name visual stimuli in each visual hemifield, stimuli were presented in intervals short enough to prevent eye movement. In a first series of experiments, the patient was asked to read words aloud from a computer screen. The words were displayed for 170 ms and located in the area 2.4 – 4.0° to the left or right of a central fixation point. Under these tachistoscopic viewing conditions, the recognition accuracy for words was greatly reduced in the left visual field (Table 1).

In another series of experiments, the task was to name physical attributes of geometric stimuli, such as shape, color or number of parts. In a first test, simple stimuli (like a red square) were presented via a perimeter at 10° to the left or right of fixation; they covered about 2° of visual angle. The short presentation was manually controlled by the experimenter. The patient was either asked to name the shape or to name the color of the stimulus. He had no difficulties in naming the stimulus attributes in his right visual field but performed at chance level in the left (Table 2, upper section).

We replicated this finding in a more controlled test situation [29]. Compound geometric stimuli (e.g. a group of three blue triangles) were displayed for 180 ms via a tachistoscope; they differed in form, color, and number of parts. The task was to name all recognized stimulus features (Table 2, lower section). The stimuli were displayed in the area between 7 and 10° to the left or right of fixation. We used two presentation conditions: unilateral presentation of one stimulus or bilateral presentation of a stimulus group.

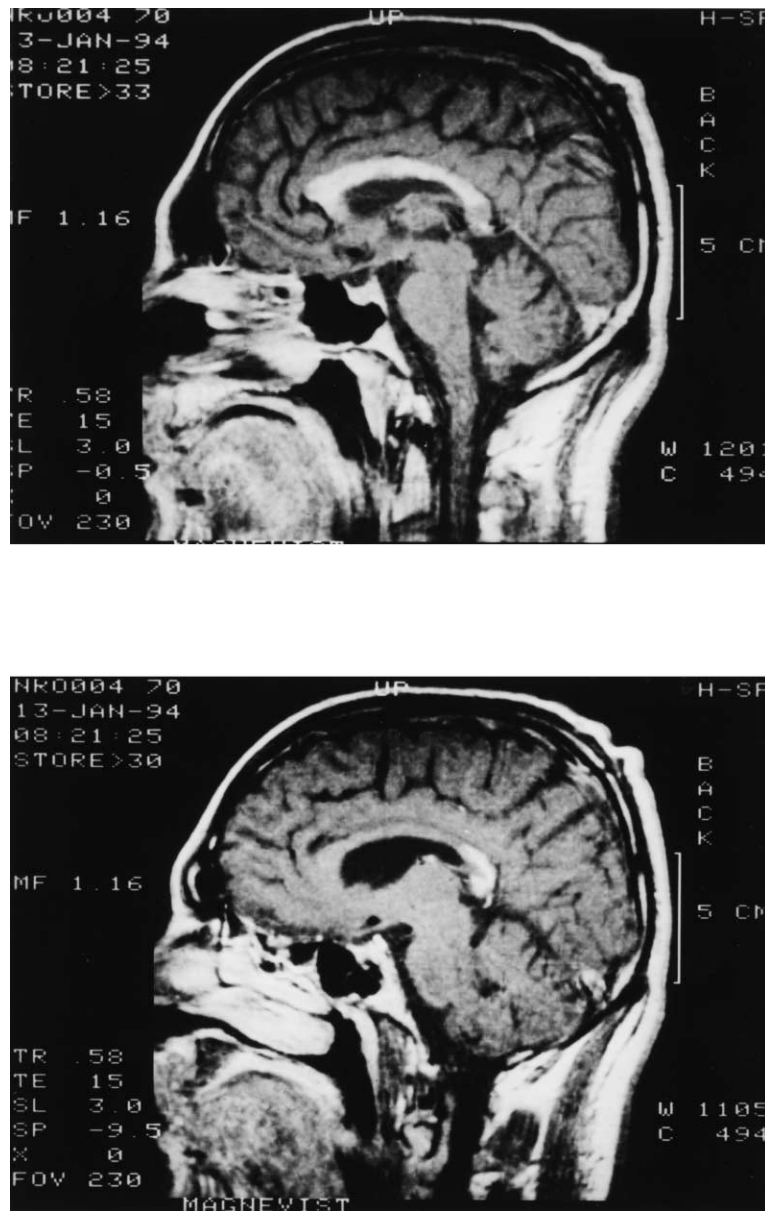


Fig. 1. Top: T1-weighted, left sagittal enhanced MR images: Enhancement of the left anterior four-fifths of the corpus callosum and a small area in the parietal white matter. Bottom: T1-weighted, right sagittal enhanced MR images: Enhancement of the right splenium.

With unilateral presentation the naming of stimulus features in the right visual field was nearly perfect, while accuracy was very low in the left visual field. The asymmetry was even more pronounced with bilateral presentation (Table 2, bottom row), when two stimuli were presented simultaneously and all features of both stimuli had to be reported. Here, the patient tended to first correctly describe the stimulus on the right side but was rarely able to report features of the left stimulus.

3.2. Hemispatial neglect

Spatial perception was impaired by neglect-like conditions in tasks confined to one hand. In a line bisection

task performed with the right hand, the midpoint was displaced by 3.5° to the right. In copying rows of numbers or block letter words with the right hand, the patient missed the first numbers or the first, left-placed letters in the row. When copying letters with the left hand, he copied the first two letters in the row, but neglected the following letters on the right side. He was not at all able to copy numbers with the left hand.

A complex pattern of results emerged in visual detection tasks when the patient had to respond with one hand to stimuli displayed in the ipsilateral or contralateral visual hemifield. When the task was to react to the figural features of the stimulus (e.g. direction of an arrow), each hand responded correctly to stimuli in the ipsilateral vis-

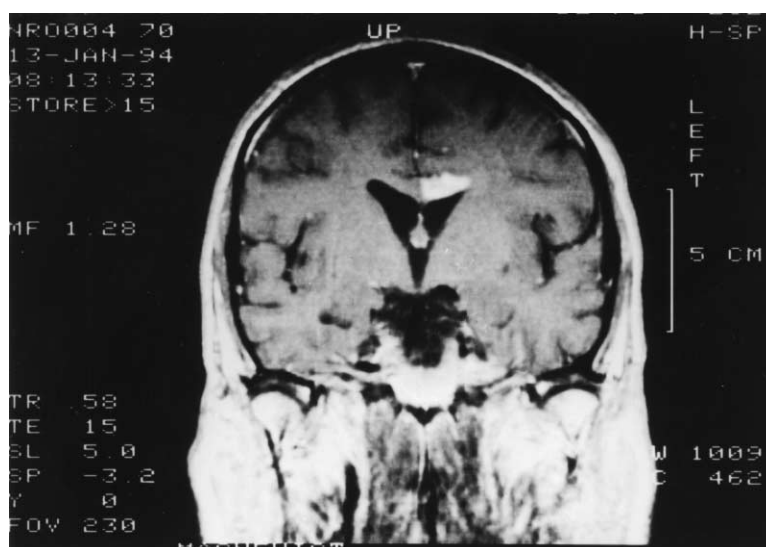


Fig. 2. T1-weighted, coronal enhanced MR images: Enhancement of the left side of the trunk of the corpus callosum.

Table 1
Percentage of words correctly identified under tachistoscopic viewing condition

Word length	<i>n</i>	Word position	
		Left	Right
4	40	45	75
5	40	25	85
6	40	10	90

Word length = number of letters.

n = Number of words presented.

Table 2
Naming the physical features of briefly presented geometrical stimuli in both visual fields

Stimulus type Task	Visual field		
Presentation condition	Left	Right	Chance
Simple stimuli			
Naming form	33	90	50
Naming colour	40	100	33
Compound stimuli			
Naming form, colour, and number			
Unilateral	40	98	
Bilateral	8	96	

The numbers represent the percentage of correct responses for reporting the critical stimulus feature. With compound stimuli the hit rates for form, colour and number were collapsed.

ual field; however, the response to stimuli in the contralateral visual field was near chance level. When the task was to detect the mere onset or motion of a stimulus,

then the response accuracy to stimuli in the visual field contralateral to the responding hand was well above chance level.

The detection of stimuli in the contralateral visual field was strongly influenced by concurrent but task-irrelevant motor activity: additional motor activity facilitated stimulus detection on the side where the activity occurred but impaired stimulus detection contralaterally. Identical results were obtained for both hands.

3.3. Auditory suppression

In order to investigate selective attention in the auditory modality, we tested the patient with the Pigache Attention Test (PAT) [41]. This test contains a dichotic listening condition, so the results can be related to the issue of auditory suppression in split-brain patients.

In dichotic listening tasks [8] two different auditory stimuli are presented simultaneously to the left and right ear. Usually the stimuli are verbal items like words, digits, or syllables and the participant is asked to repeat immediately what he has heard in any ear. This procedure requires participants to give a verbal response to verbal stimuli under the condition of divided attention. It is a common finding in healthy right-handers, that stimuli presented to the right ear are better recognised than stimuli presented to the left ear ('right ear advantage'). Several studies with split-brain patients have demonstrated a strongly increased right-ear advantage, that is an almost complete left-ear suppression [6, 14, 62].

In contrast to this common procedure the Pigache Attention Test (PAT) uses a manual response mode instead of the verbal report. Furthermore it demands selective attention to one ear instead of dividing attention between both ears. The patient has to listen to a con-

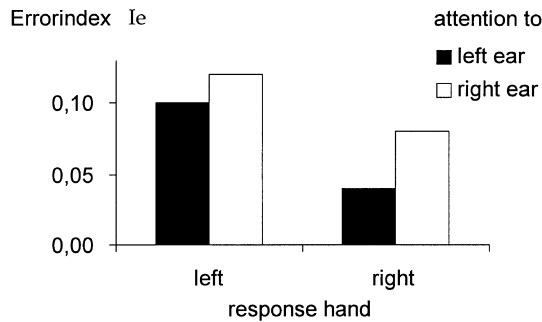


Fig. 3. Accuracy of detecting a spoken target digit in a dichotic listening task (PAT) with focused attention and a manual response format. Higher values represent lower detection accuracy.

tinuous stream of spoken digits presented on earphones; his or her task is to press a button as fast as possible when he or she hears the digit 'zero'. The PAT contains several task conditions: in the first part a diotic presentation condition is administered (i.e. both ears receive the same input). In the dichotic listening condition the patient is instructed to respond only to the digits coming from one side (i.e. from one ear) and ignore those from the other side. The test measure is an almost bias-free error index I_e [40].¹

By using the manual response format of the PAT we were able to assess each hemisphere's ability to analyse verbal input in a way that is not influenced by verbal processes related to the response mode. We tested the patient in all four combinations that can be generated by pairing the dimensions side-of-hand and side-of-ear (responding with the right hand vs. with the left hand and attending to the right ear vs. attending to the left ear). Figure 3 displays results from a slow condition in which pairs of digits were presented every 2 s. Higher values of the error index I_e characterise lower accuracy (more errors), the chance level has a value of about 1.5.

Our patient was able to perform the task in all conditions well above chance level, in fact his performance was in the normal range. The right-hand responses yielded a higher accuracy than left-hand responses. Within each response hand condition, the patient performed better when focusing to the left ear compared to the right ear. Thus, in a dichotic listening task requiring spatial selective attention and a motor response we did not find any indication of left-ear suppression.

3.4. Left agraphia

Agraphia was tested by writing to dictation, composition to dictation, copying and spontaneous writing.

In writing to dictation, the German words for house

('Haus'), car ('Auto'), man ('Mann'), hand ('Hand'), pen ('Stift'), apple ('Apfel') and the patient's first name ('Uwe') were dictated. The words were pronounced clearly and with normal cadence and tempo. The patient was asked to write first with the left hand and then with the right. He was given 1 min to write the word and the option of two attempts.

Agraphic errors were classified and scored according to the criteria of the Aachener Aphasia Test for written language [28]:

- 0 = no reaction, neologism, fragmented reaction, semantic paraphasia, perseveration;
- 1 = little phonemic similarity with the target word, i.e. more than one third of the sounds or syllables are incorrect;
- 2 = sufficient phonemic similarity with the target word, i.e. maximum of one third of the sounds or syllables are incorrect;
- 3 = correct.

Following the concept of Roeltgen [47], we used the term 'visual similarity to the target word' instead of phonemic similarity, since we found that single cursive letters were sometimes distorted in their form, suggesting an error in visual word representation retrieval. Besides, in the right hemisphere of the split brain a lack of phonological coding is purported together with recognition of words by their visual gestalts [32, 61].

If the patient spontaneously made a second attempt to correct himself, the second version was coded for evaluation. We stopped coding (a) in the case of continuous production of neologisms after the third neologism and (b) in the case of continuous perseveration after the first perseverated word. This resulted in a low number of coded words for each trial as demonstrated in Table 3.

Writing to dictation with the right hand was unimpaired. Table 3 shows left-hand aggraphic errors and the total score for agraphia according to Aachener Aphasia Test scoring.

A few weeks after the callosal infarction (December), the patient could not write to dictation with the left hand. Although he was able to correctly form letters with the

Table 3
Development of left aggraphic errors to dictation

	Dec.	Dec.	Jan.	May	Aug.
1 word	n	n	s	s	s
2 word	n	n	l	p	s
3 word	n	n	p		p
Total score	0/9	0/9	3/9	2/6	4/9

n = neologism; l = little visual similarity with the written target word; s = sufficient visual similarity; p = perseveration; Total score according to the Aachener Aphasia Test.

¹ Norms, by A. Schlenker and I. Keller, Klinik München Bogenhausen, unpublished data.

left hand, these letters did not make up meaningful words. He read his written neologistic words fluently and was astonished to find that they had no meaning. One month later (January), the first two words showed visual similarity to the target words, but then the patient perseverated with the following dictated words. Eight months later (August), the first two words increasingly resembled the dictated target words before the patient started perseverating again.

The above results refer to cursive writing. There was however, no improvement when writing in block letters. Here, the patient persistently produced neologisms.

In the task composition to dictation, a subtest of the Aachener Aphasia Test, the patient had to compose cards with letters, syllables and words to form dictated words and sentences. Here, he scored 30 of 30 possible points with the right hand and 13 of 30 points with the left hand.

Copying block letters (4–6-letter words in one row each) with either hand was impaired by spatial hemi-neglect. Thus, the first two letters in the row were omitted when copying with the right hand, whereas only the first two letters in the row were copied when using the left hand.

The patient was not able to write spontaneously with the left hand except for his first name.

3.5. Right and left constructional apraxia

Constructional apraxia was tested by copying drawings and drawing to verbal command.

The patient was asked to copy a drawing (house, star, car, block), first with the right and then with the left hand. Constructional errors were classified as simplified version of the model with absence of some of the parts, incoherence, disproportionate relationships between the parts, or loss of perspective [3].

In copying with the right hand, there was consistent incoherence and disproportionate relationships between the parts. In addition to this, there was a loss of perspective in three-dimensional drawings.

Copying with the left hand was often correct, with the

exception of minor errors such as simplified versions with the absence of parts, slight faults in perspective and errors possibly indicating a deficient visuo-spatial analysis of the model drawing.

Marked right constructional apraxia was also found in the Taylor Figure; here the patient attained 13 of 36 possible points with the right hand according to the Taylor scoring criteria [50]. Mild left constructional apraxia was confirmed by the Taylor Figure (24 points) and the HAWIE-R block design subtest, in which the patient scored a T-value of 41, i.e. within one standard deviation below average with the left hand [54].

In drawing to verbal command (bicycle, house, human being, water tap), the patient displayed severe right constructional apraxia with incoherence and disproportionate relationships between parts. He was not always able to draw with the left hand on verbal command. If he did, the drawings were correct but simplified.

3.6. Left motor apraxia

3.6.1. Left motor apraxia to verbal command

For testing apraxia to verbal command we used a test battery derived from Poeck [42] with 22 meaningful and meaningless movements. The movement tasks were conveyed verbally. The task was first given to the left hand and then to the right. This order was chosen to avoid left-hand replication of right-hand movement by the visual cues. The investigation was videotaped. According to categories used by Poeck [42] and Goldenberg [19], apractic errors were classified as substitution, perseveration, augmentation, hand-finger configuration errors and no/little movement response. Videotapes were coded with this rating instrument by a trained movement analyst. If the patient immediately corrected himself, the second trial was coded.

The patient showed severe left apraxia. There was no right apraxia. The fact that the patient readily executed all commands with the right hand affirmed that the left-sided errors could not be ascribed to a lack of understanding.

Left apractic errors on verbal command are shown in Table 5. Retests for reliability are not included in the table.

One month after callosal infarction (December), left-hand movements were performed incorrectly on verbal command. The patient predominantly showed substitution, perseveration, and augmentation of movements.

After five months (May), there was a clear increase in correct movements and a decrease in substitution and perseveration errors. After eight months (August), motor reaction to verbal command was usually spontaneously correct, but there were still errors in hand and finger configuration. When the patient was asked to bring his index finger to his nose, he used his whole hand instead,

Table 4
Constructional errors in copying drawings

	Right hand	Left hand
Total number of tasks	9	9
Simplified	0	1
Incoherent	9	0
Loss of perspective*	2*	1*
Unclassified	0	2
Correct	0	5

* In drawings suggesting three dimensions the error 'loss of perspective' was additionally coded.

Table 5
Development of left apractic errors to verbal command

	Dec.	May	Aug.
Total number of tasks	22	11*	22
Correct	3	3	15
Substitution	5	3	1
Perseveration	5	0	0
Augmentation	4	2	1
Hand configuration	3	3	5
No movement response	2	0	0

In May, only half of the battery was administered.

or he was unable to perform such single-finger movements as bending his little finger.

3.6.2. Left motor apraxia on imitation

Apraxia to imitation was tested with eight meaningless and meaningful gestures. The patient was asked to imitate first with the left hand and then with the right. Investigation and evaluation procedures were the same as for apraxia to verbal command (Table 6).

The patient had left apraxia even to imitation. Imitating with the right hand was unimpaired.

After callosal infarction (December), apraxia was severe especially with his left leg, e.g. when asked to imitate lifting the left foot as demonstrated by the investigator, he made a supination-pronation movement with his left hand.

After five months (May), apraxia to imitation had improved, especially the left-leg apraxia. However, hand configuration errors persisted even after eight months (August), e.g. when asked to imitate the form 'O', made with the left thumb and index finger, he opposed the thumb to the four other fingers.

3.6.3. Spontaneous movements, actual object use and intermanual conflict

Spontaneous movements were performed correctly on the left side. In tests used to provoke spontaneous left-sided motor reactions such as suddenly throwing an object to the patient's left, he demonstrated unimpaired

motor reaction. In his daily routine, he could use the left hand meaningfully, for example, to shave and comb himself.

However, the patient sometimes could not execute a movement when he planned to perform a specific motor action, e.g. if he wanted to let go of something that he was holding in his hand. It seemed that he was impaired if he only focussed on the motor action itself, but he was able to carry out the motor action if he focussed on the target of the movement, e.g. to have brushed his teeth.

The patient also reported an intermanual conflict, e.g. if he lifted the toilet cover with his right hand, the left one closed it again. In clinical testing, e.g. token test, a correct right-hand reaction was often obstructed by the interfering wrong left-hand reaction. The intermanual conflict was still present one year after the onset of symptoms. There was an 'alien hand' phenomenon in the sense that the patient found the behavior of his left hand uncooperative.

3.7. Procedural learning

In order to investigate the patient's ability to acquire new skills with each of the disconnected hands, we trained the patient on a visuomotor co-ordination paradigm.² The task was to steer a cursor (arrow) over a computer screen by moving a common computer mouse with one hand. Similar to Trail Making A, the numbers 1–20 surrounded by circles were randomly distributed over the screen. The task was to hit each circle with the cursor in ascending numerical order. The critical measure was the time needed to hit all 20 circles. Usually, patients only need about five trials to learn how to steer the cursor and to reach an asymptotic performance speed of about 16 s per course. Since the patient had no previous experience in handling a computer mouse, this task required him to learn a new visually guided manual skill.

Training was distributed over five 30 min training sessions. The pattern of the numbered target circles was held constant. In order to ensure that both hemispheres understood what to do, the examiner instructed the patient by demonstrating several times how to move the mouse and to master the task.

We started training by asking the patient to perform the task with his left, dominant hand. Although the patient made a great effort, he was not able to move the cursor in any intended way. After several minutes he gave up exhausted. Following a short break, we asked him to try the task with his right hand. Here, the patient succeeded in moving the cursor over the screen with his non-

Table 6
Development of left apractic errors to imitation

	Dec.	May	Aug.
Total number of tasks	8	8	8
Correct	2	6	6
Substitution	2	1	0
Perseveration	1	0	0
Hand configuration	3	2	2

²Test zum Prozeduralen Lernen. Test and training program by Troppmann N, Gatzweiler B, Keller I (1991). Klinik München Bogenhausen, unpublished.

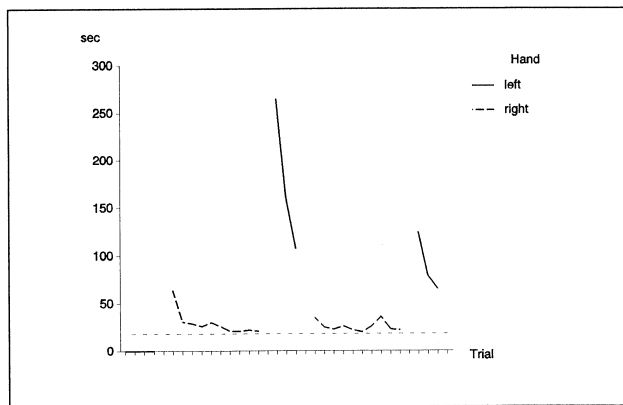


Fig. 4. Initial learning of a visuo-manual skill, task completion times in Session 1. Solid lines represent left hand performance, broken lines right hand performance.

dominant hand (Fig. 4, dotted line); in 10 consecutive trials he made substantial progress in speed and finally reached an asymptotic level. We then asked the patient to try again with his left hand. This time he was able to perform the movement with his left hand; evidently, the task was extremely strenuous and initially took the patient about five times longer to complete the course than with his right hand, but he showed considerable learning progress (Fig. 4, solid line). Since the patient was quickly exhausted by the strain, we stopped left-hand training after three trials and returned to training with the right. In session one, the patient completed two sets of 10 trials with the right hand and two sets of three trials with the left hand (Fig. 4).

In the following sessions, alternating equal training sets of five trials each were used. In session 2 (not shown), the patient completed five training sets with each hand; by the end of the second session, the patient had reached asymptotic speed levels with both hands: His dominant left hand was slightly faster (16.5 s) than his non-dominant right hand (18.0 s) in completing the course.

After the patient had reached a stable performance level with both hands, we wanted to explore the patient's ability to change and modify this consolidated skill. In the third session, after the patient had completed two sets of five trials with each hand, we inverted the position of the computer mouse by 180°. Each movement of the input device had the opposite effect on the cursor on the computer screen, e.g. a mouse movement to the left caused a cursor movement to the right.

The change in the movement-to-effect relationship immediately caused a dramatic slowing of task completion times for both hands but affected them differently (Fig. 5). The left hand adapted to the changed task steadily and reached the former performance level after about five training sets in the next training session (Session 4, Fig. 6). In contrast, there were obvious difficulties with the right hand in mastering the modified task: per-

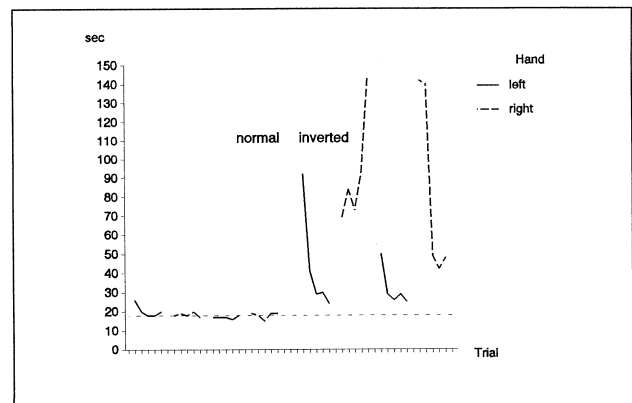


Fig. 5. Relearning of a visuo-manual skill, task completion times in Session 3. In the middle of the session, the manual device (computer mouse) was rotated by 180°.

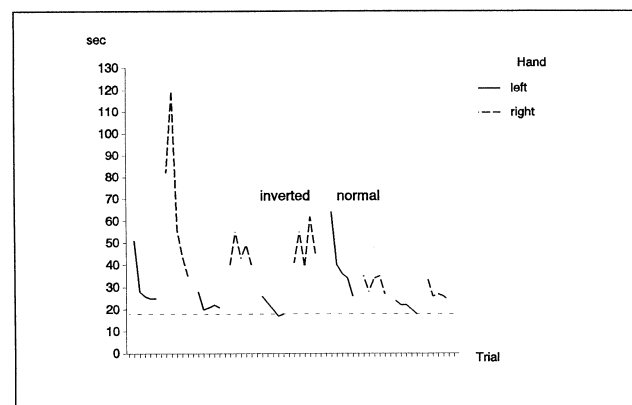


Fig. 6. Re-Relearning of a visuo-manual skill, task completion times in Session 4. In the middle of the session, the inverted position of the manual device (computer mouse) was returned to its original position.

formance was always much slower than with the left hand (Fig. 5) and settled at a completion time that was 2.5 times slower than the former performance level with the same hand (Session 4, Fig. 6).

Finally, we asked whether and how both hands would be able to readapt to the original movement-to-effect mapping. In the fourth session, we changed the mouse back to its original non-inverted position (Fig. 6). In the subsequent training sets, both hands quickly returned to their original performance levels, with the left hand being slightly faster than the right (Session 5 not shown).

4. General discussion

The patient presented with an almost complete callosal disconnection syndrome [3] including unilateral verbal anosmia, hemialexia, unilateral ideomotor apraxia, unilateral agraphia, unilateral tactile anomia, unilateral constructional apraxia, lack of somesthetic transfer, and

dissociative phenomena such as intermanual conflict and alien hand phenomenon. However, no auditory suppression was found in a dichotic listening task with a manual response mode.

Hence, the case supports previous data on callosal syndromes that were mainly obtained in callosotomy subjects by showing that the described symptoms are really caused by the disconnection (and not due to factors such as surgery, perioperative conditions or preexisting epilepsy).

Furthermore, the disconnection syndrome in this left-handed subject basically did not differ from right-handed split-brain patients. Left hemialexia, left visual anomia and left agraphia indicated left hemispheric language dominance. However, the presence of some right hemisphere language competence was suggested by the absence of auditory suppression and the ability to read 45% of the four-letter words presented to the left visual field.

It is also noteworthy that despite his left-handedness, the patient displayed left apraxia even on imitation and that his right hand was more proficient in learning a new motor skill than his left hand. Hence, we assume that there was left-hemispheric dominance for praxis despite his left-handedness. Left apraxia on verbal command and imitation improved over time, but the remaining distal dyspraxia suggested that the improvement in left apraxia was achieved by an increase in ipsilateral proximal control.

The persistent intermanual conflict also indicated that there was no recovery of callosal nor extracallosal pathways for bilateral motor co-ordination.

Since left-handers with a callosal disconnection syndrome are rare, the discussion focusses on those lateralised neuropsychological functions classically associated with handedness, i.e. language, constructional praxis and praxis.

4.1. Left aphasic agraphia

The patient showed left agraphia, since he was not able to write to dictation or spontaneously write correct meaningful words. Thus, as right verbal anosmia, left visual anomia, left alexia, and left tactile anomia also suggested, there was left hemisphere language dominance as is the case in about 70% of left-handers.

However, the motor act of writing was not impaired with the left hand (see also discussion of apraxia). The patient was also able to form letters with the left hand. Since the motor act of writing and forming letters was intact and agraphia was present in composing words from letter cards, the patient's left agraphia should be classified as aphasic agraphia [58].

There was some evidence for improvement of the aphasic agraphia in cursive writing. The increasing visual resemblance to the target word as a whole is described

in right-hemisphere writing [44] and interpreted as an expression of visual word images and whole word retrieval [47]. The concept of visual word images is supported by the fact that there were some distortions in the form of single cursive letters. Evidence for some right hemisphere language competence was described in some split-brain patients [12].

Moreover, the patient was always very astonished to read his neologistic words. This is a common observation in patients with callosal disconnection [7, 22]. The surprise may be attributed to the fact that the reading left hemisphere does not know the words written with the left hand, i.e. generated by the right hemisphere.

Similar to the improvement of aphasic agraphia in our patient, the left-handed patient with left-hemisphere language dominance described by Gur et al. [22] had severe left agraphia after callosotomy which improved after two years to the degree that he was inconsistently able to write some simple three-letter words with his left hand. The left-handed writing was well-formed. Gur [22] assumed that the improvement resulted from the development of ipsilateral pathways. Two facts argue against this. Firstly, ipsilateral control refers mainly to proximal muscles [13, 20, 55] but writing letters depends mainly on wrist motility. Secondly, if left-handed writing was under left-hemisphere control by ipsilateral pathways, the linguistic writing competence of the left hand should correspond to that of the right. However, the left-handed writing was poor with many mistakes and perseveration.

The fact that there was no improvement in block letter writing in our patient requires explanation. Even after eight months, single block letters were correctly written but did never form a meaningful word. In this respect, our patient was similar to the patient of Gersh and Damasio [15], who had a lesion in the splenium and the left parieto-occipital region and could only write his name with the left hand in cursive writing. Otherwise, he correctly wrote block letters without linguistic meaning.

This concurs with the fact that copying block letters may be preserved in callosal syndromes even if the copying of cursive writing is not [3, 60]. Bogen assumes that this may not be an example of printing with the left hand but rather a copying of geometric figures that happen to have linguistic content. This assumption is not supported by our patient, since he consistently copied with the left hand the first two letters of a word written in block letters correctly but was not able to do this with numbers. This should have been possible if only the ability to copy geometric forms was required. Furthermore, the patient spontaneously wrote (wrong) block letters during dictation. Hence, he associated block letters with writing and not with geometric tasks.

The differences between cursive and block letter writing may indicate the existence of two different writing systems. This divergence is comparable to the dis-

sociation between stenography and print [45, 46] as well as between ideograms (one word signs) and phonograms (letters) reported in Japanese patients with callosal disconnection, in whom agraphia is more prominent in phonograms (Kana) than in ideograms (Kanji) [51, 53, 59].

4.2. Auditory suppression

When testing our patient with a dichotic listening task we obtained a pattern of performance that was at variance with the common finding of a strong left-ear suppression in split-brain patients. Our patient was able to respond to verbal input in both ears with a normal accuracy level, even crossed responses (e.g. input to the left ear, response with the right hand) were within normal range. We will discuss firstly whether these differences could be caused by task factors, and secondly we will consider the patient's left-handedness.

The task applied to our patient differs in two aspects from the tasks commonly reported in the literature: There was a motor response format instead of the verbal report mode, and the patient had to respond selectively to stimuli in one ear (selective spatial attention) instead of attending to both ears (divided attention).

With divided attention and a verbal response mode, split-brain patients usually can report only verbal stimuli presented to the right ear. The report of stimuli presented to the left ear is at chance level or significantly below the report of right-ear stimuli [3, 38, 62].

There are only a few studies that have so far investigated the effect of selective attention on the dichotic listening performance in split-brain patients. When the patient is selectively attending to one ear, then the auditory asymmetry is alleviated in many patients. Thus, attending to the left ear can reduce left-ear extinction. However, this effect of selective spatial attention differs considerably between patients [9, 49, 52, 62].

In addition, only a few studies have analysed the performance in dichotic listening tasks with a manual response. In most cases, the manual response was writing down the words that have been perceived or pointing to multiple-choice items on a response sheet [10, 11, 48, 62]. These manual responses still require some degree of linguistic ability in the act of responding (e.g. reading the choice items on the response sheet). In contrast, a simple motor action like pressing a button does not demand verbal processing while producing the response. Administering the task with a key-pressing response, Wale and Geffen [57] showed that, at least in some patients, both disconnected hemispheres were able to analyse the verbal input (words) and to generate correct responses. Even crossed responses could be performed with above chance accuracy.

By and large, our results are in line with the findings that were obtained under similar task conditions. When

tested with a motor response both isolated hemispheres were able to indicate the detection of target words from both ears [57]. When tested with selective spatial attention, then the right-ear advantage was alleviated and in some patients abolished. Our results complement these findings by providing data on the combination of spatial selective attention and a key-pressing response mode. To our knowledge this combination has not been used in previous studies.

The finding of a strong left-ear suppression with a verbal response mode and the lack of left-ear suppression with a motor response mode advocates the conclusion that the ear asymmetries do indicate above all the differences in the expressive language abilities of the hemispheres. Thus, the common finding of a strong right-ear advantage with verbal report indicates the better ability of the left hemisphere in naming the auditory verbal stimuli. Only if the response demands for both hemispheres are similar, then will the performance in dichotic listening tasks supply information on differences between the hemispheres in their ability to perceive verbal input. Our procedure, as well as Wale and Geffen's [57], used such a language free response mode.

The finding that both isolated hemispheres were able to indicate the detection of the target words from both ears suggests the assumption that the right hemisphere has some ability to decode verbal input. This receptive processing does not need to be very deep and elaborated. In our task it is sufficient that an invariant acoustic pattern, the target digit, is detected and responded to by pressing a button. Whether this ability of the right hemisphere is interpreted as a limited competence for verbal comprehension or as a competence to detect sound patterns is a still controversial question (cf. the discussions in [3, 6, 48, 62]).

The asymmetry of performance between both hands in our patient (higher detection accuracy when responding with the right hand) can be explained by a higher proficiency of the left hemisphere, compared to the right, in decoding auditory verbal input [57]. However, we have no explanation for the asymmetry between the ears (slightly higher detection accuracy for input to the left ear). We do not want to put too much emphasis on the pattern of ear-asymmetry found in this dichotic listening task. Since we did not have the opportunity to replicate this test, we cannot evaluate the stability of our results. However, the data do warrant the conclusion that both disconnected hemispheres were capable of detecting the target digit with an accuracy within normal range, and that each hemisphere had access to input from both ears.

Considering the left-handedness of our patient, the pattern of performance gave no indication of a deviant cerebral lateralization of receptive and productive language. Like other results reported in this article, the performance in this dichotic listening task was in accord with the assumption of a language dominant left hemi-

sphere. In spite of the fact that there was a strong difference in performance depending on the hand used in responding, this effect obviously was not influenced by the patients left-handedness.

4.3. *Right and left constructional apraxia*

The patient had a severe right and a mild left constructional apraxia. In this respect, his deficits were similar to the right-handed patients of Habib [23] and Boldrini [4], who also had mild apraxia of the left hand in addition to their severe right constructional apraxia. These observations agree with the findings that lesions in both hemispheres can produce constructional apraxia. In certain constructional tasks, such as three-dimensional block building and copying designs, the impairment is more frequent and more severe in patients with right-hemisphere lesions [2]. Hence, our patient's constructional abilities seem to be organized in the same way as those in right-handers.

4.4. *Left apraxia to imitation and verbal command*

Our patient showed left apraxia on verbal command and imitation with intact spontaneous behaviour in routine motor tasks. This finding concurs with Liepmann's original proposal [34] that both hemispheres contain motor engrams for routine tasks but only the left hemisphere (in right-handers) can translate a new movement idea into motor execution. Several cases of patients with acute non-surgical callosal lesions and severe apraxia on verbal command and imitation and/or object use [20, 21, 23, 30, 31, 58] support Liepmann's hypothesis.

In other cases, callosal apraxia was observed only on verbal command and the ability to imitate and to use objects was not impaired [6, 13, 17, 60]. In these cases, callosal apraxia is sufficiently explained by a verbal-motor disconnection, but this hypothesis does not explain the existence of apraxia on imitation and object use.

It is still not known why these different types of apraxia exist. Variations in brain organization may explain the difference, i.e. different degrees of motor dominance [21] or the existence of bilateral movement representation [27, 31]. In some cases the possibility of substantial neural reorganization due to preexisting cerebral lesions has also to be taken into consideration [13].

The different descriptions of apraxia may also reflect differences in examination techniques. Since apraxia on imitation may manifest solely in imitation tasks for the distal part of the limb, e.g. finger positions, the apraxia may have been missed [6, 17].

Different sites and extent of the lesions in the corpus callosum also have some bearing on the different types of apraxia. All these cases of apraxia on imitation share a lesion in the body of the corpus callosum [4, 20, 21, 23, 30, 31, 58]. However, a topographic distinction in

comparison to the cases with apraxia on verbal command alone cannot be elaborated from these data. More cases are needed with precise localization of the lesion by brain imaging performed at the time of neuropsychological examination.

Analysing the improvement in apraxia in our patient provides further clues on the cortical mechanisms involved in praxis. Initially, on verbal command the patient showed severe apractic errors such as substitution and perseveration. He improved significantly in apraxia on verbal command and imitation, but it was striking that hand/finger configuration errors persisted. After eight months, he was still not able to perform such tasks as bending the little finger or crossing fingers on imitation nor on verbal command. This concurs with previous descriptions of patients after callosal disconnection, whose apractic disturbances were mainly evident in the distal part of the limb, affecting finger more than hand and arm gestures [4, 13, 58]. These findings support the hypothesis that improvement in unilateral apraxia in split-brain patients results from an increase in ipsilateral control which can mainly be gained for proximal movements [55, 56]. The supplementary motor area is assumed to have bilateral direct efferent pathways only to proximal muscles [20].

4.5. *Motor dominance and handedness*

The apractic symptomatology of our patient corresponds to cases of callosal syndromes in right-handers [4, 21, 23, 30, 31, 35, 58]. Analogously, we assume that although our patient is a left-hander his left hemisphere has motor dominance. This agrees with the observation that in many left-handers ideomotor apraxia has been observed following left-sided or bilateral lesions [24, 25] whereas reports of apraxia in left-handers after right-hemispheric brain damage are rare [26, 36, 43]. Hence, handedness seems to be a factor independent of the lateralization of motor dominance for praxis.

The development of skill acquisition in the training study shows the dissociation of handedness and the competencies controlling the learning of new movement patterns. Although the patient was left-handed, he was initially unable to perform the new task with the left hand; instead only the right, non-dominant hand was capable of executing the new movement. We interpret this finding as evidence for left-hemisphere dominance in the intentional control of new movements.

In the course of the training, the patient learned to master the task with both hands. Thus, both isolated hemispheres were capable of acquiring the new skill. Handedness seemed to be irrelevant in the initial stages of skill acquisition: left-handedness did not prevent left-sided apraxia. Moreover, once skilful performance was established and performance was no longer apractic, the handedness, i.e. the superiority of the left hand in fine

motor tasks, reappeared. This was evident in daily life skills as well; even after the callosal infarction the patient still performed his routine tasks (shaving etc.) faster with the left than with the right hand.

Hence, the cerebral motor systems establishing handedness must be separate from the cerebral lateralization of motor dominance. Since handedness effects are preserved after complete callosal disconnection, it seems likely that differences in efficiency between both hands result from differences in local, intrahemispheric motor control systems.

A rather unexpected finding of the training study was the difference in the ability of both hands to modify the initial movement pattern. Since the left hemisphere was much faster in initially learning the task, we expected the right hand to be more efficient in modifying the movement pattern. However, it was the left hand that adapted very quickly to the inverted movement pattern while the right showed considerable difficulties even after many training sessions.

Thus, the performance of a new movement pattern in a task situation, in which another, mirror-inverted movement pattern had already been well established, must be different from learning a completely new skill. While the initial acquisition of the skill was considerably disturbed by left-sided apraxia, no signs of left apraxia were present in the modification of the movement pattern. This finding is noteworthy, since the relearning process may require at least the same degree of intentional control as initial learning. The better relearning performance of the left hand could be explained by the assumption that relearning was accomplished by adding a mirror transformation to the existing movement pattern. This spatial transformation may be much easier for the right hemisphere than for the left.

Despite left-handedness, the callosal disconnection syndrome is analogous to that in right-handers revealing left-hemispheric dominance for language and praxis. It is noteworthy that motor dominance and handedness seem to be hemispherically separate functions. Furthermore, we speculate that the improvement in left apraxia is presumably due to a compensatory increase in ipsilateral proximal muscle control whereas left agraphia seemed to improve by an increase in right-hemisphere language competence.

Acknowledgements

Neuropsychological testing was performed at the Universitätsklinikum Benjamin Franklin der Freien Universität Berlin and the Städtische Klinik München-Bogenhausen. We wish to thank our staff colleagues whose discussions and reports substantially contributed to an understanding of the patient's condition, particularly to: Dr G. Curio, Dr T. Bak, Prof Dr G. Gol-

denberg, Prof Dr D. Y. von Cramon, Dr S. Stein, A. Gensberger, R. Götze, M. Mebus, I. Schnell, Dr H. Schröter-Morasch and E. Stögerer.

References

- [1] Aptman M, Levin H, Senelick RC. Alexia without agraphia in left-handed patient with prosopagnosia. *Neurology* 1977;27:533–6.
- [2] Benton A, Tranel D. Visuo-perceptual, visuo-spatial, and visuo-constructive disorders. In: Heilman KM, Valenstein E, editors. *Clinical neuropsychology*. New York: Oxford University, 1993:165–213.
- [3] Bogen JF. The callosal syndromes. In: Heilman KM, Valenstein E, editors. *Clinical neuropsychology*. New York: Oxford University, 1993:337–407.
- [4] Boldrini P, Zanella R, Cantagallo A, Basaglia N. Partial hemispheric disconnection syndrome of traumatic origin. *Cortex* 1992;28:135–43.
- [5] Botez MI, Crighel E. Partial disconnection syndrome in an ambidextrous patient. *Brain* 1971;94:487–94.
- [6] Bradshaw JL. Methods for studying human laterality. In: Boulton AA, Baker GB, Hiscock M, editors. *Neuromethods*, vol. 17: *Neuropsychology*. Clifton, N.J.: Humana Press, 1990:225–80.
- [7] Brion S, Jedynak CP. Troubles du transfert interhémisphérique (callosal disconnection). A propos de trois observations de tumeurs du corps calleux. Le signe de la main étrangère. *Revue Neurologique* 1972;126:257–66.
- [8] Broadbent DE. The role of auditory localization in attention and memory span. *Journal of Experimental Psychology* 1954;47:191–6.
- [9] Clarke JM, David AS, Zaidel E. Dichotic listening performance during selective attention in commissurotomy and hemispherectomy patients. *Journal of Clinical and Experimental Neuropsychology* 1993;155:36–7.
- [10] Clarke JM, Lufkin RB, Zaidel E. Corpus callosum morphometry and dichotic listening performance: individual differences in functional interhemispheric inhibition? *Neuropsychologia* 1993;31:547–57.
- [11] Dimond SJ, Scammell RE, Brouwers EYM, Weeks R. Functions of the centre section (trunc) of the corpus callosum in man. *Brain* 1977;100:543–62.
- [12] Gazzaniga MS. Right hemisphere language following brain bisection: a 20-year perspective. *American Psychologist* 1983;38:525–37.
- [13] Gazzaniga MS, Bogen J, Sperry R. Dyspraxia following diversion of the cerebral commissures. *Archives of Neurology* 1967;16:606–12.
- [14] Geffen G, Quinn K. Hemispheric specialization and ear advantages in processing speech. *Psychological Bulletin* 1984;96:273–91.
- [15] Gersh F, Damasio AR. Praxis and writing of the left hand may be served by different callosal pathways. *Archives of Neurology* 1981;38:634–6.
- [16] Geschwind IN. The frequency of callosal syndromes in neurological practice. In: Reeves AG, editor. *Epilepsy and the corpus callosum*. New York: Plenum, 1985:349–56.
- [17] Geschwind N, Kaplan E. A human cerebral disconnection syndrome. *Neurology* 1962;12:675–85.
- [18] Giroud M, Dumas R. Clinical and topographical range of callosal infarction: a clinical and radiological correlation study. *Journal of Neurology, Neurosurgery, and Psychiatry* 1995;59:238–42.
- [19] Goldenberg G. Defective imitation of gestures in patients with damage in the left or right hemispheres. *Journal of Neurology, Neurosurgery and Psychiatry* 1996;61:176–80.
- [20] Goldenberg G, Wimmer A, Holzner F, Wessely P. Apraxia of the

- limbs in a case of callosal disconnection: the contribution of medial frontal lobe damage. *Cortex* 1985;21:135–48.
- [21] Graff-Radford NR, Welsh K, Godersky J. Callosal apraxia. *Neurology* 1987;37:100–5.
 - [22] Gur RE, Gur RC, Sussman NM, O'Connor MJ, Vey MM. Hemispheric control of the writing hand: the effect of callosotomy in a left-hander. *Neurology* 1984;34:904–8.
 - [23] Habib M, Ceccaldi M, Poncet M. Syndrome de déconnexion calleuse par infarctus jonctionnel hémisphérique gauche. *Revue Neurologique* 1990;146:119–24.
 - [24] Hécaen H, Ajuriaguerra J. Left handedness. New York: Grune and Stratton, 1964.
 - [25] Hécaen H, Sauguet J. Cerebral dominance in left-handed subjects. *Cortex* 1971;7:18–48.
 - [26] Heilman KM, Coyle JM, Gonyea EF, Geschwind N. Apraxia and agraphia in a left-hander. *Brain* 1973;96:221–8.
 - [27] Heilman KM, Rothi LJG. Apraxia. In: Heilman KM, Valenstein E, editors. *Clinical neuropsychology*. New York: Oxford University, 1993:141–63.
 - [28] Huber W, Poeck K, Weniger D, Willmes K. *Aachener Aphasie Test*. Göttingen: Hogrefe, 1983.
 - [29] Karnath HO. Deficits of attention in acute and recovered visual hemineglect. *Neuropsychologia* 1988;26:27–43.
 - [30] Kashiwagi A, Kashiwagi T, Nishikawa T, Tanabe H, Okuda I. Hemispatial neglect in a patient with callosal infarction. *Brain* 1990;113:1005–23.
 - [31] Leiguarda AR, Starkstein S, Berthier M. Anterior callosal haemorrhage: a partial interhemispheric disconnection syndrome. *Brain* 1989;112:1019–37.
 - [32] Levy J, Trevarthen C. Perceptual, semantic, and phonetic aspects of elementary language processes in split-brain patients. *Brain* 1977;100:105–18.
 - [33] Liepmann H. Das Krankheitsbild der Apraxie ('motorische Asymbolie') auf Grund eines Falles von einseitiger Apraxie. *Monatsschrift für Psychiatrie und Neurologie* 1900;VIII(3):182–97.
 - [34] Liepman H. Drei Aufsätze aus dem Apraxiegebiet. Berlin: Karger, 1908.
 - [35] Liepmann H, Maas O. Fall von linksseitiger Agraphie und Apraxie bei rechtseitiger Lähmung. *Journal für Psychologie und Neurologie* 1907;X(4/5):214–27.
 - [36] Margolin DI. Right hemisphere dominance for praxis and left hemisphere dominance for speech in a left-hander. *Neuropsychologia* 1980;18:715–9.
 - [37] Mesulam MM. A cortical network for directed attention and unilateral neglect. *Annals of Neurology* 1981;10:309–325.
 - [38] Milner B, Taylor L, Jones-Gotman M. Lessons from cerebral commissurotomy: auditory attention, haptic memory, and visual images in verbal associative-learning. In: Trevarthen CB, editor. *Brain circuits and functions of the mind. Essays in honor of R. W. Sperry*. New York: Cambridge University Press, 1990:293–303.
 - [39] Oldfield RC. The assessment and analysis of handedness: The Edinburgh Inventory. *Neuropsychologia* 1971;9:236–47.
 - [40] Pigache RM. Comparison of scoring methods for tests of attention, including an error index for use with schizophrenic patients. *Perceptual and Motor Skills* 1976;42:243–53.
 - [41] Pigache RM. The clinical relevance of an auditory attention task (PAT) in a longitudinal study of chronic schizophrenia, with placebo substitution for chlorpromazine. *Schizophrenia Research* 1993;10:39–50.
 - [42] Poeck K. Apraxie. In: Poeck K, editor. *Klinische Neuropsychologie*. New York: Georg Thieme, 1989:188–206.
 - [43] Poeck K, Kerschensteiner M. Ideomotor apraxia following right-sided cerebral lesion in a left-handed subject. *Neuropsychologia* 1971;9:359–61.
 - [44] Rapsak SZ. Writing with the right hemisphere. *Brain and Language* 1991;41:510–30.
 - [45] Regard M, Landis T, Graves R. Dissociated hemispheric superiorities for reading stenography vs print. *Neuropsychologia* 1985;23:431–35.
 - [46] Regard M, Landis T, Hess K. Preserved stenography reading in a patient with pure alexia. A model for dissociated reading processes. *Archives of Neurology* 1985;42:400–2.
 - [47] Roeltgen DP. Agraphia. In: Heilman KM, Valenstein E, editors. *Clinical neuropsychology*. New York: Oxford University, 1993:63–89.
 - [48] Sidtis JJ, Volpe BT, Wilson DH, Rayport M, Gazzaniga MS. Variability in right hemisphere language function after callosal section: evidence for a continuum of generative capacity. *The Journal of Neuroscience* 1981;3:323–31.
 - [49] Sparks R, Geschwind N. Dichotic listening in man after section of neocortical commissures. *Cortex* 1968;4:3–16.
 - [50] Spreen O, Strauss E. *A compendium of neuropsychological tests*. New York: Oxford University, 1991.
 - [51] Sugishita M, Toyokura Y, Yoshioka M, Yamada R. Unilateral agraphia after section of the posterior half of the truncus of the corpus callosum. *Brain and Language* 1980;9:215–25.
 - [52] Sugishita M, Otomo K, Yamazaki K, Shimizu H, Yoshioka M, Shinohara A. Dichotic listening in patients with partial section of the corpus callosum. *Brain* 1995;118:417–27.
 - [53] Tei H, Soma Y, Maruyama S. Right unilateral agraphia following callosal infarction in a left-hander. *European Neurology* 1994;34:168–72.
 - [54] Teres U. *HAWIE-R: Hamburg-Wechsler Intelligenztest für Erwachsene; Handbuch und Testanweisung*. Bern: Huber, 1991.
 - [55] Volpe BT. Motor control in patients with callosal section. In: Reeves AG, editor. *Epilepsy and the corpus callosum*. New York: Plenum 1985:381–91.
 - [56] Volpe BT, Sidtis JJ, Holtzman JD, Wilson DH, Gazzaniga MS. Cortical mechanisms involved in praxis: observations following partial and complete section of the corpus callosum in man. *Neurology* 1982;32:645–50.
 - [57] Wale J, Geffen G. Hemispheric specialization and attention: effects of complete and partial callosal section and hemispherectomy on dichotic monitoring. *Neuropsychologia* 1986;24:483–96.
 - [58] Watson RT, Heilman KM. Callosal apraxia. *Brain* 1983;106:391–403.
 - [59] Yamadori A, Osumi Y, Ikeda H, Kanazawa Y. Left unilateral agraphia and tactile anomia. *Archives of Neurology* 1980;37:88–91.
 - [60] Zaidel D, Sperry RW. Some long-term motor effects of cerebral commissurotomy in man. *Neuropsychologia* 1977;15:193–204.
 - [61] Zaidel E, Peters AM. Phonological encoding and ideographic reading by the disconnected right hemisphere: two case studies. *Brain and Language* 1981;14:205–34.
 - [62] Zaidel E, Zaidel DW, Bogen JE. Testing the commissurotomy patient. In: Boulton AA, Baker GB, Hiscock M, editors. *Neuromethods, vol. 17: Neuropsychology*. Clifton, N.J.: Humana Press, 1990:147–201.