

Endovascular Recanalization with Balloon Angioplasty and Stenting of an Occluded Occipital Sinus for Treatment of Intracranial Venous Hypertension: Technical Case Report

Adel M. Malek, M.D., Ph.D., Randall T. Higashida, M.D., Peter A. Balousek, M.D., Constantine C. Phatouros, F.R.A.C.R., Wade S. Smith, M.D., Christopher F. Dowd, M.D., Van V. Halbach, M.D.

Department of Radiology (AMM, RTH, PAB, CCP, CFD, VVH), Division of Interventional Neurovascular Radiology, and Departments of Neurosurgery (RTH, CFD, VVH) and Neurology (WSS), University of California at San Francisco, San Francisco, California

OBJECTIVE AND IMPORTANCE: Dural sinus thrombosis can lead to intracranial venous hypertension and can be complicated by intracranial hemorrhage. We present a case report of a patient who underwent endovascular recanalization and stenting of a thrombosed occipital sinus.

CLINICAL PRESENTATION: A 13-year-old patient with a history of chronic sinus thrombosis refractory to anticoagulant therapy presented with acute onset of aphasia and hemiparesis. Computed tomography and magnetic resonance imaging revealed hydrocephalus and cerebral edema. Angiography delineated multiple dural arteriovenous fistulae and persistent occlusion of the posterior sagittal, occipital, and bilateral transverse dural sinuses with retrograde cortical venous drainage.

INTERVENTION: After embolization of the dural arteriovenous fistulae, a transvenous approach was used to recanalize and perform balloon angioplasty of the right internal jugular vein and the occipital and left transverse sinuses, resulting in subsequent clinical improvement. The patient's condition deteriorated 3 days later with reocclusion of both balloon-dilated sinuses. Repeat angioplasty and then deployment of an endovascular stent in the occipital sinus were performed, and reestablishment of venous outflow was achieved, resulting in a decrease of intracranial venous pressure from 41 to 14 mm Hg and neurological improvement. At the 3-month follow-up examination, the stented occipital sinus remained patent and served as the only conduit for extracranial venous outflow; the patient remained neurologically intact at the 12-month follow-up examination.

CONCLUSION: This is the first report of mechanical recanalization, balloon angioplasty, and stent deployment in the occipital sinus to provide sustained venous outflow for the treatment of venous hypertension with retrograde cortical venous drainage in a patient with dural pansinus thrombosis refractory to anticoagulant therapy. (*Neurosurgery* 44:896-901, 1999)

Key words: Cerebral edema, Dural arteriovenous fistula, Hemiplegia, Interventional neuro-radiology, Neurological deficit, Vascular malformation, Venous sinus thrombosis

Venous sinus thrombosis can result in intracranial venous hypertension and can be complicated by intracranial hemorrhage. This condition usually responds to systemic anticoagulation, which is recommended even in the presence of intracranial hemorrhage (5). For patients whose conditions fail to improve despite anticoagulation, a number of reports have described good clinical success using direct endoluminal infusion of urokinase for reestablishing sinus patency (9, 16, 18). We herein describe the first case of mechanical recanalization, balloon angioplasty, and endoluminal stent placement within the occipital sinus for the treatment of intracranial venous hypertension in a patient with long-standing dural pansinus thrombosis and acute clinical deterioration despite systemic anticoagulation. We discuss the clinical management and technical aspects of the case, provide angiographic follow-up at 3 months and clinical follow-up at 1 year, and discuss dural arteriovenous fistula (DAVF) pathogenesis.

CLINICAL PRESENTATION

This 13-year-old male patient had a history of a fall from a tree and had presented with headache and pulsatile tinnitus 15 months before the current admission. At that time, magnetic resonance (MR) imaging and diagnostic angiography revealed that the patient was suffering from spontaneous dural pansinus thrombosis of the superior sagittal sinus, straight sinus, bilateral transverse sinuses, and occipital sinus, and he underwent a laboratory workup for a hypercoagulable state, the results of which were negative. His first angiogram revealed no arteriovenous shunts. He was treated for 7 months with a regimen of orally administered warfarin and aspirin but presented at the time of the current admission with aphasia, right hemiparesis, and engorged scalp veins. MR imaging and computed tomography showed no evidence of cortical infarct or intraparenchymal hemorrhage (*Fig. 1*) but demonstrated dilated temporal horns and effacement of the basal cisterns, consistent with hydro-

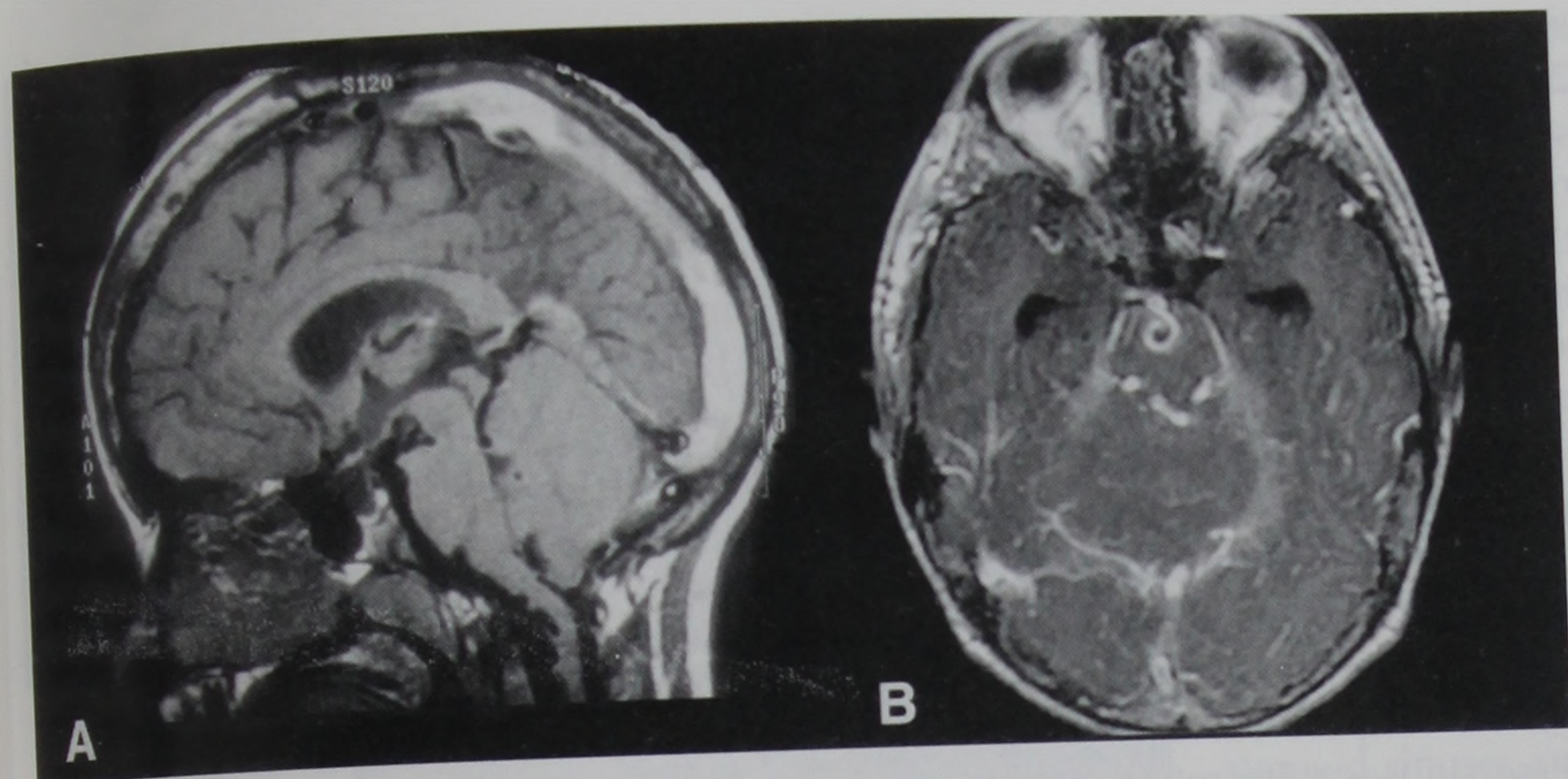


FIGURE 1. A, sagittal T1-weighted MR image of the head, without contrast enhancement, demonstrating edema in the posterior fossa and associated tonsillar ectopia, consistent with venous hypertension and edema. B, axial T1-weighted postgadolinium MR image showing dilated temporal horns and effaced basal cisterns with dilated cortical veins.

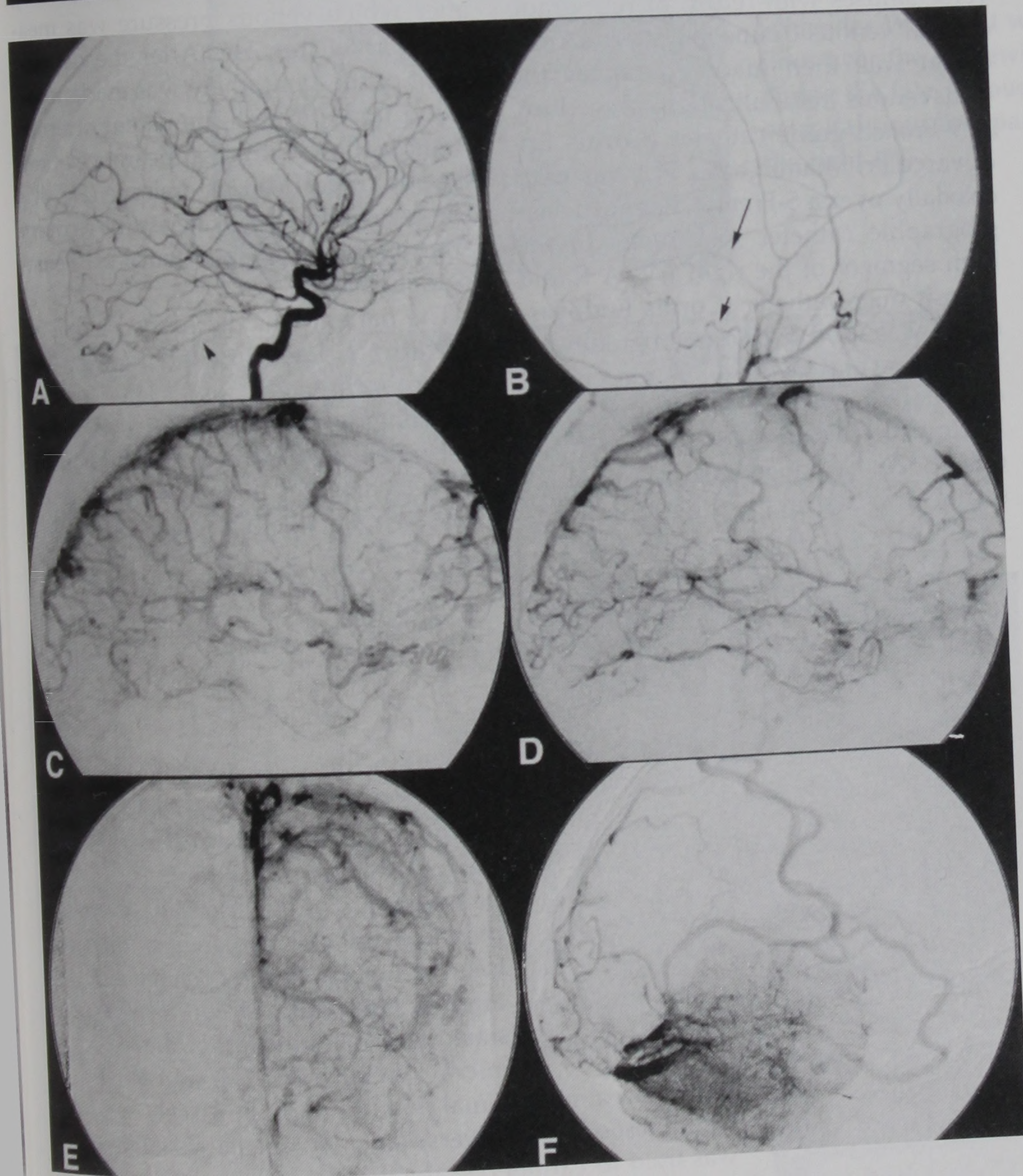


FIGURE 2. A, lateral projection arterial phase digital subtraction angiogram (DSA) of the left internal carotid artery (ICA), showing early arteriovenous shunting from the meningo-hypophyseal trunk to a DAVF in the region of the transverse sinus (arrowhead). B, arterial phase DSA of a left external carotid injection, revealing dural arteriovenous shunting from the ascending pharyngeal artery (short arrow) and from the posterior branch of the anterior division of the middle meningeal artery (long arrow). Late venous phase angiograms of the left ICA in the lateral (C) and anteroposterior (E) projections, the right ICA the lateral projection (D), and the left vertebral artery in the lateral projection (F) confirm venous sinus thrombosis in the posterior region of the superior sagittal sinus, both transverse sinuses, and the torcular herophili. Venous drainage is via cortical veins with diversion to the deep venous system and diversion anteriorly to the cavernous sinus via transcortical pathways. The anterior falcine sinus is patent.

cephalus and cerebral edema. The deep venous structures were sufficiently dilated so as to distort the brain stem and result in cerebellar ectopia; there was no evidence of intraparenchymal hemorrhage. Diagnostic angiography revealed multiple DAVFs involving separately the right transverse-sigmoid junction (Fig. 2,

A and B), the left transverse sinus, the superior sagittal sinus, and the occipital sinus. The right transverse sinus was noted to be occluded, as was the superior sagittal sinus at its junction with the torcular herophili. Venous drainage was retrograde via the anterior portion of the superior sagittal sinus via collateral ve-

nous channels to bilateral cavernous sinuses and transosseous channels to the scalp (Fig. 1, C-F). Of clinical importance was the presence of retrograde cortical venous drainage into a large posterior temporoparietal vein, which may, in part, have been responsible for the patient's left hemispheric ischemia. A combination of

superselective transarterial and transvenous approaches was used to embolize the dural arteriovenous fistulae, with a resulting decrease in the amount of arteriovenous shunting.

A transvenous approach was then undertaken, and a diagnostic angiographic catheter was positioned in the high cervical left internal jugular vein (IJV) where multiple attempts at catheterizing the left sigmoid sinus were unsuccessful. The catheter was then placed in the right IJV, and attempts at recanalizing the right sigmoid sinus were again unsuccessful. A channel was, however, found in the posterior medial right jugular bulb. Recanalization along this channel using a microwire/microcatheter combination led to the occipital sinus, torcular herophili, and then to the left transverse sinus. Measurement of the venous pressure yielded 41 mm Hg in the left transverse sinus. An angioplasty balloon catheter was guided over an exchange guidewire and used to balloon-dilate, in an overlapping fashion, the stenotic and partially thrombosed occipital sinus, left transverse sinus, and a stricture at the transverse-sigmoid junction (Fig. 3). After angioplasty, occipital

sinus venous pressure was measured at 21 mm Hg and antegrade flow was observed down the occipital sinus to the right IJV and the left transverse down to the left IJV with disappearance of the retrograde cortical venous drainage pattern. The patient's mental status improved and hemiparesis cleared within 12 hours of the procedure, but he developed several transient episodes of aphasia 3 days later, prompting reevaluation.

Repeat angiography revealed reocclusion of the previously recanalized and dilated occipital sinus and right transverse sinuses with return of retrograde cortical venous drainage pattern. A decision was then made to repeat the transvenous recanalization procedure. A 9-French guide catheter (Cordis Endovascular, Miami Lakes, FL) was used coaxially over a 5-French diagnostic angiographic catheter to catheterize the high segment of the right IJV. A Rapid Transit microcatheter (Cordis Endovascular) was used over a microguidewire to traverse and navigate the reoccluded occipital sinus, torcular herophili, and left transverse sinus and into the left IJV (Fig. 4). An exchange wire was then inserted over the microcatheter and ad-

vanced to the level of the innominate vein. A balloon was then passed over the exchange wire and used to perform balloon angioplasty of the entire venous pathway from the right IJV, occipital sinus, left transverse sinus, and left IJV. The venous pressure measurement revealed a value of 21 mm Hg. An 8 × 40-mm Schneider WallStent (Schneider Inc., Plymouth, MN) was then inserted over the guidewire and deployed in the occipital sinus. The stent was then post-dilated using an Optra 5 balloon angioplasty catheter (Cordis Endovascular), after which venous pressure was measured at 14 mm Hg. After the deployment of the stent, there was evidence of blood flow through the patent occipital sinus outflow with disappearance of retrograde cortical venous drainage (Fig. 4C). The patient made an uneventful recovery from the procedure and remained neurologically intact.

The patient was discharged home on warfarin, ticlopidine, and aspirin. The patient returned 3 months later, and repeat angiography revealed the persistent patency of the occipital sinus stent as the major extracranial outflow pathway, with no evidence of cortical ve-

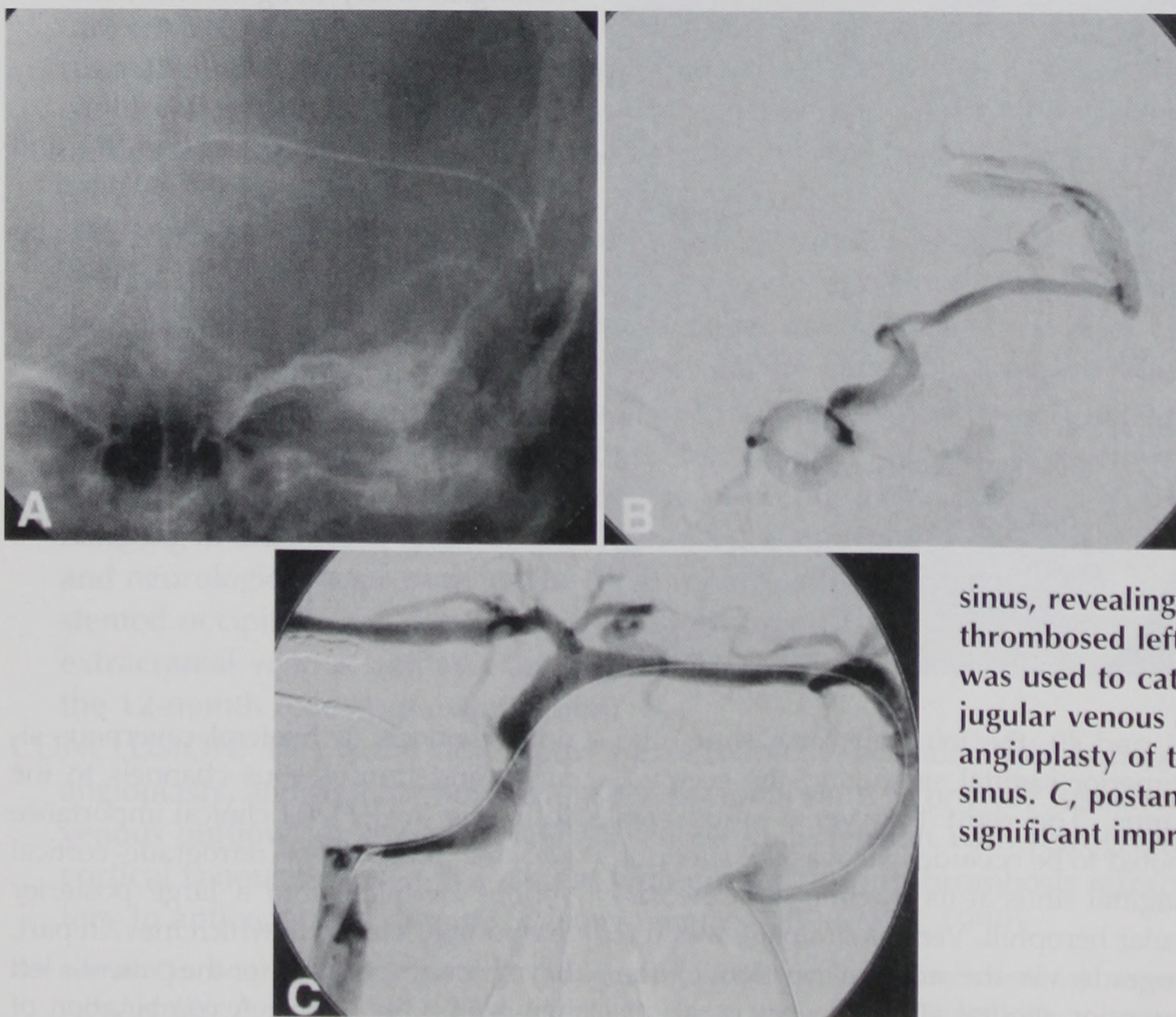


FIGURE 3. *A*, recanalization using a femoral transvenous approach of the occipital and left transverse sinuses. Anteroposterior projection fluorographic of the cranium, revealing the microcatheter course from the right internal jugular to the occipital sinus, torcular herophili, and left transverse sinus. *B*, distal injection of the microcatheter in the left transverse sinus, revealing minimal flow through the largely thrombosed left transverse sinus. An exchange guidewire was used to catheterize the left IJV from a right internal jugular venous approach and was used to perform balloon angioplasty of the occipital sinus and the left transverse sinus. *C*, postangioplasty venous injection revealing the significant improvement in venous outflow.

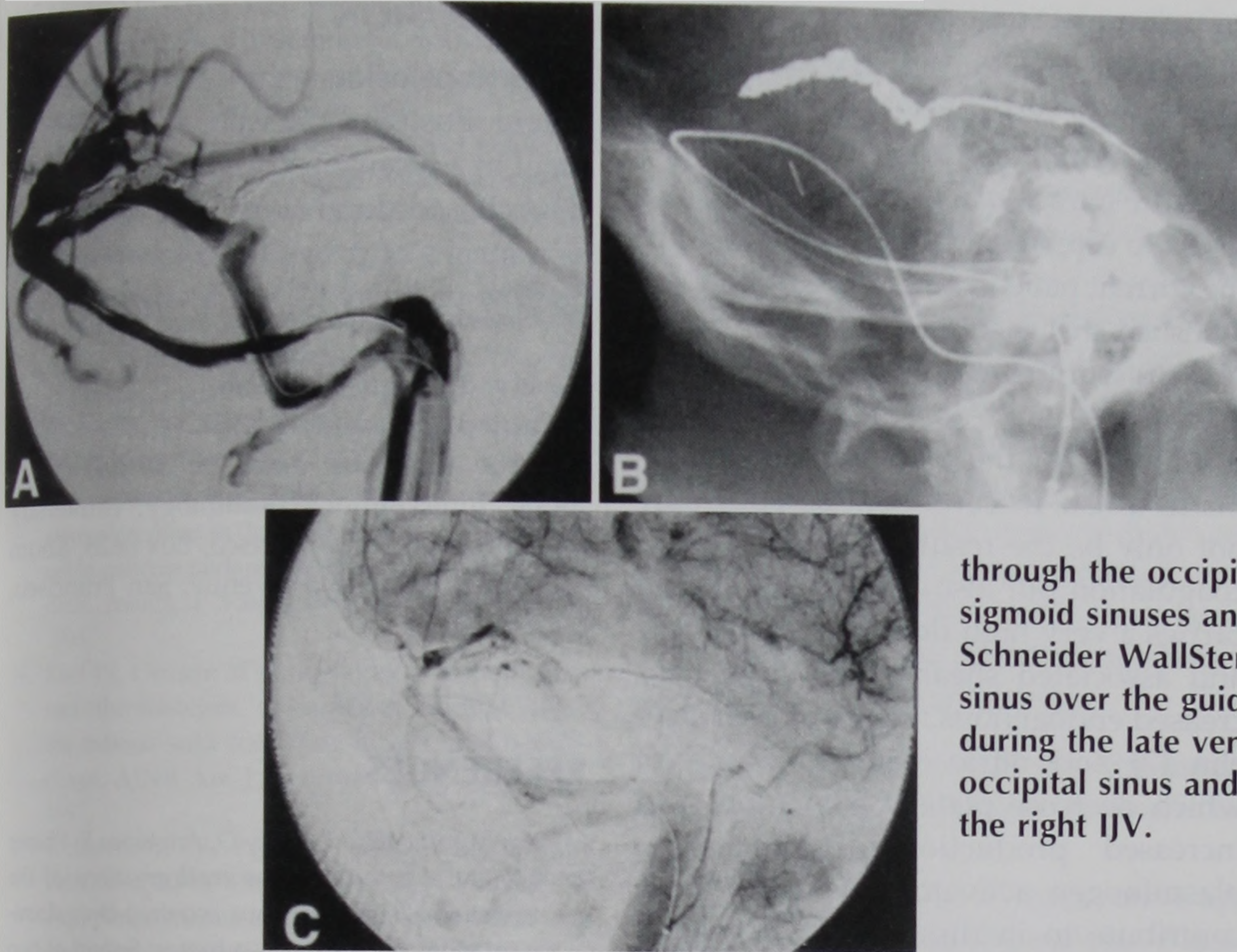


FIGURE 4. Patient was taken back to the neuroangiography suite 3 days after undergoing angioplasty and experiencing worsening episodes of aphasia despite continued intravenous anticoagulation. Angiography revealed reocclusion of the previously balloon-dilated segments (not shown).

A, femoral transvenous approach was again undertaken to pass a guidewire through the occipital sinus and to the left transverse and sigmoid sinuses and down into the IJV. B, 8 × 40-mm Schneider WallStent was then deployed in the occipital sinus over the guidewire. C, DSA of the left ICA, obtained during the late venous phase, demonstrating patency of the occipital sinus and passage of angiographic contrast to the right IJV.

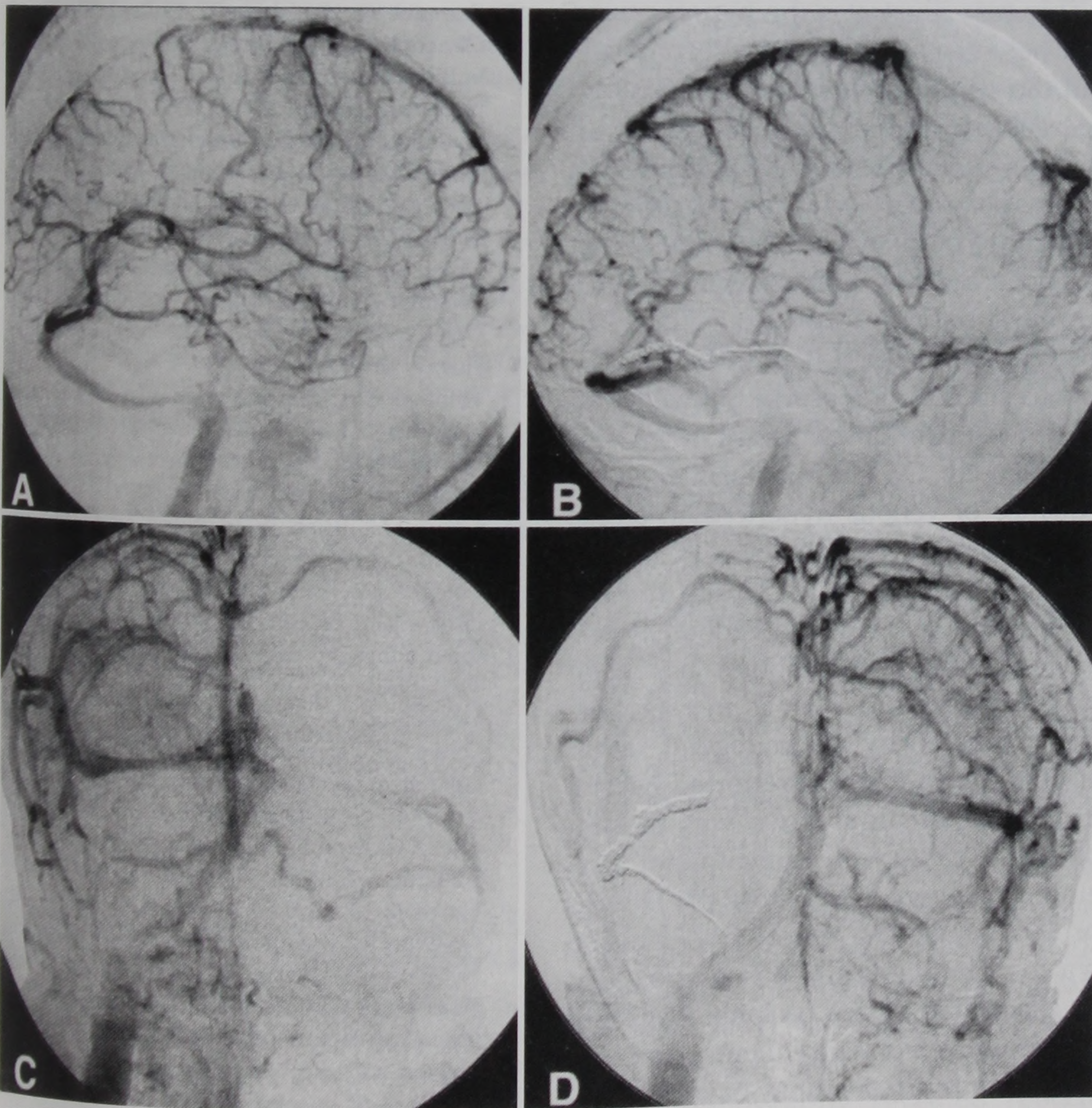


FIGURE 5. Follow-up diagnostic DSA, obtained at 3 months during the late venous phase, of the right (A and C) and left (B and D) ICAs in the lateral and anteroposterior projections, respectively. The angiograms demonstrate continued patency of the stented occipital sinus, which constitutes the sole outflow among the major venous sinuses. Note that the previously balloon-dilated but nonstented left transverse sinus is occluded.

nous drainage (Fig. 5). No new DAVFs were found. All previously treated DAVFs were closed, except for one involving the right transverse sinus,

which underwent repeat transarterial embolization using absolute ethanol via its ascending pharyngeal and posterior division of the left middle meningeal

artery feeders. After stent placement, the patient remained without neurological symptoms or deficits at 1 year of clinical and neurological follow-up.

DISCUSSION

Dural sinus thrombosis is usually treated using systemic anticoagulation, even in the presence of intraparenchymal hemorrhage (5). A number of reports have also described the use of superselective infusion of thrombolytics through an indwelling catheter via both a transjugular and transvenous approach, with good success (2, 9, 16, 18). Although superselective thrombolysis using urokinase (Abokinase; Abbott Labs, Chicago, IL) was considered for the current patient, there was significant concern regarding its potential efficacy, considering the patient's extensive and long-standing venous sinus thrombosis. Although the patient's symptoms initially improved with embolization of the multiple DAVFs, he suffered recurrence of dysphasia, most likely as a result of ischemia produced by documented venous hypertension. This is emphasized by the observed clinical improvement after mechanical recanalization and angioplasty of the occipital and left transverse sinuses. The value of stent deployment in this patient was evident after recanalization with balloon angioplasty and systemic anticoagulation failed to maintain the patency of the occipital and left transverse sinuses for longer than 3 days.

Intravascular stents are being used increasingly for the treatment of extracranial and, in select cases, intracranial arterial abnormalities, including carotid and vertebral stenosis and dissection (22), and as a scaffold for coil embolization of fusiform aneurysms (8). Stent placement in the venous system is less prevalent because of the risk of long-term thrombosis, considering the thrombogenicity of a foreign body in a non-anticoagulated patient. Intravascular stenting in the venous system has been limited to cases of dialysis fistula stenosis (15), axillary-subclavian thrombosis (17), and fresh venous thrombus successfully (21). Stent placement in the intracranial venous system has been previously reported in the treatment of stenosis of the transverse sinus but not for treatment of an occluded sinus after recanalization (12).

More recently, a case of traumatic bilateral internal jugular venous thrombo-

sis has been described in which stent placement into the left IJV resulted in significantly decreased intracranial pressure (4). Although we did not directly measure intracranial pressure and did not resort to cerebrospinal fluid diversion for the current patient, previous work has established that increased venous intracranial pressure results in increased intracranial pressure. Although spontaneous thrombosis of the stented segment remains a risk, its continued patency may not only be the result of systemic anticoagulation but also may be because it carries a very high flow rate. High flow and associated shear stress induce increased endogenous release of prostacyclin (7) and nitric oxide (6), both of which decrease platelet activation, and increased production of tissue-type plasminogen activator (3), which may contribute to dissolution of formed clot.

This case illustrates the hypothesized link between venous sinus thrombosis and the resulting venous hypertension and subsequent development of DAVF (13, 14, 18). This patient had presented 15 months before the current admission with a diagnosis of dural sinus thrombosis that was not associated with any dural arteriovenous shunting. Consistent with previous reports (1, 14), it is possible that the venous sinus thrombosis may have led to the downstream development of DAVFs. Alternatively, DAVFs may form as a consequence of venous hypertension alone, perhaps by fostering the growth of arteriovenous shunts found within normal pachymeninges. Induced venous hypertension without thrombosis has been shown to produce DAVFs in rats, perhaps mediated by an angiogenic factor (10, 19, 20). In the case reported herein, thrombosis of dural sinus was present for some time with concomitant systemic anticoagulation before the DAVFs formed, suggesting venous hypertension as a contributing factor. It is possible that the placement of the occipital stent and the documented consequent decreased venous sinus pressure may have also contributed to spontaneous DAVF thrombosis and the decrease in DAVF prominence revealed by the 3-month follow-up angiography (11). It is clear that no new DAVFs formed during this interval.

CONCLUSION

In conclusion, the case presented herein illustrates the value of stent placement in a recanalized and balloon-dilated thrombosed dural sinus after reocclusion as a means of providing a low-resistance outflow pathway for venous hypertension.

Received, August 18, 1998.

Accepted, December 7, 1998.

Reprint requests: Adel M. Malek, M.D., Ph.D., Interventional Radiology, University of California, San Francisco, Box 0628, Room L352, 505 Parnassus Avenue, San Francisco, CA 94143.

REFERENCES

1. Arnautovic KI, Al-Mefty O, Angtuaco E, Phares LJ: Dural arteriovenous malformations of the transverse/sigmoid sinus acquired from dominant sinus occlusion by a tumor: Report of two cases. *Neurosurgery* 42:383-388, 1998.
2. Barnwell SL, Higashida RT, Halbach VV, Dowd CF, Hieshima GB: Direct endovascular thrombolytic therapy for dural sinus thrombosis. *Neurosurgery* 28:135-142, 1991.
3. Diamond SL, Eskin SG, McIntire LV: Fluid flow stimulates tissue plasminogen activator secretion by cultured human endothelial cells. *Science* 243:1483-1485, 1989.
4. Duke BJ, Ryu RK, Brega KE, Coldwell DM: Traumatic bilateral jugular vein thrombosis: Case report and review of the literature. *Neurosurgery* 41:680-683, 1997.
5. Einhaupl KM, Villringer A, Meister W, Mehraein S, Garner C, Pellkofer M, Haberl RL, Pfister HW, Schmiedek P: Heparin treatment in sinus venous thrombosis. *Lancet* 338:597-600, 1991.
6. Faraci FM, Brian JE Jr: Nitric oxide and the cerebral circulation. *Stroke* 25:692-703, 1994.
7. Frangos JA, Eskin SG, McIntire LV, Ives CL: Flow effects on prostacyclin production by cultured human endothelial cells. *Science* 227:1477-1479, 1985.
8. Higashida RT, Smith W, Gress D, Urwin R, Dowd CF, Balousek PA, Halbach VV: Intravascular stent and endovascular coil placement for a ruptured fusiform aneurysm of the basilar artery: Case report and review of the literature. *J Neurosurg* 87:944-949, 1997.
9. Horowitz M, Purdy P, Unwin H, Carstens G III, Greenlee R, Hise J, Kopitnik T, Batjer H, Rollins N, Samson D: Treatment of dural sinus thrombosis using selective catheterization and urokinase. *Ann Neurol* 38:58-67, 1995.
10. Lawton MT, Jacobowitz R, Spetzler RF: Redefined role of angiogenesis in the pathogenesis of dural arteriovenous malformations. *J Neurosurg* 87:267-274, 1997.
11. Malek AM, Halbach VV, Dowd CF, Higashida RT: Diagnosis and treatment of dural arteriovenous fistulas. *Neuroimaging Clin N Am* 8:445-468, 1998.

12. Marks MP, Dake MD, Steinberg GK, Norbash AM, Lane B: Stent placement for arterial and venous cerebrovascular disease: Preliminary experience *Radiology* 191:441-446, 1994.
13. Mayberg MR, Zimmerman C: Vein of Galen aneurysm associated with dural AVM and straight sinus thrombosis: Case report. *J Neurosurg* 68: 288-291, 1988.
14. Pierot L, Chiras J, Duyckaerts C, Jason M, Martin N: Intracranial dural arteriovenous fistulas and sinus thrombosis: Report of five cases. *J Neuroradiol* 20:9-18, 1993.
15. Quinn SF, Schuman ES, Demlow TA, Standage BA, Ragsdale JW, Green GS, Sheley RC: Percutaneous transluminal angioplasty versus endovascular stent placement in the treatment of venous stenoses in patients undergoing hemodialysis: Intermediate results. *J Vasc Interv Radiol* 6:851-855, 1995.
16. Rael JR, Orrison WW Jr, Baldwin N, Sell J: Direct thrombolysis of superior sagittal sinus thrombosis with coexisting intracranial hemorrhage. *AJNR Am J Neuroradiol* 18:1238-1242, 1997.
17. Rutherford RB: Primary subclavian-axillary vein thrombosis: The relative roles of thrombolysis, percutaneous angioplasty, stents, and surgery. *Semin Vasc Surg* 11:91-95, 1998.
18. Smith TP, Higashida RT, Barnwell SL, Halbach VV, Dowd CF, Fraser KW, Teitelbaum GP, Hieshima GB: Treatment of dural sinus thrombosis by urokinase infusion. *AJNR Am J Neuroradiol* 15:801-807, 1994.
19. Terada T, Higashida RT, Halbach VV, Dowd CF, Tsuura M, Komai N, Wilson CB, Hieshima GB: Development of acquired arteriovenous fistulas in rats due to venous hypertension. *J Neurosurg* 80:884-889, 1994.
20. Terada T, Tsuura M, Komai N, Higashida RT, Halbach VV, Dowd CF, Wilson CB, Hieshima GB: The role of angiogenic factor bFGF in the development of dural AVFs. *Acta Neurochir (Wien)* 138:877-883, 1996.
21. Vorwerk D, Guenther RW, Schurmann K: Stent placement on fresh venous thrombosis. *Cardiovasc Intervent Radiol* 20:359-363, 1997.
22. Wholey MH, Wholey M, Bergeron P, Diethrich EB, Henry M, Laborde JC, Mathias K, Myla S, Roubin GS, Shawl F, Theron JG, Yadav JS, Dorros G, Guimaraens J, Higashida R, Kumar V, Leon M, Lim M, Londero H, Mesa J, Ramee S, Rodriguez A, Rosenfield K, Teitelbaum G, Vozzi C: Current global status of carotid artery stent placement. *Cathet Cardiovasc Diagn* 44: 1-6, 1998.

COMMENTS

Malek et al. describe a case of a 13-year-old patient with a history of chronic sinus thrombosis refractory to anticoagulant therapy with associated focal neurological deficits related to venous hypertension. The authors present their management of an extremely difficult case with an excellent outcome. In addition, this further emphasizes and illustrates the presence of chronic venous hyper-

pertension as a cause of focal neurological deficits. Reduction of pressure from 41 to 14 mm Hg after recanalization is further objective evidence of the cause of this problem. This case also illustrates that, contrary to popular thought, stents can be deployed in areas of low flow on the venous side, although I suspect that as the number of cases increase, the incidence of stent thrombosis might be higher. That being the case, such antiplatelet agents as Reopro may be advantageous. As technology improves, application of endovascular techniques to intracranial and venous disease will become more commonplace, and these authors introduce it for disease on the venous side.

Robert H. Rosenwasser
Philadelphia, Pennsylvania

This article shows an innovative approach to dural sinus thrombosis. Placement of a stent in this setting was probably the only way patency of the sinus could be maintained. This case has all the elements of disease affecting the dural sinuses, and the authors present their excellent management and documentation.

Stanley L. Barnwell
Portland, Oregon

The authors present a technical case report of a 13-year-old patient with a history of chronic sinus thrombosis refractory to anticoagulant therapy with the acute onset of aphasia and hemiparesis. The patient had a transverse sinus dural arteriovenous fistula, which was embolized with transvenous and transarterial approaches. A subtotal embolization was achieved, and cortical venous drainage and venous hypertension remained. It was therefore necessary to recanalize through angioplasty of the dural sinus drainage involving the occipital sinus, torcula, and left transverse sinus. The patient improved clinically within 12 hours, and angiographically, the cortical venous drainage resolved. However, within 3 days, neurological symptoms returned and repeat angiography revealed reocclusion of the previously recanalized occipital sinus and right transverse sinus with return of cortical venous drainage. The authors, at that time, redilated the

above mentioned venous pathways and placed a WallStent (Schneider Inc., Minneapolis, MN) in the recanalized occipital sinus. The patient remained without neurological symptoms or deficits at the 1-year clinical and neurological follow-up examinations.

In summary, this report illustrates the value of stent placement in a thrombosed dural sinus as a means of providing a low resistance outflow pathway for venous hypertension. Indications for stent placement were justified in this patient for whom more traditional and conservative therapy had failed. The authors used a logical and systematic treatment approach that resulted in an almost immediate reduction of venous hypertension. In addition, the authors present an interesting discussion of the uses of angioplasty and stenting of the dural sinuses.

In our experience with two patients with dural sinus stenoses with and without thrombosis, the stented sinuses either rapidly restenosed or occluded. The authors' enthusiasm for this technique should be tempered by the knowledge that stented veins (in body interventional cases) have very rapidly restenosed. Perhaps in the future, some technique such as intraluminal brachytherapy may help to reduce these postvenous-stenting restenoses.

As a technical note, we have found the flexibility and trackability of the 7-French sheath (Arrow International, Inc., Reading, PA) to be slightly superior to the 9-French guide catheter (Cordis Endovascular) used by the authors in this report. This sheath may be obtained in up to a 90-cm length and without a proximal hemostatic valve, enabling the interventionalist to pass other devices, such as WallStent delivery systems, coaxially or the use of diagnostic catheters and microcatheters for an effective triaxial system. We have found this device to be extremely useful for carotid stenting, as well as for guide catheter access to the jugular venous system.

Donald W. Larsen
George P. Teitelbaum
Interventional Neuroradiologists
Los Angeles, California