

SHORT REPORT

Unidirectional dyslexia in a polyglot

R R Leker, I Biran

Abstract

Alexia is usually seen after ischaemic insults to the dominant parietal lobe. A patient is described with a particular alexia to reading Hebrew (right to left), whereas no alexia was noted when reading in English. This deficit evolved after a hypertensive right occipitoparietal intracerebral haemorrhage, and resolved gradually over the ensuing year as the haematoma was resorbed. The deficit suggests the existence of a separate, language associated, neuronal network within the right hemisphere important to different language reading modes.

(J Neurol Neurosurg Psychiatry 1999;66:517-519)

Keywords: neglect; dyslexia; alexia without agraphia; intracranial haematoma

Alexia without agraphia may follow lesions to the dominant occipital lobe and the posterior part of the corpus callosum as well as lesions that undercut the dominant angular gyrus. It may or may not be associated with visual field defects as well as other deficits such as colour anomia. With the exception of neglect dyslexia, right hemispheric lesions are not commonly associated with alexia, as the action of reading involves neuronal networks in the language systems of the dominant hemisphere. Alternate networks for reading may exist in the right hemisphere.¹ These networks may have important implications while reading material in different modes and languages (right to left as in Hebrew or Arabic versus left to right as in English). We present a patient with unidirectional right to left dyslexia.

Case report

A 73 year old right handed hypertensive man, a professor of art and design in university and fluent in Hebrew and English, presented with headache and left homonymous hemianopsia that began on the night of his admission while having sexual intercourse. His mother tongue was Hebrew and he acquired his English language proficiencies throughout elementary and high school as well as university tuition. His hypertension was medically controlled with 50 mg atenolol /day, and his medical history was otherwise unremarkable. On admission he was afebrile, his blood pressure was 160/100, his pulse was 88 and regular, and the

general examination was unremarkable. On neurological examination he was noted to have left homonymous hemianopia without motor signs. There was no evidence for simultanagnosia or Balint syndrome. No neglect was seen on repeated line bisection tests (13 lines in sizes of 2.7 cm to 15.7 cm, mean 7.3 cm, median 6 cm, mean error 1.08 (SD 3.60) mm with the smaller fraction being on the right). No neglect was found on repeated star cancellation tests (no omissions found on the standard cancellation form of the Florida battery), as well as on repeated (n=10 in each category) tests of bilateral simultaneous stimuli for visual (finger pointing), tactile, and auditory modalities. He complained of abstract, coloured, formed, visual hallucinations in the hemianopic field with palinopsia but no polyopia, micropsia, or macropsia and no auditory or sensory component. Fluttering of objects in the visual focus was noted and the patient could not focus his vision. On repeated trials (n=3) he complained of being unable to read simple words or paragraphs from a daily newspaper in Hebrew, both aloud and silently, whereas he noted no such difficulty while reading in English (all written material in Hebrew was tested on square, unpointed text). Comprehension for reading was also impaired in Hebrew whereas it was normal in English. A fluttering motion of the rightmost letters of every word (both in separate words and in text) was noted when trying to read in Hebrew. This motion prevented him from focusing and reading and persisted when trying to read Hebrew letters from left to right, as well as when looking at pictures not containing linguistic information. To read in Hebrew the patient would turn the page 90° and read vertically. When forced to read in a horizontal plane the patient made literal paraphasic mistakes as he tried to substitute for the letters he could not read. No letter agnosia was present, as he could read Hebrew letters from left to right. He had problems in reading Hebrew both letter by letter and word by word. Writing in both Hebrew and English, spontaneously and to dictation, was normal, as was copying of geometric forms on several trials. All other language variables were normal. A mini mental examination and a more elaborate battery of tests gave normal results, except for reading and comprehension difficulties when reading in Hebrew.

A laboratory screen that included erythrocyte sedimentation rate, complete blood count,

**Department of
Neurology, Hebrew
University-Hadassah
Medical School,
Jerusalem, Israel**
R R Leker
I Biran

Correspondence to:
Dr R R Leker, Department
of Neurology, Hadassah
University Hospital, POB
12000, Jerusalem 91120,
Israel. Telephone 00972 2
6776941; fax 00972 2
6437782; email
leker@cc.huji.ac.il

Received 7 April 1998 and in
final form
20 October 1998
Accepted 3 November 1998

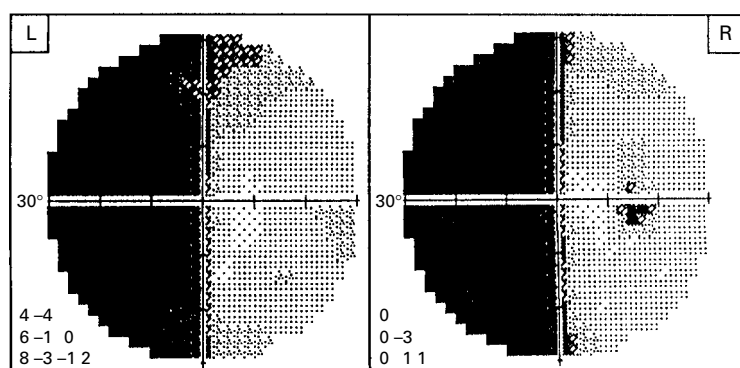


Figure 1 Visual fields obtained 2 days after admission, showing left homonymous hemianopia.

and routine chemistry was normal. Computerised visual field examination showed congruent left homonymous hemianopia with macular splitting (fig 1). Non-enhanced CT (fig 2A) of the brain showed a right occipital haematoma involving the superior and middle occipital gyri, extending into the right occipital horn but not to the splenium. An EEG was normal. The patient was treated conservatively and the dose of atenolol was set at 100 mg/day. A follow up CT showed resolution of the haematoma and a brain MRI study showed the resolution of the haematoma and evidence for subcortical ischaemic disease without evidence of underlying malignancy (fig 2B).

On follow up evaluation 18 months after the ictus he still had minor deficits when reading Hebrew. When given repeated trials of reading meaningful and nonsense words in Hebrew, at different orientations (n=20 in each category, right to left, left to right, or vertical) he made two mistakes when reading in a horizontal plane from right to left, whereas no mistakes were made in all other directions and planes. When given parallel tests in English or Yiddish he made no mistakes at all. The previously found visual field defect returned to normal.

Discussion

Our patient showed an alexia with an unusual feature of not being able to read from right to left, whereas he was able to read from left to right. This type of unidirectional alexia without agraphia has not been described before. Although evidence for subcortical vascular disease was seen on the MRI, no infarcts involving the language areas of the left hemisphere were seen. Therefore, prior cerebral ischaemia does not seem to explain the findings noted in our patient. The closest descriptions we were able to find resembling our patient are those of hemiparalexia and neglect dyslexia. The first implicates the splenium,² which was not involved in our patient, and manifests in reading difficulties in half of the visual field. The phenomena described by our patient was different as he mainly complained of a fluttering motion in the visual field that rendered reading impossible only when reading Hebrew. Patients with neglect dyslexia described earlier³⁻⁶ usually had right parietal lesions and could not read the beginning of words when reading from left to right (English). Although similar to the described patient in not being able to read the first few letters of a word, all those patients except one⁵ were shown to have left sided neglect, which was not present in our patient. Two possible explanations have been proposed for neglect dyslexia. The first states that a primary visual data acquisition process is faulty in these patients⁷ and the second states that the flaw lies within the central multimodal, word processing neuronal network.^{5,8} Most English words carry the bulk of their meaning in the first and second thirds of their letter string but whether the same is true for Hebrew words is unknown.⁹ Thus, the fluttering in the right hemifield may have been responsible for his inability to read the all important first letters string and to comprehend Hebrew words. This and the fact that the patient managed to read Hebrew by turning the page 90° supports at least in part the primary visual field

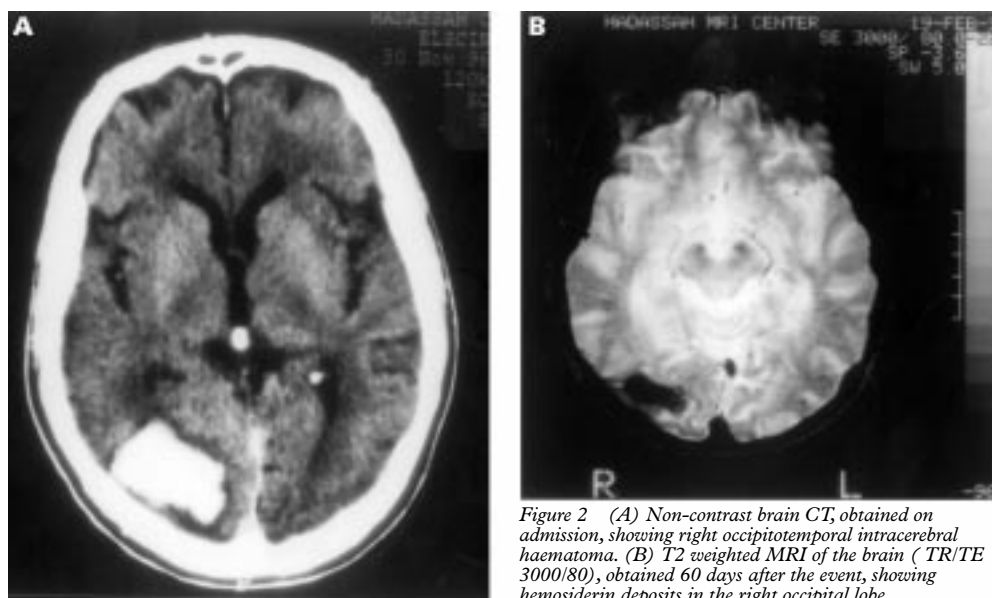


Figure 2 (A) Non-contrast brain CT, obtained on admission, showing right occipitotemporal intracerebral haematoma. (B) T2 weighted MRI of the brain (TR/TE 3000/80), obtained 60 days after the event, showing hemosiderin deposits in the right occipital lobe.

theory. Yet the data obtained in the present case might also support the role of a central integrative lesion in causing neglect dyslexia, as visual neglect, which is suggestive for the peripheral data acquisition flaw theory, was absent. Thus the patient did not complain of inability to read the left side of words which could have been caused by the left homonymous hemianopia, but rather complained of inability to read the right side of words and non-verbal material. He probably managed reading English by moving his eyes so that words fell in his intact right visual field. The return of his lexical abilities to normal while the MRI still showed the resolving occipital haematoma also supports the presence of a more anterior, temporo-occipital integrative network, which was probably the site of the lesion causing his lexical defect. Moreover, it is interesting to note that previous reports⁴⁻⁶ speculated that in Hebrew or Arabic speaking people with right sided lesions the dyslexia will manifest as a difficulty in reading the end of the words, whereas our patient had difficulties with the beginning of words. This case, therefore, shows a special variety of neglect dyslexia, which should be called "directional alexia". The role of the right hemisphere in reading is not clear. Some investigators suggest that it is responsible for graphemic representation of words, which probably plays an important part in reading Hebrew in its various forms.¹ The present case indeed supports the notion that the right hemisphere has a role in reading Hebrew, as our patient's lesion involved that hemisphere.

Our case also provides important information regarding spatial orientation in reading. It has been suggested that when showing rotated words to subjects there is a mental rectifying process, which turns the word to its normal, horizontal array before full analysis can be done. Our patient's inability to read horizontally, and preserved capability to read in vertical orientation stands against such a theory.¹⁰

The cause of the visual hallucinations present in this case probably represent the effects of disconnection of primary and secondary visual association fibre systems, as no evidence for seizure activity was found clinically or on EEG, and the complaints were constantly present and sustained.

The cause of the haemorrhage in our patient was probably hypertensive given his medical history, although other causes for cerebral haemorrhage such as amyloid angiopathy have not been specifically looked for. It would have been interesting to speculate about the possible relation between amyloid angiopathy and brain amyloid depositions leading to cognitive changes (comprehension difficulties) present in our patient. However, the acute onset of the reading disability, the absence of cognitive decline on the mini mental test and on a wider variety of tests, as well as the return of our patient to his previous position as faculty member mitigates against the possibility of an early dementing process being responsible for the reading and comprehension abnormalities exemplified by our patient.

We think that the unique findings in this patient imply, although they do not prove, that the right hemisphere does play a part in reading ability, and that this part may have special relevance to different spatial patterns used while reading. Thus, while using a pattern for reading from right to left (for example, Hebrew), different neuronal networks responsible for the direction of reading may come into play. We suggest that these networks involve the right occipital lobe or in its connections and that lesions of these systems can cause directional dyslexia. Further case studies are needed to evaluate this phenomenon.

This work was supported in part by the Sol Irwin Juni Endowment Fund.

- 1 Koriat A. Lateralization effects in reading pointed and unpointed Hebrew. *Br J Psychol* 1985;76:161-73.
- 2 Binder J, Lazar R, Tatemichi T, et al. Left hemiparalexia. *Neurology* 1992;42:562-9.
- 3 Behrmann M, Moscovitch M, Black SE, et al. Perceptual and conceptual mechanisms in neglect dyslexia. Two contrasting case studies. *Brain* 1990;113:1163-83.
- 4 Kinsbourne M, Warrington E. A variety of reading disability associated with right hemisphere lesions. *J Neurol Neurosurg Psychiatry* 1962;25:339-44.
- 5 Costello AD, Warrington EK. The dissociation of visuospatial neglect and neglect dyslexia. *J Neurol Neurosurg Psychiatry* 1987;50:1110-6.
- 6 Ellis AW, Flude BM, Young AW. Neglect dyslexia and the early visual processing of letters in words and non words. *Cognitive Neuropsychology* 1987;4:439-64.
- 7 Warrington E, Zangwill OL. A study of dyslexia. *J Neurol Neurosurg Psychiatry* 1957;20:208-15.
- 8 Caramazza A, Hillis AE. Levels of representation, coordinate frames and unilateral neglect. *Cognitive Neuropsychology* 1990;7:391-445.
- 9 Berent I, Shimron J. The representation of Hebrew words: evidence from the obligatory contour principle. *Cognition* 1997;64:39-72.
- 10 Koriat A, Norman J. Reading rotated words. *J Exp Psychol Hum Percept Perform* 1985;11:490-508.