

Trihexyphenidyl in Posthemorrhagic Dystonia: Motor and Language Effects

Frank S. Pidcock, MD*,
Alexander H. Hoon, Jr, MD, MPH[†], and
Michael V. Johnston, MD[‡]

Trihexyphenidyl has been found to be an effective treatment for dystonic movement disorders, improving gross motor function in patients with axial and torsional dystonia, tremors, and myoclonus. In this report, improvements in fine motor control, language, and oral motor skills are described with trihexyphenidyl in an 8-year-old female who developed dystonia after spontaneous bilateral putamenal hemorrhages. No adverse side effects occurred. The mechanism of action of trihexyphenidyl is believed to be in the basal ganglia where it inhibits muscarinic cholinergic receptors and increases the turnover of dopamine. © 1999 by Elsevier Science Inc. All rights reserved.

Pidcock FS, Hoon, Jr, AH, Johnston MV. Trihexyphenidyl in posthemorrhagic dystonia: Motor and language effects. *Pediatr Neurol* 1999;20:219-222.

Introduction

Dystonia has been defined as involuntary sustained or twisting movements of the extremities and may be caused by a number of genetic or acquired disorders [1]. Trihexyphenidyl, an inhibitor of muscarinic cholinergic receptors, has been used to improve acute dystonia induced by antipsychotic drugs, as well as dystonia from other disorders [2,3]. The effects of trihexyphenidyl have predominately been reported in regard to reducing dystonic tone in the extremities or trunk. In the patient reported here, dramatic changes in fine motor, oral motor, and language

skills were seen in addition to an improvement of gross motor tone.

The treatment of dystonia is characterized by variable response and frequent failure of medications, including anticholinergics, baclofen, benzodiazepines, carbamez-epine, levadopa, and antidopaminergics [2]. In 1983, Fahn [2] reported a beneficial response to trihexyphenidyl in 14 of 23 children with generalized dystonic syndromes, including inherited disorders, birth injuries, and idiopathic causes. The three patients in whom dystonic was secondary to head trauma or infection did not respond to trihexyphenidyl [2]. In cases of delayed-onset dystonia related to perinatal or early childhood asphyxia, Saint Hilaire et al. [4] reported a beneficial response to trihexyphenidyl in six of seven children. Jabbari et al. [5] reported significant improvement in a patient with post-traumatic segmental axial dystonia and progressive scoliosis. Conversely, a lack of response to trihexyphenidyl was seen by Nardocci et al. [6] in five cases of acquired hemidystonia [6]. Trihexyphenidyl was not as effective as botulinum toxin in treating cervical dystonia [7].

Trihexyphenidyl has also been used to treat extrapyramidal side effects of medication for schizophrenia [8]. When used in patients with early Parkinson's disease, it has been demonstrated to improve results on tests of frontal lobe function [9]. However, in one patient the onset of orobuccal dyskinesia was associated with trihexyphenidyl therapy [10]. Beneficial effects of trihexyphenidyl have also been reported in cases of subacute sclerosing panencephalitis, ataxia telangiectasia, and Meige's syndrome [11-13].

Case Report

A previously healthy 8-year-old right-handed female presented with acute onset of headache, dizziness, and leg weakness. She became progressively less responsive and was comatose on arrival at a hospital. There was no antecedent history of fever, rash, or gastrointestinal or urinary signs. Her initial blood pressure was 140/100 mm Hg. The blood cell count, electrolytes, serum urea nitrogen, and liver function tests were unremarkable. A cerebrospinal fluid analysis was normal with a protein of 34 mg/dL.

An initial cranial computed tomography study revealed increased attenuation in the basal ganglia and corona radiata. A brain magnetic resonance imaging study obtained 5 days later revealed putamenal hemorrhage, with cystic changes bilaterally, and evidence of white matter injury (Fig 1). A repeated study 14 days later revealed changes in T₁- and T₂-weighted signals consistent with early subacute hemorrhage.

Magnetic resonance arteriograms and venograms revealed normal

From the Departments of *Physical Medicine and Rehabilitation and Pediatrics; [†]Pediatrics; and [‡]Neurology and Pediatrics; Johns Hopkins University School of Medicine and Kennedy Krieger Institute; Baltimore, Maryland.

Communications should be addressed to:
Dr. Pidcock; Kennedy Krieger Institute; 707 North Broadway;
Baltimore, MD 21205.

Received June 2, 1998; accepted October 2, 1998.

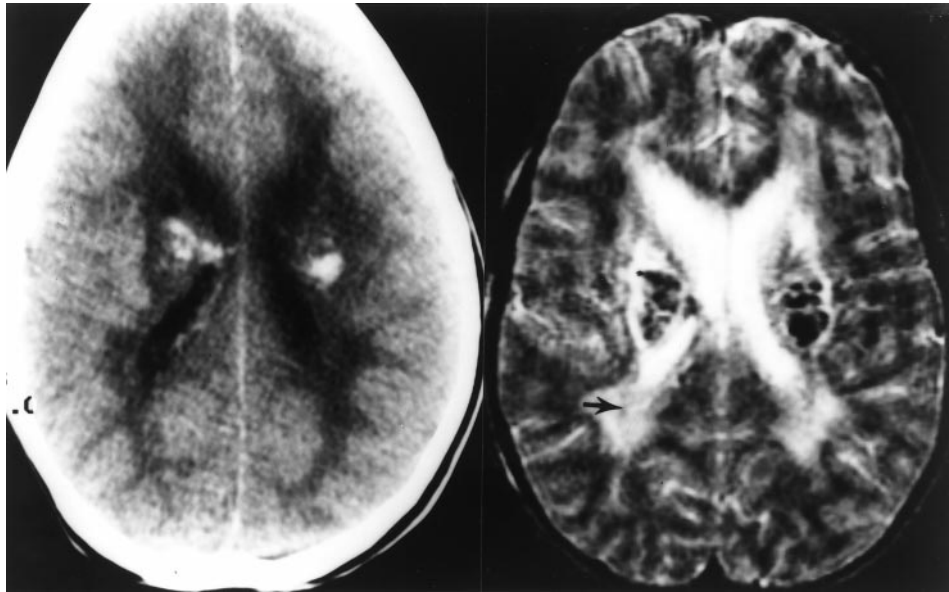


Figure 1. Axial computed tomography image of the brain demonstrates increased bilateral attenuation in the basal ganglia and corona radiata. An axial T₂-weighted magnetic resonance image (TR = 3,000 ms, TE = 120 ms) 5 days later reveals putamenal hemorrhage, with cystic changes bilaterally, and hyperintense signal in the white matter (arrow).

cerebral vessels. An echocardiogram was normal. Hematologic studies revealed a mild factor VII deficiency, which was not thought to be related to the putamenal hemorrhages, and normal platelet function. Cerebrospinal fluid studies for herpes simplex virus, Lyme titers, and lactate were normal. Ammonia level was normal and lactate immunoassay screen was negative. Urine for organic acids, amino acids, and toxicologic findings was negative. Ceruloplasmin and urine copper studies were normal. Peroxisomal assays, carnitine assays, and mitochondrial assays were all within normal limits. Cardiolipin panel, antinuclear antibodies, and antimitochondrial antibodies were negative.

The patient was able to open her eyes 6 days after the initial event and recognized her parents 8 days later. At the time of transfer to a rehabilitation facility 1 month after the initial event, she was able to interact by smiling and by using eye movements to locate family members. Muscle tone consisted of both dystonia and spasticity. Minimal spontaneous movements were present, and she remained avocal.

When she was discharged home 49 days later, she was alert and could smile and visually fixate. She could answer "yes" and "no" questions with eyelid movements. Dystonia interfered with gross motor and fine motor use of her upper extremities. Her left hand was open with no control of finger movements. Her right hand was fisted with a tonically flexed right wrist. Sustained bilateral clonus, brisk deep tendon reflexes, and extensor posturing interfered with isolated movements in the legs. Transfers required maximal assistance and used the extensor tone for facilitation. Trunk tone was low, and maximal assistance was needed for sitting. Oral musculature demonstrated an incoordinated pattern with a persistent tongue thrust and dysphagia. Drooling was present, and crying was her only consistent vocalization.

Seven months after the initial event the patient was evaluated for the management of dystonia. No fixed contractures at hips, knees, wrists, elbows, or fingers were evident. The ankles were plantar flexed and difficult to position in neutral. The left arm could be moved in space, with poor control, and the left hand could be opened and closed. Movement of the right arm was limited, and the right hand was held in a fisted and flexed position. Independent sitting was not possible because of poor trunk control and inability to access automatic postural control reactions. There was a paucity of facial movements and no speech.

Trihexyphenidyl was initiated at a dose of 1 mg twice daily and gradually increased as tolerated. At 3 mg daily, her parents reported a decrease in muscle stiffness; however, blurry vision occurred. The dose

was decreased, with a return of increased tone. An eye examination excluded the presence of glaucoma, and dose increases were resumed.

Three months later, receiving 4 mg in the morning and 3 mg in the evening, her ability to draw improved dramatically. A chronology of her pictures is presented in Figure 2. Oral abilities also improved, and the amount of tube feedings was decreased. Drooling decreased significantly. There was less torsion of the right foot and easier positioning of the left foot on the foot plate of her wheelchair. Control of leg movements was becoming possible, with suppression of automatic reflexes. Both knees could be moved simultaneously to kick a ball with the therapists.

With a dosage of 4 mg in the morning, 2 mg in the afternoon, and 2 mg in the evening, her mother reported greatly improved oral motor control and coordination of tongue movements. Improved chewing and vocalizations occurred, with the production of an occasional "no." The variety of facial expressions increased. She began using crayons for drawing and began to print. Access to a communication board improved, and she was able to use a stylus for more accurate choices. Her sitting posture improved, with momentary independent sitting occurring. Isolated movements of the lower extremities occurred, which allowed her to pedal a tricycle and to start ambulation training.

By 11 months, she was tolerating 5 mg in the morning, 5 mg in the afternoon, and 4 mg at night. Drooling was decreased and language production improved. With the help of speech therapy, she was beginning to vocalize consonant-vowel combinations and beginning to form an "o" with her mouth. She was able to use her left finger to access her communication board in a rapid and controlled manner. Trunk and pelvic tone was decreased, allowing more comfortable positioning in her wheelchair. At this point the therapeutic effects of trihexyphenidyl were believed to have plateaued, and she has been maintained on this dose with stable benefits, as previously described.

Discussion

This patient presented with an acute deterioration of consciousness progressing to coma, with neuroradiologic findings in the putamina and cortical white matter. Hemolytic uremic syndrome and acute hemorrhagic leukoencephalopathy were excluded on the basis of the diag-




Figure 2. Sequence of drawings before and after trihexyphenidyl was initiated. The daily dose of trihexyphenidyl is indicated on each drawing: (A) dog, (B) elephant, (C) clown, and (D) self-portrait.

nostic evaluation. The absence of exanthem, fever, leukocytosis, or increased cerebrospinal fluid protein make an infectious or parainfectious etiology unlikely [14,15]. Although extensive testing for recognized genetic-metabolic disorders, including mitochondrial encephalopathies, was negative, it is still possible that this patient had an unclassified disorder involving mitochondrial function [16, 17].

Persistent disabling dystonia, drooling, and aphasia after recovery from the acute encephalopathy was present with little improvement 7 months after the initial event. Trihexyphenidyl was then recommended to treat the dystonia, which was interfering with gross motor movements, sitting, and wheelchair positioning. Relaxation of muscle tone was reported after a low dose was started. This improvement was lost when the dose was temporarily reduced because of transient blurry vision.

An increased dose of trihexyphenidyl resulted in significant improvement in fine motor and oral motor control, as well as in a decrease of the dystonia affecting the lower extremities. The improvements in fine motor control are documented through a series of drawings. Coincident with these changes, her mother reported a significant decrease in drooling and an increase in language production. Gross motor control also improved and eventually progressed to independent sitting, weight bearing in standing, and the initiation of gait training.

In almost all cases that report the benefits of trihexyphenidyl the decrease in dystonia and resulting improvement in gross motor control is emphasized, including the treatment of parkinsonism, Meige's syndrome, ataxia-telangiectasia, subacute sclerosing panencephalitis, and acquired hemidystonia [6,10-13]. Improvement in fine motor skills and speech have been much less commonly reported.

Vogels et al. [18] described a 9-year-old female who had a thalamic infarction of perinatal origin and borderline cognitive function who demonstrated improvement in focal dystonia and speech after anticholinergic treatment. In another patient, Nicaretta et al. [19] reported improvement in a writing tremor with trihexyphenidyl that had not responded to either propranolol or primidone.

Trihexyphenidyl, a muscarinic acetylcholine antagonist, increases dopamine turnover in the basal ganglia, which may antagonize the dystonic speech musculature resulting from the putamen injury. In primates the posterior lateral putamen has been linked to a somatotopic representation for upper extremity function and speech [20]. In humans, lesions in this area have produced spasmodic dysphonia [21]. These areas influence tone and posture through the modulation of thalamic excitatory feedback to the motor cortex. The functional improvements in hand use and speech for the child in the present report may be related to this close anatomic relationship of motor and speech function in the putamen.

Trihexyphenidyl is well tolerated in children, especially if started at a low dose and then gradually increased. The dosage should be initiated at 1 or 2 mg daily and then increased by 2- to 3-mg intervals to the desired effect or intolerance because of side effects. High-dose therapy of up to 35 or 40 mg daily has been reported. Adverse effects include blurred vision, dry mouth, and urinary difficulties. On a central basis, side effects also include forgetfulness, weight loss, personality changes, and sleep disturbances [2].

This case report describes improvements in fine motor, oral motor, and language skills associated with trihexyphenidyl after idiopathic putamenal hemorrhage and necrosis. It is one of only a few documented cases that report

beneficial changes in these areas in addition to a reduction in dystonia. Because of the prolonged interval between injury and initiation of medication, it is believed by the authors that these improvements represent an effect of the medication on central pathways rather than spontaneous recovery. By interfering with the antidopaminergic effects of acetylcholine in the basal ganglia, trihexyphenidyl may facilitate the return of important functions of daily living.

References

[1] **Fahn S.** Concept and classification of dystonia. In: Fahn S, Marsden CD, Calne DB, eds. *Dystonia 2. Advances in neurology*, Vol. 50. New York: Raven Press, 1988:1-8.

[2] **Fahn S.** High dosage anticholinergic therapy in dystonia. *Neurology* 1983;33:1255-61.

[3] **Ayd FJ.** A survey of drug-induced extrapyramidal reactions. *JAMA* 1961;175:1054-60.

[4] **Saint Hilaire M-H, Burke RE, Bressman SB, Brin MF, Fahn S.** Delayed-onset dystonia due to perinatal or early childhood asphyxia. *Neurology* 1991;41:216-22.

[5] **Jabbari B, Paul J, Scherokman B, Van Dam B.** Post-traumatic segmental axial dystonia. *Mov Disord* 1992;7:78-81.

[6] **Nardocci N, Zorzi G, Grisoli M, Rumi V, Broggi G, Angelini L.** Acquired hemidystonia in childhood: A clinical and neuroradiological study of thirteen patients. *Pediatr Neurol* 1996;15:108-13.

[7] **Brans JW, Lindeboom R, Snoek JW, et al.** Botulinum toxin versus trihexyphenidyl in cervical dystonia: A prospective, randomized, double-blind controlled trial. *Neurology* 1996;46:1066-72.

[8] **Chen Y.** A double-blind study on the effect of dextimide in the control of neuroleptic-induced extrapyramidal side-effects. *Chung-Hua Shen Ching Ching Shen Ko Tsa Chih* 1991;24:197-9.

[9] **Schelosky L, Benke T, Poewe WH.** Effect of treatment with

trihexyphenidyl on cognitive function in early Parkinson's disease. *J Neural Transm Suppl* 1991;33:125-32.

[10] **Hauser RA, Olanow CW.** Orobuccal dyskinesia associated with trihexyphenidyl therapy in a patient with Parkinson's disease. *Mov Disord* 1993;8:512-4.

[11] **Nunes ML, daCosta JC, daSilva LF.** Trihexyphenidyl and isoprinosine in the treatment of subacute sclerosing panencephalitis. *Pediatr Neurol* 1995;13:153-6.

[12] **Koopp M, Schelosky L, Cordes I, Cordes M, Poewe W.** Dystonia in ataxia telangiectasia: Report of a case with putaminal lesions and decreased striatal iodobenzamide binding. *Mov Disord* 1994;9:455-9.

[13] **Kammitsukasa I, Yamada T, Tokumaru Y, Hirayama K.** Clinical features and factors related to the functional prognosis in Meige's syndrome. *Rinsho Shinkeigaku* 1995;35:231-6.

[14] **Rosemberg S, Amaral LC, Kliemann SE, Arita FN.** Acute encephalopathy with bilateral striatal necrosis: A distinctive clinicopathological condition. *Neuropediatrics* 1992;23:310-5.

[15] **Menkes JH.** Autoimmune and postinfectious diseases. In: Menkes JH, ed. *Textbook of child neurology*. Philadelphia: Lea & Febiger, 1985:440-7.

[16] **De Meirleir L, Seneca S, Lissens W, Schoentjes E, Desprechins B.** Bilateral striatal necrosis with a novel point mutation in the mitochondrial ATPase 6 gene. *Pediatr Neurol* 1995;13:242-6.

[17] **Roig M, Calopa M, Rovira A, Macaya A, Riudor E, Losado M.** Bilateral striatal lesions in childhood. *Pediatr Neurol* 1993;9:349-58.

[18] **Vogels OJM, Maassen B, Rotteveel JJ, Merx JL.** Focal dystonia and speech impairment responding to anticholinergic therapy. *Pediatr Neurol* 1994;11:346-8.

[19] **Nicaretta DH, Pereira JS, Pimentel ML.** Writing tremor: Report of a case. *Arq Neuropsiquiatr* 1994;52:87-9.

[20] **Garrett EA, Crutcher MD.** Functional architecture of basal ganglia circuits: Neural substrates of parallel processing. *Trends Neurosci* 1990;13:266-71.

[21] **Lee MS, Lee SB, Kim WC.** Spasmodic dysphonia associated with left ventrolateral putaminal lesion. *Neurology* 1996;47:827-8.