

SEVERAL neurophysiological studies have highlighted the role of the midbrain periaqueductal gray matter (PAG) in the initiation of vocalization in various animal species, from frogs to primates. With regard to humans, only two cases of complete mutism following a lesion to the PAG have been reported so far. This article describes a new case of a patient (GM) who, following an ischemic lesion to the periaqueductal gray region of the midbrain, presented with complete and irreversible mutism, though her language comprehension functions and her non-verbal expression capacity were preserved. This clinical case provides evidence that in humans the PAG also acts as a link between different vocalization-eliciting external and internal stimuli (which reach the PAG from sensory and emotional structures) and the vocal-motor coordinating mechanisms in the lower brain stem. *NeuroReport* 10:681–685 © 1999 Lippincott Williams & Wilkins.

**Key words:** Emotion; Midbrain; Mutism; Periaqueductal gray; Speech; Vocalization

## Complete mutism after midbrain periaqueductal gray lesion

Antonio Esposito, Guy Demeurisse, Barbara Alberti<sup>1</sup> and Franco Fabbro<sup>1,2,CA</sup>

Service de Revalidation Neurologique, CHU Brugmann, Université Libre de Bruxelles, Brussels, Belgium; <sup>1</sup>Children's Neurological Research Hospital 'E. Medea', Ass. La Nostra Famiglia, Via Don L. Monza, 20, 23842 Bosisio-Parini (LC); <sup>2</sup>Department of Physiology and Pathology, University of Trieste, Italy

CA,<sup>1</sup>Corresponding Author and Address

### Introduction

Lesions in different structures of the nervous system may provoke patterns of transitory or persistent mutism. Lebrun [1] schematically identified five types of mutism: (i) patients with total (or global) aphasia who, by definition, have lost the ability to use language both expressively and receptively. They generally present with hemiplegia or hemiparesis but usually respond adequately to non-verbal stimulation. (ii) Patients with apallism who look awake but do not show awareness of their environment. They do not speak and do not follow verbal instructions but they may move or shout or moan spontaneously. This condition is believed to be due to a complete disconnection of the cerebral cortex, which is responsible for cognitive functions, including speech, from the underlying nervous structures. (iii) Patients with 'locked-in syndrome', who have spastic quadriplegia, and are mute but alert. Usually their comprehension of spoken language is preserved and it is possible to communicate with them by means of eye movements (i.e. upward gaze for 'no' and downward gaze for 'yes'), since they can voluntarily control a few isolated eye movements only. (iv) Patients with transitory mutism following cerebellar damage [2]. (v) Patients with 'akinetic mutism' who do not speak and do not move (or only weakly and after repeated stimulation) but are

aware of their environment and have preserved at least elementary speech comprehension. The lesion responsible for akinetic mutism may lie at various levels between the pons and the frontal lobes. The most frequently involved structures are the midline portions of the midbrain and both gyri cinguli [3,4].

A nervous structure which is of fundamental importance for the initiation of vocalization and speech is the periaqueductal gray (PAG). Electrical stimulation and experimental lesion studies highlighted that this structure is responsible for initiating vocalization in numerous animal species such as frogs, cats and apes. In these species, a lesion to the PAG provokes complete and permanent mutism [5,6]. Experimental neuroanatomical studies in squirrel monkeys have revealed that numerous motivation-controlling brain structures, such as the medio-basal amygdala, the middle thalamus, different hypothalamic areas and the anterior cingulate cortex, have direct projections to the periaqueductal gray and laterally bordering tegmentum. The PAG has direct projections to the reticular formation around the nucleus retroambiguus, a region called periambigular reticular formation. The periambigular reticular formation projects to the trigeminal motor nucleus responsible for jaw control, the facial muscle responsible for lip movements, the nucleus ambiguus controlling the vocal folds, and the thoracic and upper lobar ventral horn containing the expiratory

motoneurons [7]. These neuroanatomical and neurophysiological studies highlighted that the PAG is the phylogenetically oldest structure for the generation of sounds. It seems that the periaqueductal region does not participate in the motor coordination of vocalization itself, but it would couple specific motivations (depending on different internal and external stimuli) with the corresponding vocal expression [7,8]. Numerous neurobiological research studies have shown that the PAG not only is responsible for the initiation of vocalization, but it is also involved in at least four other interactive major functions, namely pain processing, autonomic regulations, fear and anxiety, and sexual behavior components [7].

In humans, only a few cases of mutism following lesions to the periaqueductal gray matter have been described in detail [9]. Steriade *et al.* [10] reported the case of an 11-year-old boy with hemorrhage secondary to an aneurysm of the basilar artery. The clinical findings favoured the existence of a lesion in the higher part of the brainstem. After the coma period, the patient displayed dissociation between complete mutism and the ability to perform movements spontaneously or upon request. He chewed and swallowed normally. The second patient was described by Botez [11]. This 59-year-old patient had suffered two cerebral vascular strokes which left him with right hemiparesis, left abducens oculomotor paresis and mental disturbances. The patient had been completely mute for 5 months. He had not uttered even the slightest mumbling sound (not even in reaction to nociceptive stimuli). Language comprehension was sufficiently preserved because he was capable of performing simple commands correctly. In contrast to this picture of mutism, kinesia was normal. The autopsy revealed a macroscopic lesion in the periaqueductal gray matter. The two cases described by Botez *et al.* [10,11] suggest that in humans the periaqueductal gray matter is also essential for the starting mechanism of speech.

The present article presents another case of complete and permanent mutism following a lesion to the periaqueductal gray matter. So far very few cases describing this mutism pattern have been reported. The more accurate neuro-imaging techniques used in this study allow for a better understanding of the neurofunctional mechanisms of the brainstem involved in the initiation of speech.

## Patient and Methods

*Case report:* G.M. is a 74-year-old right-handed (native French), retired office worker. In December 1994 G.M. suffered a stroke which provoked a right-sided hemisyndrome with consequent Broca's

aphasia. After the first stroke the patient showed a good functional recovery, both at motor and linguistic level. She could live on her own since she was completely self-sufficient. After 10 months (September 1995) G.M. underwent a neurological and neuropsychological examination which revealed a mild paresis of her right hand (1/5) and a slight deficit of the seventh right cranial nerve. When walking she slightly dragged her right leg. Deep reflexes were more pronounced on the right side. No ocular motility or visual discrimination disorders were detected. Cutaneous sensitivity, vibration discrimination and pain sensitivity were preserved. Her neuropsychological recovery was good. The patient showed a good orientation as to time and space. Verbal comprehension and repetition were preserved. Verbal expression was good. A slightly reduced verbal fluency and phonemic paraphasias were the only detectable disorders.

On June 30, 1997 G.M. was found at her home in a comatose state. An investigation revealed that the second stroke had occurred ~2 days before the patient was found. G.M. was admitted to the Brugmann Hospital, Université Libre de Bruxelles. Upon admission she did not open her eyes, nor did she produce any verbal utterance, but she reacted to painful stimuli by trying to avert them with a hand movement. An emergency CT scan showed a hypodense (ischemic) area located in the brain stem (Fig. 1), a hypodense image in the right thalamic region, and an old ischemic area related to the first stroke (December 1994) and affecting the left lenticular nucleus, a part of the head of the caudate nucleus and the left internal capsule. After a few days the patient was transferred from the intensive care department to the neurological rehabilitation department where she stayed until April 1998, when she was transferred to a nursing home. Neurological examination (April 1998) revealed a paralysis of the third bilateral cranial nerve (ptosis, large fixed pupils and divergent strabismus), hypersomnia, mutism and right-sided hemiparesis. The presence of ophthalmoplegia, mutism and hypersomnia indicated a rostral brain stem lesion. The signs of dysfunction of the pupils and of the third nerve clearly indicated a lesion in proximity of the periaqueductal gray region of the midbrain [12–14]. If the patient was left on her own, especially if she was lying in bed, she tended to fall asleep. If she was sitting and her eyes were held open, she was able to interact with the hospital staff using simple forms of non-verbal communication (nodding for 'yes' and 'no', smiling). She showed a prominent facial hypomimia. During the months she spent in the neurological rehabilitation department she exhibited a low level of emotional response, mainly lying in bed or remaining seated.

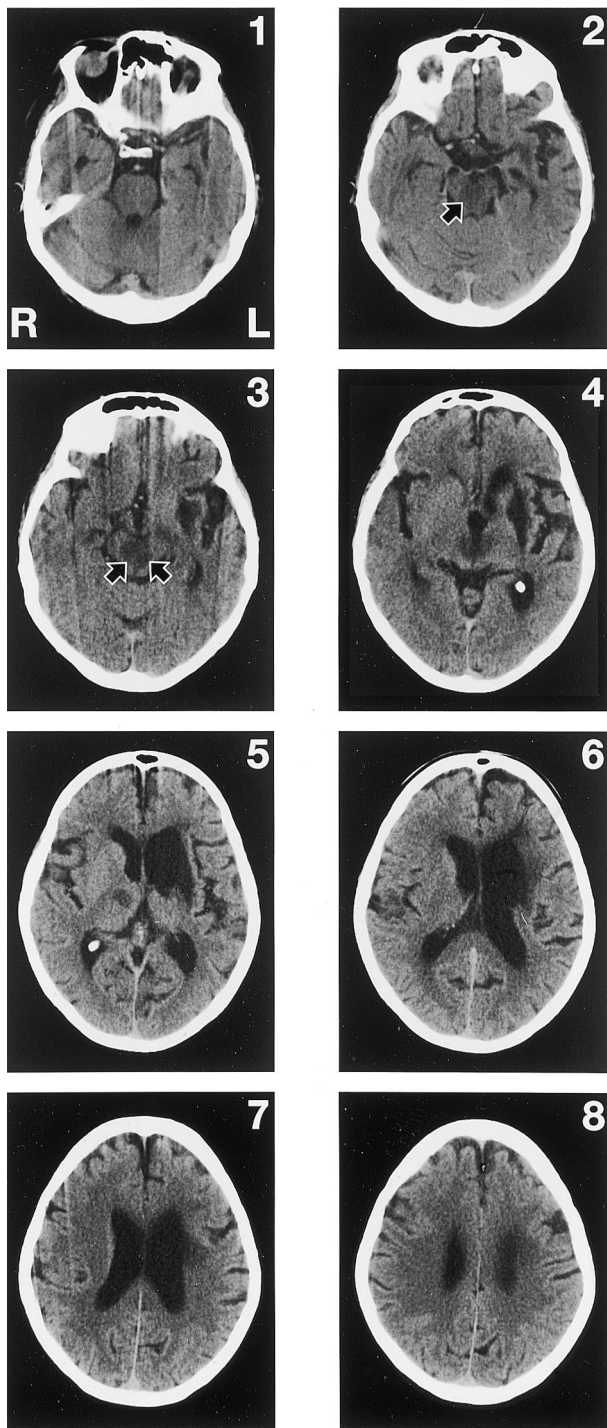


FIG. 1. CT scan without contrast obtained 2 days after G.M. developed a complete mutism with bilateral paralysis of the third bilateral cranial nerve (ptosis, large fixed pupils and divergent strabismus) (June 1997). The number on the upper corner of each scan marks the caudal rostral progression. The CT scan shows a hypodense (ischemic) area located in the brain stem (the midbrain lesion is indicated by black arrows in the 2nd and 3rd slice); a hypodense image in the right thalamic region (5th slice), and; an old ischemic area related to the first stroke (December 1994) affecting the left lenticular nucleus, part of the head of the caudate nucleus and the left internal capsule (3rd–6th slice).

Three months after the second stroke (September 1997) a series of instrumental examinations were carried out to assess the extent of the mesencephalic lesion. The EEG exhibited a regular activity in the frequency range 7–9 Hz in the occipital region. A rich polymorphic theta and delta activity mainly on the left hemisphere was observed. The auditory evoked potentials of the brain stem (BERA) were normal. The blink reflex level was normal, thus showing that no serious disorders had affected the activating reticular formation. A SPECT (performed using [ $^{99m}\text{Tc}$ ]bicisate) highlighted a pathological left frontal and temporal cortical hypoactivity, while the left basal nuclei were not observable.

More than 7 months after the second stroke the clinical condition of the patient remains unchanged. She is not able to sit upright, lies in bed or sits on a couch by means of appropriate support. She is hypersomnic, sleeps most of the day, yet if she has to perform tasks (for example, eat or perform motor and cognitive rehabilitation tasks) and her eyelids are held open, she can stay awake for a few hours. She can swallow liquids and chew food. Her sphincter control is preserved. She exhibits spontaneous movements in her lower limbs and her left arm. Her tactile discrimination and pain sensitivity are preserved. She is oriented as to time and space (she knows she is in a hospital and what year it is), she can recognize her relatives. She is completely mute, does not speak, nor does she produce any type of vocalization, not even in reaction to painful stimuli. Over more than 5 months' hospitalization she has not produced any type of vocalization, nor has she been heard crying. Verbal comprehension is good, if she is called, she turns her head towards her interlocutor. She understands and correctly performs all simple commands given to her by hospital staff. Upon request she can lift her lower and upper limbs correctly. However, a mild right hemiparesis is still observable. She is able to smile, show her teeth and open her mouth, if she is asked to show her tongue, she opens her mouth and tries to stick out her tongue without succeeding. At times when she gives an affirmative answer to a question (for example, 'Are you thirsty?') she moves her lips in the correct position in order to pronounce the first phoneme of the word 'oui', but she is not able to produce any sound. She performs cerebellar tasks correctly but slowly. If her eyelids are held open she is able to perform simple verbal tasks (for example, show two fingers with her left hand, three fingers, etc. upon request). She is able to perform the pointing test correctly [15]. A magnetic resonance study performed in December 1997 enabled a more detailed description of the extent of the lesion which affected the periaqueductal structures of the midbrain (Fig. 2A,B).

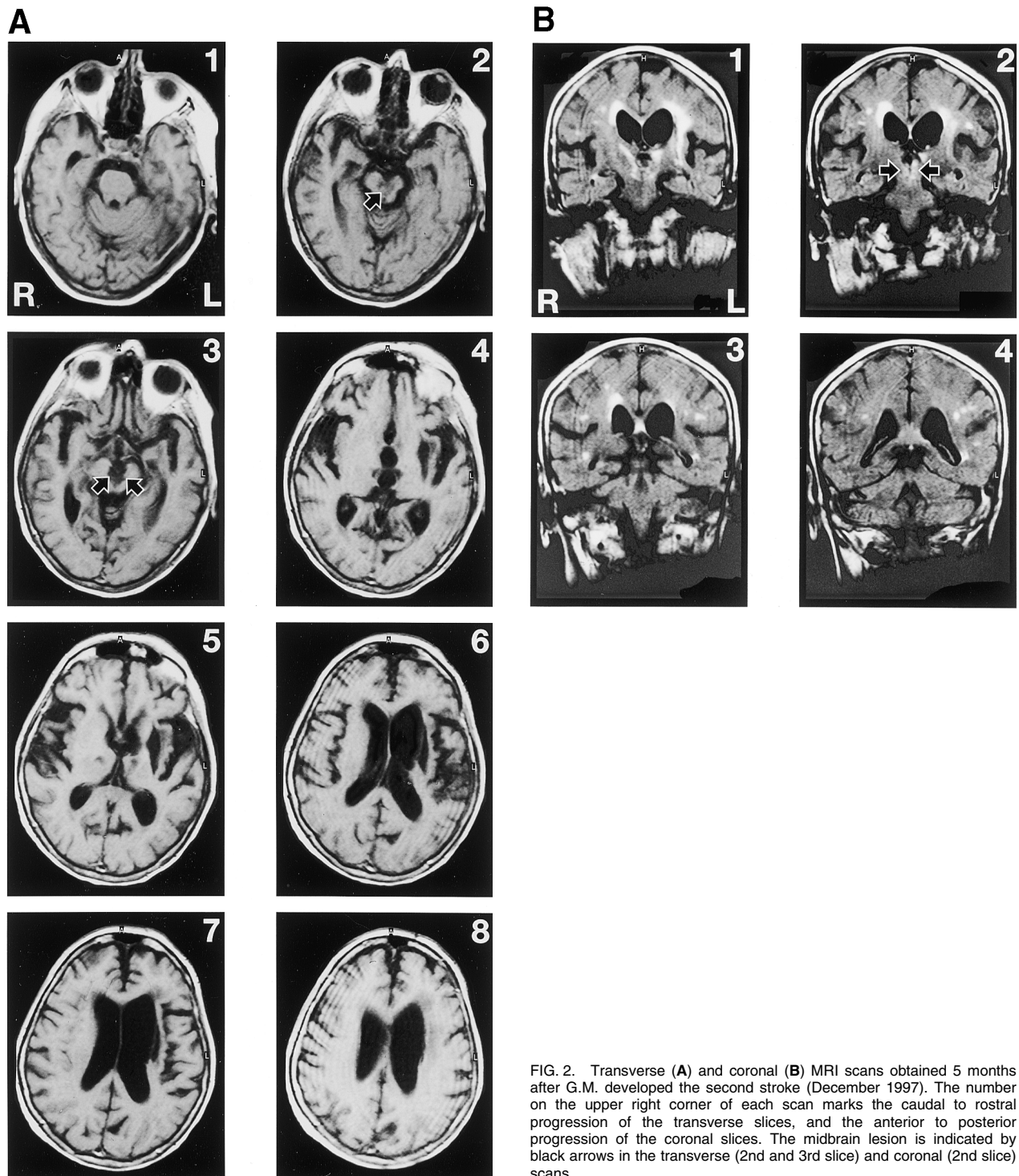


FIG. 2. Transverse (A) and coronal (B) MRI scans obtained 5 months after G.M. developed the second stroke (December 1997). The number on the upper right corner of each scan marks the caudal to rostral progression of the transverse slices, and the anterior to posterior progression of the coronal slices. The midbrain lesion is indicated by black arrows in the transverse (2nd and 3rd slice) and coronal (2nd slice) scans.

**Discussion**

The cases of complete mutism in humans following a lesion to the PAG are extremely rare in the literature [1,7,9,16]. Numerous electrostimulation and experimental lesion studies on various animal species highlighted the fundamental role of this structure in initiating vocalization and in the control of pain-analgesia, fear-anxiety, autonomic regula-

tion and sexual behavior components [6,8,17]. Lesions to the PAG in numerous animal species and in humans provoke complete mutism without affecting voluntary motility and cognitive functions. Patients are oriented as to time and space and are able to understand and perform verbal tasks [10,11]. Lesions to other structures of the nervous system, e.g. the bilateral anterior cingulate cortex, may also provoke mutism syndromes which, however, are

transient [3], whereas lesions to the periaqueductal gray matter provoke absolute and irreversible mutism [9,10].

The localization of the lesion in the patient we studied was carried out both at neuroanatomical and functional level. Mutism in this patient was coupled with excessive sleepiness, bilateral ptosis, bilateral divergent strabismus and large fixed pupils. This picture is due to a lesion localized in the rostral brain stem, which affects the nucleus of the third cranial nerve, the Edinger–Westphal nucleus and the periaqueductal gray matter, following occlusion of the rostral basilar artery [13,14]. This lesion did not affect the tactile, proprioceptive, auditory and pain discrimination pathways, or the pyramidal tract.

The mutism patterns following a lesion to the PAG are to be distinguished from the 'locked-in' syndrome, apallism and global aphasia. Since G.M. was able to understand verbal commands and perform voluntary movements with her limbs, the mutism pattern she exhibited cannot be due to the first two clinical syndromes (locked-in syndrome and apallism), nor to global aphasia. In fact, after the first stroke (December 1994), which had provoked a lesion to the basal ganglia of the left hemisphere, the patient had suffered Broca's aphasia but had shown a good recovery of verbal functions. Ten months after the first stroke the patient had shown a good recovery of her verbal expression and the only aphasic symptoms left were reduced fluency and some phonemic paraphasias. The second stroke (June 1997) not only provoked a mesencephalic lesion but also a thalamic lesion mainly affecting the right thalamus. Whereas lesions to the left thalamus are known to provoke aphasic syndromes, no thalamic lesions have so far been described in correlation with clinical patterns of complete and permanent mutism [18–21].

## Conclusions

Experimental neuroanatomical and neurophysiological studies suggest that the PAG, and in particular the dorso-lateral portion, is the phylogenetically oldest structure responsible for the generation of vocalization [5,7]. This critical structure receives different pathways from numerous subcortical structures (midline thalamus, mediobasal amygdala, sev-

eral hypothalamic areas) and from the anterior cingulate cortex and sends projections to the reticular formation of pons and medulla [17]. The hypothesis has been put forward that the PAG does not participate in the motor coordination of vocalization itself, but is allegedly responsible for the initiation of vocalization and speech following appropriate emotional stimuli [7]. This suggestion seems to be corroborated by some aspects of G.M.'s behavior. Indeed, the patient could not produce any moaning sound or vocalization, not even in reaction to painful stimuli, whereas she could chew, swallow and open her mouth upon request. This fact allows for putting forward the hypothesis that the PAG plays a crucial role in the initiation of vocalization and speech, since it acts as a link between other emotional-motivational structures and the periambigular reticular formation, a structure of the reticular substance functioning as motor coordinator of cranial nerves and respiratory centers, two structures accounting for vocalization and speech.

## References

1. Lebrun Y. *Mutism*. London: Whurr Publisher, 1990.
2. Ersahin Y, Mutluer S, Saydam S and Barçın E. *Clin Neurol Neurosurg* **62**, 130–134 (1997).
3. Jürgens U and Von Cramon D. *Brain Lang* **15**, 234–248 (1982).
4. Cumming JL, Benson F, Houlihan JP and Gosenfeld LF. *J Nerv Mental Dis* **171**, 255–259 (1983).
5. Jürgens U. Anatomical and functional cerebral organisation of phonation in animals. In: Creutzfeldt O, Scheich H and Schreiner Chr., eds. *Hearing Mechanism and Speech*. Berlin: Springer-Verlag, 1979: 171–182.
6. de Lanerolle NC and Lang FF. Functional neural pathways for vocalisation in the cat. In: Newman JD, ed. *The Physiological Control of Mammalian Vocalization*. New York: Plenum Press, 1988: 21–41.
7. Jürgens U. *Behav Brain Res* **62**, 107–117 (1994).
8. Ploog D. *Human Neurobiol* **6**, 227–238 (1988).
9. Botez M and Barbeau A. *Int J Neurol* **8**, 300–320 (1971).
10. Steriade M, Botez MI and Petrovici I. *Psychiat Neurol* **141**, 38–58 (1961).
11. Botez M. *Ideggyógyászati Sz* **1**, 13–29 (1964).
12. Segarra JM. *Arch Neurol* **22**, 408–418 (1970).
13. Caplan LR. *Neurology* **30**, 72–79 (1980).
14. Caplan LR. Vertebrobasilar system syndromes. In: Vinken PJ, Bruyn GW and Klawans HL, eds. *Handbook of Clinical Neurology*, vol. 53. Amsterdam: Elsevier, 1988: 371–409.
15. Paradis M. *The Assessment of Bilingual Aphasia*. Hillsdale, NJ: Erlbaum, 1987.
16. Lebrun Y. Mutism. In: Asher RE, ed. *The Encyclopedia of Language and Linguistics*. Oxford: Pergamon Press, 1994: 2655–2658.
17. Behbehani MM. *Prog Neurobiol* **46**, 575–605 (1995).
18. Crosson B. *Subcortical Functions in Language and Memory*. New York: The Guilford Press, 1992.
19. Crosson B, Zawacki T, Brinson G et al. *J Neurolinguistics* **10**, 277–300 (1997).
20. Wallish C-W. *J Neurolinguistics* **10**, 267–276 (1997).
21. Fabbro F, Peru A and Skrap M. *J Neurolinguistics* **10**, 347–367 (1997).

ACKNOWLEDGEMENTS: We are grateful to Professor Y. Lebrun, Professor M. Paradis and Dr V. Daró for improving the manuscript.

**Received 2 December 1998;  
accepted 4 January 1999**