



PII S0145-2134(98)00128-8

THE ROLE OF CRANIAL MRI IN IDENTIFYING PATIENTS SUFFERING FROM CHILD ABUSE AND PRESENTING WITH UNEXPLAINED NEUROLOGICAL FINDINGS

BRIGITTE CHABROL

Neuropediatrics Unit, CHU Timone, Marseille, France, and Department of Pediatrics, Hôpital Sainte-Justine, Montréal, Quebec, Canada

JEAN-CLAUDE DECARIE

Department of Medical Imaging, Hôpital Sainte-Justine, Montréal, Quebec, Canada

GILLES FORTIN

Department of Pediatrics, Hôpital Sainte-Justine, Montréal, Quebec, Canada

ABSTRACT

Objective: The aim of this study was to demonstrate the usefulness of cerebral MRI to detect possible child abuse in children with unexplained neurologic findings.

Method: Between 1990 and 1997, 208 children were referred for suspected physical child abuse to the Child Protection Clinic of Ste-Justine Hospital, a tertiary care pediatric hospital. Among them, 39 children presented initially with neurological findings. For 27 of them, the CT Scan results prompted the diagnosis of child abuse. However, in 12 children, even if a CT-Scan was performed, the diagnosis and/or the mechanisms of the neurologic distress remained obscure. Investigation was completed with MRI study in those 12 cases.

Results: MRI findings were diagnostic for physical abuse in eight cases. A diagnosis of child abuse was made in two more cases by a combination of MRI and skeletal survey findings. In one case, MRI was suggestive but the diagnosis of child abuse could not be confirmed. One case was misinterpreted as normal.

Conclusions: MRI is the test of choice to rule out child abuse when faced with a child presenting unexplained neurologic signs lasting for few days. The fact that MRI can better differentiate collections of different ages makes this imaging test particularly useful in identifying cases of child abuse. These results, however, always have to be integrated in a well conducted multidisciplinary clinical approach. © 1999 Elsevier Science Ltd

Key Words—MRI, Child abuse, Head injury.

INTRODUCTION

DURING THE LAST 20 years the development of modern neuroradiology (CT-Scan, then MRI) has allowed a better pathologic understanding to the diagnosis of children who present with acute

Received for publication April 10, 1998; final revision received July 31, 1998; accepted August 7, 1998.

Reprint requests should be addressed to Dr. Brigitte Chabrol, Service de Neuropédiatrie, Hôpital d'Enfants, CHU Timone, 13385 Marseille Cedex 5, France.

neurological findings. The diagnostic difficulties are various and the real incidence of child abuse among the cases of neurologic distress remains unknown. However, when evaluating the cause of head injury in an infant, pediatricians must consider all origins including the potential role of abuse which is often misdiagnosed. Head injury represents from 10% to 20% of all physical child abuse. The highest incidence is in children under 2 years of age (Levitt, Smith, & Alexander, 1994). Classically, the diagnosis of Shaken Baby Syndrome (SBS) was made by a combination of retinal hemorrhages seen by fundoscopic examination, and subdural hemorrhages and cerebral edema seen on neuroradiological studies. Previous studies (Alexander, Schor, & Smith, 1986; Nimkin & Kleinmann, 1997; Sato, Yuh, Smith, Alexander, Kao, & Ellerbroek, 1989) demonstrated that MRI is a more sensitive method than CT Scan to diagnose child abuse.

We report here on 12 children who presented neurological signs with uncertain diagnosis after CT Scan. The more accurate information provided by MRI has been helpful in the multidisciplinary investigation of possible child abuse.

Patients and Methods

Patients. Between 1990 and 1997, 208 children patients were referred for suspicion of physical abuse to the Child Protection Clinic of Ste-Justine Hospital university teaching and a tertiary care pediatric hospital. Among them, 39 children presented initially with neurological findings. For 27 of them, the CT Scan results added to complete medical and social history prompted to make the diagnosis of child abuse. However, even if a CT scan was performed in 12 children (five girls, seven boys, mean age: 3 months), the diagnosis and/or the mechanism of the neurological distress remained obscure. In these patients, the initial diagnosis was encephalitis in two cases, venous thrombosis in one case, ischemic brain injury with gastroenteritis in an other case, vascular abnormalities in two cases (one of which had mild coagulation abnormality), accidental head trauma in two other cases, and suspicion of SBS in two cases. In two cases, no diagnosis was made because of normal CT Scan findings. Investigation was completed with MRI study in those 12 patients.

MRI procedures. Images were acquired on two units: a General Electric Sigma 1.5 Tesla system and a ELSCINT 2 Tesla system. Coronal and Axial T1 and T2 weighted sequences were used. MR angiography was performed when judged necessary by the radiologists in charge.

RESULTS

Patient 1: This 2 and 1/2 month old boy presented first with generalized seizures, followed 24 hours later by diarrhea. Diagnosis of gastroenteritis was made, but 2 days later, seizures were again observed. Physical examination revealed drowsiness, head circumference at 41.5 cm with normal fontanel, but the child developed status epilepticus and was transferred to the intensive care unit because assisted ventilation was necessary for 4 days. CT Scan showed multiple low density areas in the right parietal and frontal lobes, but also in left posterior parietal parenchyma. Optic fundi showed pallor of papilla. CSF, electrolytes, coagulation values, and echocardiography were normal. Ten days later, MRI showed several lesions which were of low signal in T1, high signal in T2 in right and left frontal areas and bilateral posterior parietal areas. With infusion of contrast, enhancement was noted at the sites of these lesions and in the basal ganglia. A well-marginated slit-like lesion in the superficial cerebral white-matter in left temporal area was noted. These findings were compatible with ischemic-anoxic injuries. Cerebral angiography was performed and did not reveal any vascular malformations or thrombosis. The skeletal survey revealed a periosteal new bone formation on the medial side of the left tibia suggesting an old fracture. Therefore, the diagnosis of physical abuse was suggested by combination of MRI and

skeletal survey findings. At 3 years of age, his neurological examination showed microcephaly, with left hemiparesis and language delay.

Patient 2: This 1 and 1/2 month old girl was admitted for hyperthermia and drowsiness for 48 hours, but without seizures. CT Scan showed a focal area of high density in the right ventricular occipital horn. CSF was normal in spite of a clinical diagnosis of encephalitis. Serologic studies were negative. Optic fundi were normal. Eleven days later, MRI showed focal encephalomalacia in the right temporal lobe with areas of hemorrhage presenting as high signal intensity on T1-weighted images and low signal intensity on T2-weighted images. A subarachnoid hemorrhage was also noted in both occipital areas. Therefore, the two diagnoses considered were child abuse and encephalitis. At this time, a skeletal survey was performed which showed right corner metaphyseal fractures of the proximal and distal tibia suggesting a torsion injury. Therefore, the diagnosis of child abuse was made by a combination of MRI and skeletal survey findings. Five months later, a new MRI showed focal encephalomalacia in the right temporal area and to a lesser degree in the left temporal area.

Patient 3: This 4 and 1/2 month old boy was admitted for left-sided seizures. A story of a fall was noted at 3 months, but without clinical signs. At 4 months, a suspicion of splenic hematoma was made but not confirmed. At admission, physical examination revealed left hemiparesis. Head circumference was 42 cm. Status epilepticus developed. CT Scan showed loss of the gray-white matter differentiation in right posterior temporal, occipital, and parietal area and to a lesser degree in the left occipital parenchyma. An interhemispheric subdural hemorrhage was noted. Optic fundi were normal, but no ocular pursuit was noted. The diagnosis of viral encephalitis was made, but CSF and serologic studies were negative. Twenty days later, MRI showed high intensity T2 signal in both occipital and posterior temporal areas and in the basal ganglia. These findings were compatible with traumatic injuries of the occipital areas, associated with an anoxic event. Cerebral angiography, echocardiography, and skeletal survey were normal. Therefore, in this patient MRI was suggestive but the diagnosis of child abuse could not be confirmed. In spite of these suspicious results, the child was nonetheless sent home with his parents. A new MRI performed 5 months later, showed only slight necrosis in the posterior occipital area. One year later, the child was placed in a foster family because of neglect. His neurological exam showed a slight motor delay.

Patient 4: This 2 month old boy had fever for 24 hours, and several tonic-clonic seizures. His exam at admission revealed drowsiness, axial hypotonia, seizures, and anemia (hemoglobin was 8.5 g/l). CT Scan showed hyperdensity in the falx (Figure 1a), and a diagnosis of venous thrombosis was made in the context of possible hemolytic/uremic syndrome. Optic fundi showed bilateral retinal hemorrhages without edema. Fifteen days later, MRI showed subdural hematoma of different ages and chronic subarachnoid hemorrhages (Figure 1b). Therefore, the diagnosis of child abuse was made by a combination of fundoscopic and MRI findings. Three years later, this young boy presents with optic atrophy, retinal abnormalities, and global psychomotor delay.

Patient 5: A fall from a table was reported for this 3 and 1/2 month old girl, followed in the next hours by anorexia and drowsiness. Physical exam at admission, 12 hours later, was normal. Head circumference was 41.3 cm. CT Scan showed chronic subdural hematoma. Five days later, MRI confirmed a subacute subdural hematoma seen only on T1 weighted images. These findings were not compatible with the alleged history and, therefore, were suggestive of child abuse. Optic fundi and skeletal survey were normal.

Patient 6: This 5 and 1/2 month old girl was admitted with a history of head trauma after being hit with a baseball. There were no clinical signs immediately. But 4 hours later, she had a brief loss of consciousness. Physical exam showed bulging fontanel, irritability, and head circumference at 45 cm. Skull x-rays showed a fracture involving the left parietal and occipital bones. CT Scan showed acute subdural hematoma and subarachnoid hemorrhage in the frontal area. Optic fundi showed retinal and preretinal hemorrhages. A subdural drainage was performed. Twenty days

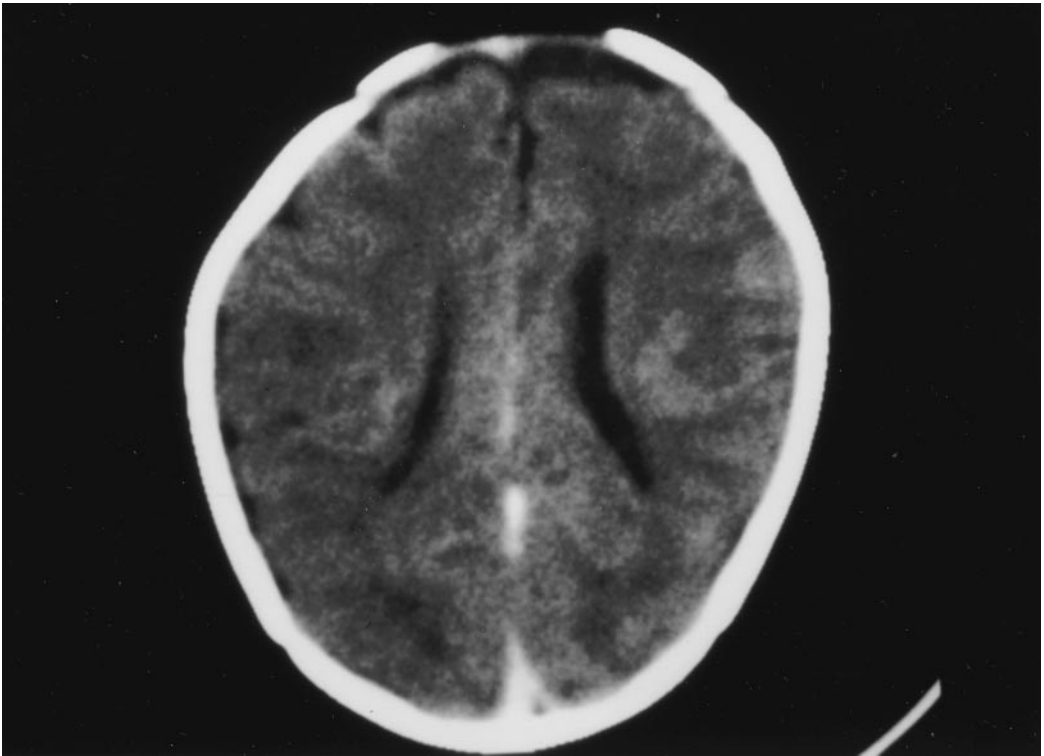


Figure 1a. In patient 4, Ct Scan showed hyperdensity in falx.

later, MRI showed several subdural hematoma of different ages with the largest in the inter-hemispheric area in a chronic phase, two subdural collections in the posterior fossa were more recent. Also two small areas of older subarachnoid hemorrhage were observed. These findings suggested a Shaken Baby Syndrome associated with direct trauma to the head. Three months later, this young girl showed psychomotor delay.

Patient 7: This 1 month old boy presented with status epilepticus requiring assisted ventilation and transfer to the intensive care unit. Upon admission, bruises were noted on left eyelid, right ear, and abdomen. CT Scan showed a right temporoparietal fracture, cerebral edema, and inter-hemispheric hemorrhage. Optic fundi revealed retinal hemorrhages in the right eye. Coagulation values were normal. The child remained intubated for 11 days. At this time, MRI (Figure 2) showed subdural hematoma of different ages, subarachnoid hemorrhages, and several areas of encephalomalacia. These findings were compatible with SBS. Skeletal survey confirmed this diagnosis and showed right and left clavicle fractures of different ages, several rib fractures also of different ages, and a parietal skull fracture. At 3 and 1/2 years, his neurological examination showed severe sequelae with microcephaly, spasticity, and epilepsy. The father's confession was obtained.

Patient 8: This 2 and 1/2 month old girl was admitted for anorexia and tonicoclonic seizures. Her exam revealed irritability, bulging fontanel, and bruises on her forehead. The first CT Scan showed increased pericerebral fluid and a hemorrhagic left contusion. Optic fundi revealed retinal hemorrhages. Eighteen days later, MRI (Figure 3) showed a chronic subdural hematoma, a hemorrhagic left frontal contusion, an older hematoma in the posterior fossa, and bilateral areas of periventricular encephalomalacia. These findings suggested SBS. At 2 years, she showed motor and language delay. The father's confession was obtained.

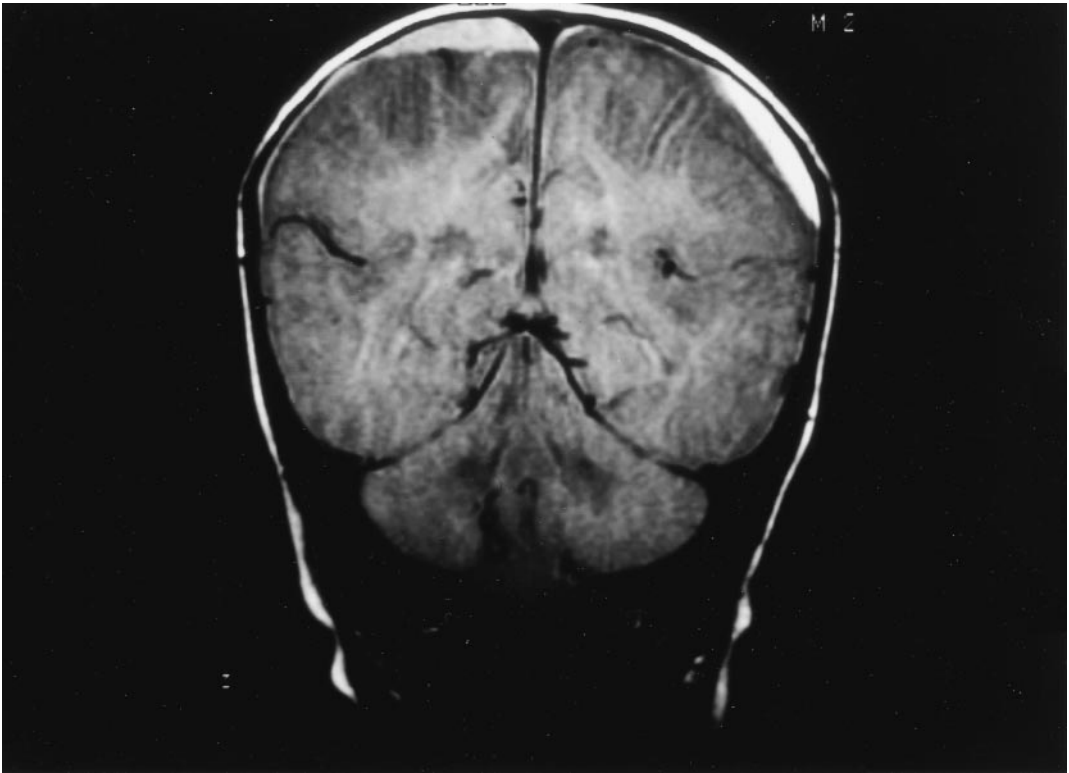


Figure 1b. In this same patient (number 4), 15 days later, MRI showed several subdural hematomas.

Patient 9: This 2 month old boy was admitted for seizures without fever. At examination, eyelid, knee, elbow bruises, and bulging fontanel were noted. There was no neurological deficit. CT Scan showed two areas of encephalomalacia in the frontal lobes with a hyper dense inner component, suggesting an old vascular injury. Five days later, MRI confirmed the hemorrhagic area with high signal intensity on T1-weighted images and low signal intensity on T2-weighted images. There was also an old parieto occipital right subdural hematoma and a more recent left temporal subdural hematoma. MRI angiography revealed no vascular anomaly. Coagulation values were normal. Though MRI suggested child abuse, no followup was performed. Four months later, this young boy was readmitted because of family violence. A new CT Scan revealed partial involution of the frontal lobe lesions. Two days later, a second MRI showed a depressed anterior fontanel, signs of brain atrophy, a recent right frontal subacute subdural hematoma, a chronic subdural hematoma at the convexity of both hemispheres, and area of frontal atrophy with hemosiderin inside. The areas of encephalomalacia in the frontal lobes suggested direct trauma through the fontanel. This child was placed in a foster family.

Patient 10: This 1 and 1/2 month old girl was admitted for respiratory distress with apneic events. A few hours later, she developed status epilepticus and she was admitted to the intensive care unit. She had a congenital anomaly of the left forearm and hand. Optic fundi revealed retinal hemorrhages, more severe in the left eye. CT Scan revealed hemorrhagic injury in the right parietal area and a vascular malformation was suspected (Figure 4a). Coagulation values were slightly abnormal with mild prothrombin time prolongation. Two days later, MRI (Figure 4b) showed several subdural hematomas of different ages in both frontal, and occipital areas and in the left parietal area. Subarachnoid hemorrhage was also observed in the left parietal area. MRI

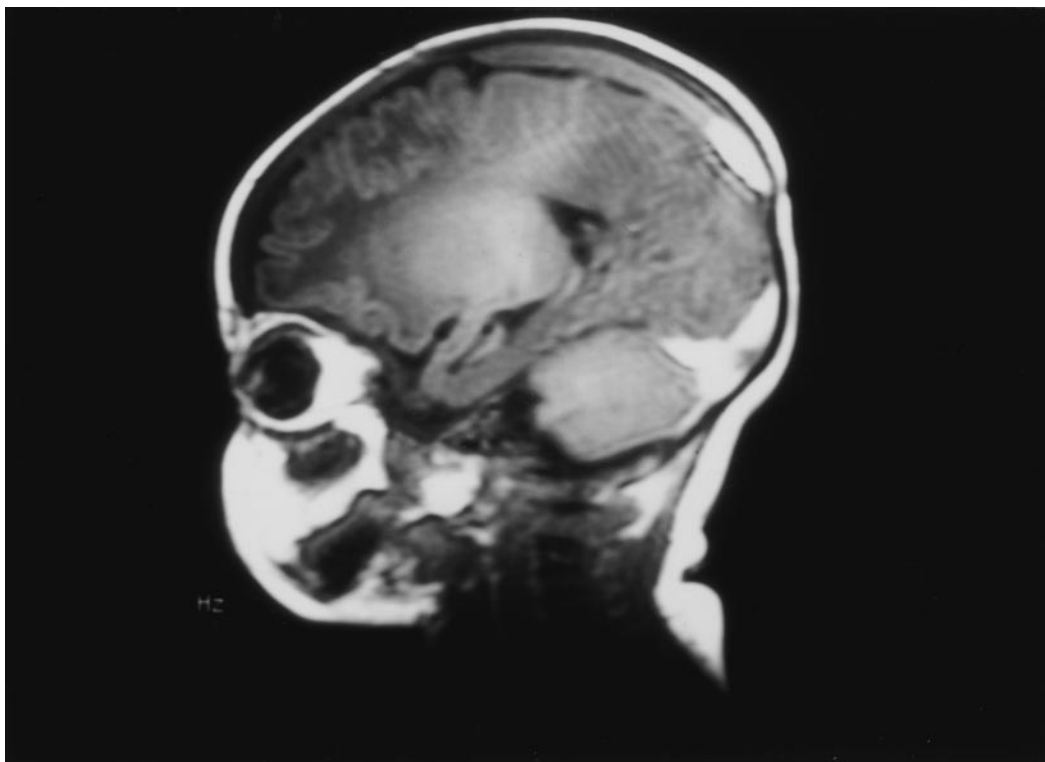


Figure 2. In patient 7, MRI showed subdural hematomas of different ages.

angiography did not visualize any venous thrombosis or vascular malformation. Therefore, the diagnosis of SBS was made by a combination of fundoscopic and MRI findings. This child was placed in a foster family.

Patient 11: This 2 month old girl was admitted for apneic episodes. At admission, the neurological exam was normal. The investigation of her apneic events prompted esophagography which was normal, but revealed rib fractures. A skeletal survey showed at this time multiple fractures of different ages (clavicles, ribs, femur, tibia, and skull). Therefore, CT Scan was performed and was normal. There was no explanation for the apneic event in this context. But, 6 days later MRI was performed and showed an old subdural hematoma, with an hemorrhagic right frontal contusion, suggestive of head injury in this case of child abuse.

Patient 12: This 8 month old boy was admitted for hypotonia and fever. Xanthochromic CSF was noted on lumbar puncture. The first CT scan was interpreted as normal. This young boy was sent back home. Twenty days later, MRI was wrongly interpreted as normal. At 9 and 1/2 months, he was admitted to the emergency unit in a coma. CT Scan showed brain edema with loss of the gray-white matter differentiation and an acute interhemispheric subdural hematoma. The child passed away 12 hours after being admitted. Post mortem examination revealed several old subdural hemorrhages. The review of the MRI showed a subtle subacute subdural hemorrhage unrecognized at the first interpretation.

Summary of our results. In our study, each case has been discussed with a multidisciplinary team composed by pediatricians, radiologists, social workers, nurses, and psychologists. The diagnosis of abuse was suggested by combination of MRI and optic fundi findings in six cases. Among them,

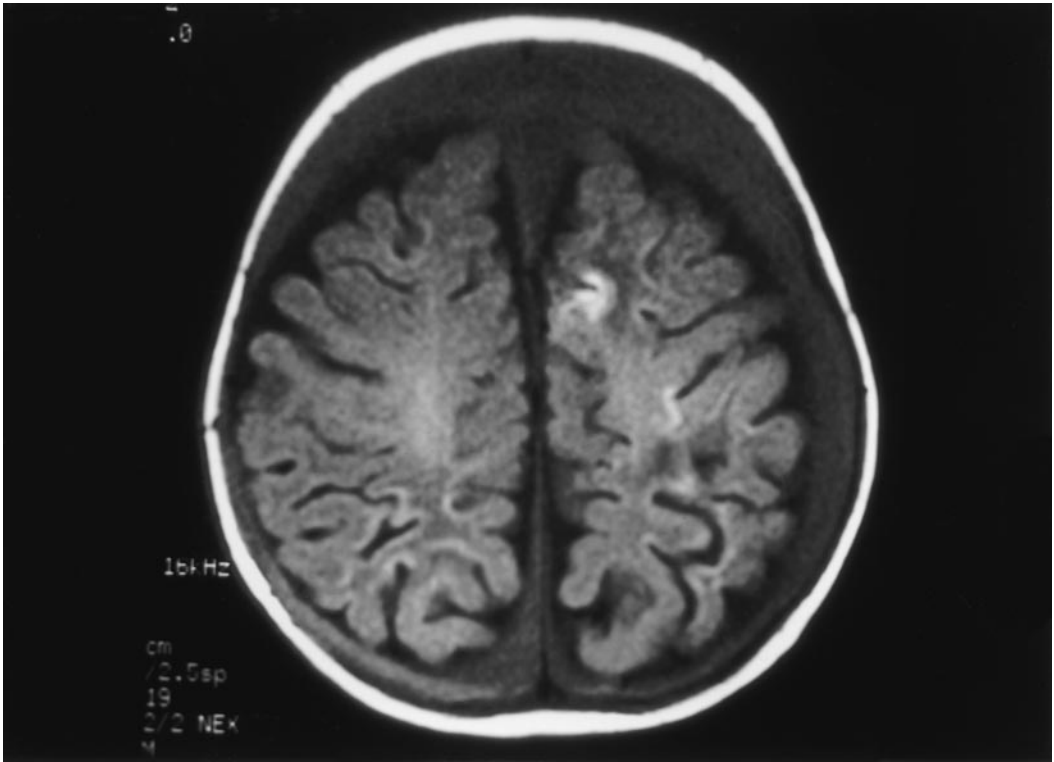


Figure 3. In patient 8, MRI showed a chronic subdural hematoma and a hemorrhagic left frontal contusion.

three patients also presented fractures suggesting child abuse. In two cases, the diagnosis of child abuse was made by combination of MRI findings and skeletal survey. In one case, MRI findings were not compatible with alleged history, and suggested child abuse. In two other cases, a diagnosis of child abuse was made because MRI findings and sociofamilial history, but in one case, the diagnosis could not be confirmed. One case was misinterpreted as normal (cf Table 1).

DISCUSSION

In the infant, the occurrence of acute unexplained neurological symptoms should not only be managed aggressively, but also be investigated as to the etiology. If the child has no fever, metabolic and neuroradiological examinations must be performed. In the presence of fever, encephalitis or meningitis have to be considered and lumbar puncture performed rapidly. In child abuse, neurological signs and symptoms are varied and often nonspecific, mimicking gastroenteritis, encephalitis, or apnea. Pediatricians must consider head injury in the differential diagnosis of these symptoms, especially if the child is young. On the other hand, alleged history of accidental trauma must be accepted with caution to explain these symptoms (Duhaime, Alario, Lewander, Schut, Sutton, Seidl, Nudelman, Budenz, Hertle, Tsiaras, & Loporchio, 1992). The patient's clinical followup is very important. Most frequently, clinical signs in intentional head trauma are at their peak at the time of admission. On the opposite site, these signs will become more manifest later in cases of encephalitis or metabolic diseases (Levitt, Smith, & Alexander, 1994). Finally, some cases of Shaken Baby Syndrome have been misdiagnosed, because some professionals don't

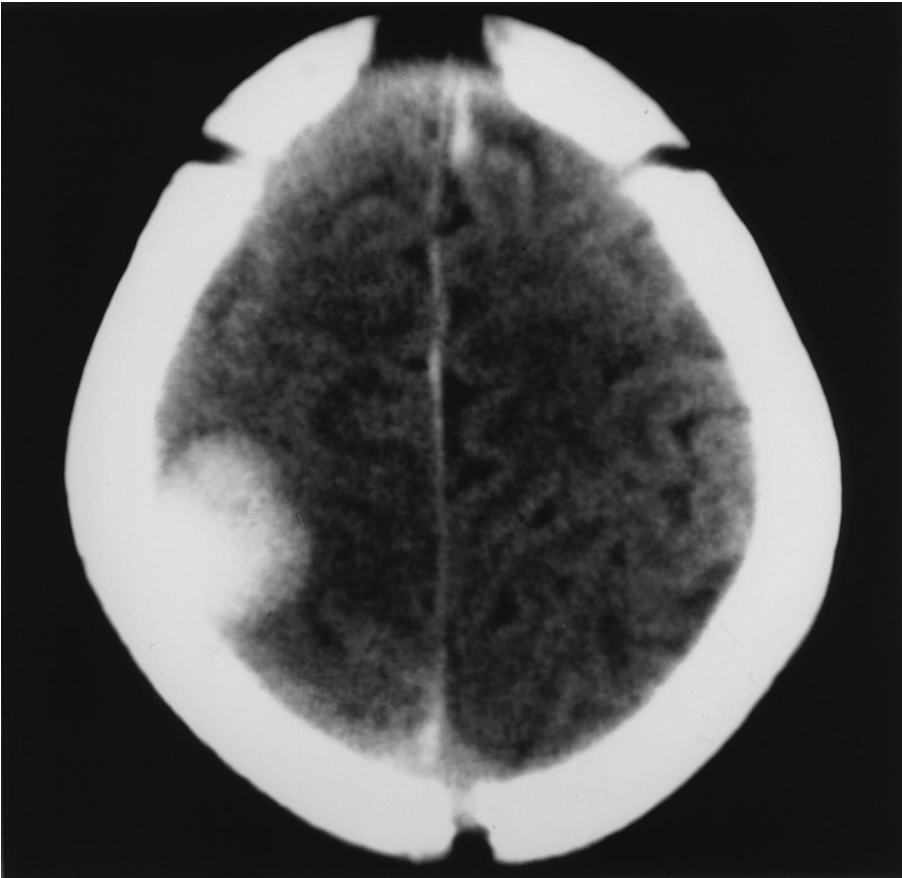


Figure 4a. In patient 10, CT Scan revealed hemorrhagic injury in the right parietal area and a vascular malformation was suspected.

consider this possibility. Donald and Jureidini (1996) consider that child abuse is more likely to be misdiagnosed when “there is a medical system that is specialized, investigation orientated, fascinated by rare conditions, often ignorant of abusive behaviors.”

The diagnosis of SBS was made by a combination of retinal hemorrhages, subdural hematomas, and cerebral edema (Caffey, 1974; Duhaime, Chistian, & Zimmerman, 1998; Duhaime, Gennarelli, Thibault, Bruce, Margulies, & Wisner, 1987; Lazowitz, Baldwin, & Kini, 1997). In our study, only five patients presented with retinal hemorrhages. However, this exam was often delayed and was not included in the screening at the time of admission. The first National Conference of SBS (Salt-Lake City, November 1996), recommended that all children under the age of 2 who show central nervous system symptoms should receive an eye exam done by an experienced examiner or ophthalmologist at the time of admission. In fact, retinal hemorrhages are present in 65% to 95% of cases of SBS, and occurs rarely in accidental head injury (Buys, Levin, Enzenauer, Elder, Letourneau, Humphreys, Mian, & Morin, 1992; Green, Lieberman, Milroy, & Parsons, 1996; Johnson, Braun, & Friendly, 1993), and never in encephalitis (Newton, 1989). In some cases, there is evidence of retinal hemorrhages without visible subdural hematoma in CT scan. As convexity subdural hematomas associated with hemispheric brain swelling are difficult to visualize from CT scan alone, MRI is particularly helpful in this context.

On the other hand, previous studies (Alexander, Schor, & Smith, 1986; Feldman, Brewer, &

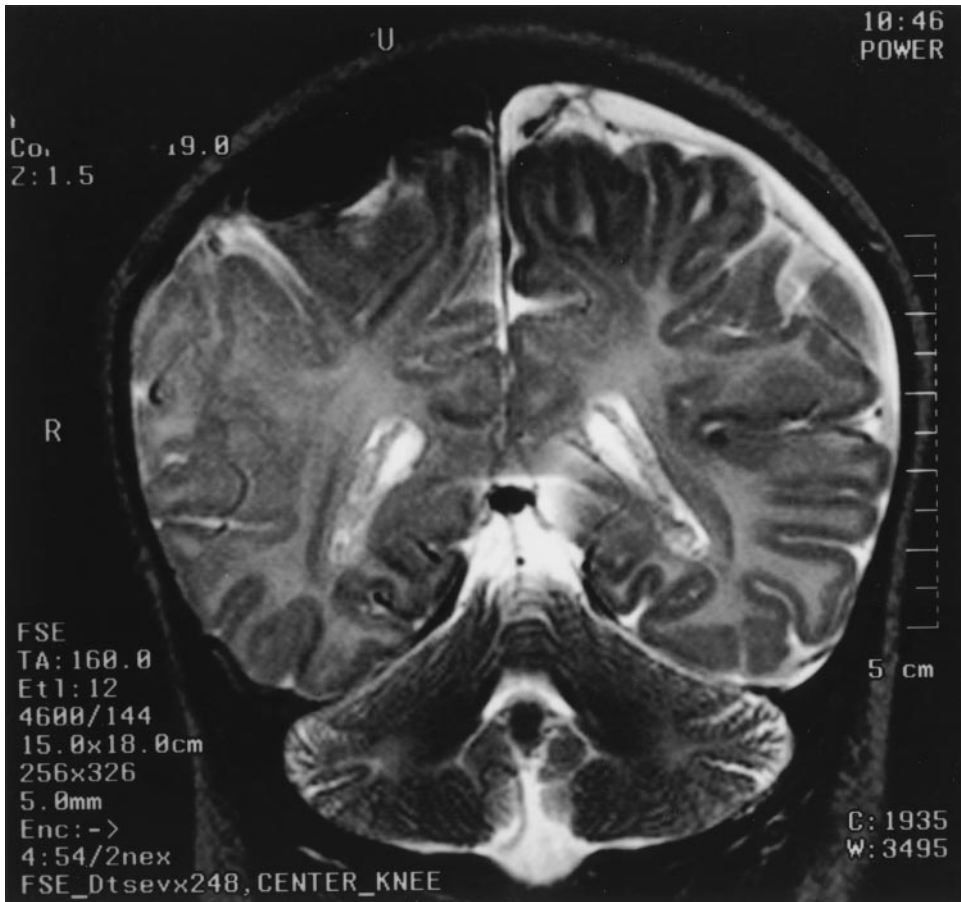

Figure 4b. In patient 10, MRI showed several subdural hematomas of different ages in both frontal areas.

Shaw, 1995; Nimkin & Kleinmann, 1997; Sato, Yuh, Smith, Alexander, Kao, & Ellerbroek, 1989) demonstrated that CT Scan and MRI have helped in the recognition of abuse as a leading cause of head injury in children. MRI has several advantages over CT scan because in many cases there are no direct signs of trauma, or sign of subdural hematoma (Frank, Zimmerman, & Leeds, 1985). One of the problems is to determine the most appropriate time to perform MRI. In fact, acute subarachnoid or subdural hemorrhage are more difficult to identify on MRI than on CT Scan. MRI is also much less available than CT in the context of an emergency situation. In our study, MRI was performed at mean of 11 days after admission (range: 2–20). MRI is better performed at least several days after the presumed injury time, MRI has an increased sensitivity to detect intracranial bleeding compared to CT scan. MRI allows identification of subdural blood collections of various ages, due to changes in signal of the hematoma secondary to the transformation of hemoglobin degradation products (Barkovich & Atlas, 1988, Merten & Carpenter, 1990). So, hemorrhage has a much higher intensity in MRI images with the passage of time, its appearance has become intensified on T1 weighted images (Bradley & Schmidt, 1985). On the other hand, MRI gives increased clarity and greater details in parenchymal injuries and in evaluation of the posterior fossa. In our study, additional findings provided by MRI were particularly useful to diagnose SBS in eight cases. Coexistence of subdural blood that appears to be of various ages on MRI indicates that the injuries occurred at different times, suggesting repeated episodes of shaking. This particular finding

Table 1. Summary of MRI, Optic Fundi and Skeletal Survey Results in our 12 Children

Case	Age (Months)	Time Elapsed Between Initial CT Scan and MRI	Subdural and/or Subarachnoid Hemorrhages	Different Ages of Lesions	MRI: Parenchymal Injuries	MRI: Ischemic-Anoxic Findings	Optic Fundi Results	Skeletal Survey Results
1	2.5	Day 10	No	No	Several	Yes	Palor of papilla	Tibial old fracture
2	1.5	Day 11	One subarachnoid hemorrhage	No	Focal encephalomalacia in right temporal area	Yes	Normal	Corner metaphyseal fractures
3	4.5	Day 20	No	No	Multiple	Yes	Normal	Normal
4	2	Day 15	Several subdural and subarachnoid hemorrhages	Subacute and chronic	No	No	Retinal hemorrhages	
5	3.5	Day 5	One subdural hematoma	Chronic hematoma not compatible with history	No	No	Normal	Normal
6	5.5	Day 20	Several subdural and subarachnoid hemorrhages	Subacute and chronic	No	No	Retinal and preretinal hemorrhages	Parietal and occipital fractures
7	1	Day 11	Several subdural and subarachnoid hemorrhages	Subacute and chronic	Several area of encephalomalacia	No	Retinal hemorrhages	Several fractures
8	2.5	Day 18	Several subdural hematoma	Subacute and chronic	Hemorrhagic frontal left contusion area and bilateral periventricular encephalomalacia	No	Retinal hemorrhages	
9								
a)	2	Day 5	Several subdural hematoma	Subacute and chronic	Two frontal hemorrhagic injuries	No		
b)	4	Day 2	Recent subdural hematoma	Subacute and chronic	No	No	Normal	
10	1.5	Day 2	Several subdural and subarachnoid hemorrhages	Subacute and chronic	No	No	Retinal hemorrhages	
11	2	Day 6	One subdural hematoma	Subacute	Frontal hemorrhagic contusion	No		Several fractures
12	8	Day 20	One subdural hematoma but after post-mortem review	No	No	No		

constitutes a real marker of head injury in child abuse. Caffey (1974) described SBS as a “condition with whiplash-induced intracranial and intraocular bleeding,” but already Tardieu (1860) noted intracranial hemorrhages at the autopsy of children who were abused. As the presence of multiple fractures of different ages on skeletal survey, the presence of subdural hematomas of different ages on MRI suggests several subsequent severe shaking episodes, not consistent with the frequently alleged history of a unique event of shaking by caretakers because “the child cried, or fainted.”

In three cases of our study, MRI did not reveal subdural hematomas, but nonspecific ischemic-anoxic findings. In an infant, hypoxic-ischemic injuries can be the result of different mechanisms such as embolic events, respiratory infections, severe gastroesophageal reflux, but also trauma events or intentional suffocation. To date there is no way to identify intentional suffocation even at postmortem exam. Because hypoxic events can be repeated with resulting recurrent hypoxic cerebral injury, Sothall, Plunkett, Banks, Falkov, and Samuels (1997) proposed recently a covert video recording of life-threatening child abuse.

Finally, because one of our cases presented with a final mortal event, we want to emphasize the importance of careful assessment of MRI images. Initial MRI interpretation failed to appreciate very small subdural blood collections. After the death of this patient, the review of the MRI revealed a subtle subdural hematoma which had been overlooked; autopsy revealed old and new subdural hematomas.

We agree with Kleinman, Nimkin, Spevak, Rayder, Madansky, Shelton, and Patterson (1996) when they said: “Whether abuse is considered clinically or in court, three important questions must be answered. How many injuries are present, what is their specificity for abuse, and how old are they?” MRI is really useful for answering these questions, especially when performed several days after the initial event. MRI is the test of choice to rule out child abuse when faced with a child presenting unexplained neurologic signs lasting for a few days. MRI allows identification of intracranial blood collection of various ages. The presence of hemorrhagic lesions of different ages strongly favors the diagnosis of child abuse. However, the final accurate diagnosis in each patient has to be substantiated by a multidisciplinary team constituted by pediatricians, neurologists, ophthalmologists, radiologists, nurses, and social workers.

REFERENCES

- Alexander, R. C., Schor, D. P., & Smith W. L. (1986). Magnetic resonance imaging of intracranial injuries from child abuse. *Journal of Pediatrics*, **109**, 975–979.
- Barkovich, A. J., & Atlas, S. W. (1988). Magnetic resonance imaging of intracranial hemorrhage. *Radiologic Clinics of North America*, **26**, 801–820.
- Bradley, W. G., & Schmidt, P. G. (1985). Effect of methemoglobin formation on the MRI appearance of subarachnoid hemorrhage. *Radiology*, **156**, 99–103.
- Buys, Y. M., Levin, A. V., Enzenauer, R. W., Elder, J. E., Letourneau, M. A., Humphreys, R. P., Mian, M., & Morin, J. D. (1992). Retinal findings after head trauma in infants and young children. *Ophthalmology*, **99**, 1718–1723.
- Caffey, J. (1974). The whiplash shaken infant syndrome: Manual shaking by the extremities with whiplash-induced intracranial and intraocular bleeds, linked with residual permanent brain damage and mental retardation. *Pediatrics*, **54**, 396–403.
- Donald, T., & Jureidini, J. (1996). Munchausen syndrome by proxy. Child abuse in the medical system. *Archives of Pediatric Adolescent Medicine*, **150**, 753–758.
- Duhaime, A. C., Gennarelli, T. A., Thibault, L. E., Bruce, D. A., Margulies, S. S., & Wiser, R. (1987). The shaken baby syndrome: A clinical, pathological, and biochemical study. *Journal of Neurosurgery*, **66**, 409–415.
- Duhaime, A. C., Alario, A. J., Lewander, W. J., Schut, L., Sutton, L. N., Seidl, T. S., Nudelman, S., Budenz, D., Hertle, R., Tsiaras, W., & Loporchio, S. (1992). Head injury in very young children: Mechanisms, injury types, and ophthalmologic findings in 100 hospitalized patients younger than 2 years of age. *Pediatrics*, **90**, 179–185.
- Duhaime, A. C., Christian, C. W., Rorke, L. B., & Zimmerman, R. A. (1998). Nonaccidental head injury in infants—The shaken-baby syndrome. *New England Journal of Medicine*, **338**, 1822–1829.
- Feldman, K. W., Brewer, D. K., & Shaw, D. W. (1995). Evolution of the cranial computed tomography scan in child abuse. *Child Abuse & Neglect*, **19**, 307–314.
- Frank, Y., Zimmerman, R., & Leeds, N. M. D. (1985). Neurological manifestations in abused children who have been shaken. *Developmental Medicine & Child Neurology*, **27**, 312–316.

- Green, M. A., Lieberman, G., Milroy, C. M., & Parsons, M. A. (1996). Ocular and cerebral trauma in nonaccidental injury in infancy: Underlying mechanisms and implications for pediatric practice. *British Journal of Ophthalmology*, **80**, 282–287.
- Johnson, D. L., Braun, D., & Friendly, D. (1993). Accidental head trauma and retinal hemorrhage. *Neurosurgery*, **33**, 231–235.
- Kleinman, P., Nimkin, K., Spevak, M. R., Rayder, S. M., Madansky, D. L., Shelton, Y. A., & Patterson, M. M. (1996). Followup skeletal surveys in suspected child abuse. *American Journal of Radiology*, **167**, 893–896.
- Lazoritz, S., Baldwin, S., & Kini, N. (1997). The whiplash shaken infant syndrome: Has Caffey's syndrome changed or have we changed his syndrome? *Child Abuse & Neglect*, **21**, 1009–1014.
- Levitt, C. J., Smith, W. L., & Alexander, R. C. (1994). Abusive head trauma. In R. M. Reece (Eds.), *Child abuse: Medical diagnosis and management* (pp. 1–22). Philadelphia, PA: Lea & Febiger.
- Merten, D. F., & Carpenter, B. L. M. (1990). Radiologic imaging of inflicted injury in the child abuse syndrome. *Pediatric Clinics of North America*, **37**, 815–837.
- Newton, R. W. (1989). Intracranial hemorrhage and nonaccidental injury. *Archives of Diseases in Childhood*, **64**, 188–190.
- Nimkin, K., & Kleinmann, P. K. (1997). Imaging of child abuse. *Pediatric Clinics of North America*, **44**, 615–635.
- Sato, Y., Yuh, W. T. C., Smith, W. L., Alexander, R. C., Kao, S. C. S., & Ellerbroek, C. J. (1989). Head injury in child abuse: Evaluation with MR Imaging. *Radiology*, **173**, 653–657.
- Sothall, D. P., Plunkett, M. C. B., Banks, M. W., Falkov, A. F., & Samuels, M. P. (1997). Covert video recordings of life-threatening child abuse: Lessons for child protection. *Pediatrics*, **100**, 735–760.
- Tardieu, A. (1860). Etude médico-légale sur les sévices et mauvais traitements exercés sur des enfants. *Annales d'Hygiène Publique et Médico-Légales*, **13**, 361–398.

RÉSUMÉ

French abstract not available at time of publication.

RESUMEN

Objetivo: El objetivo de este estudio era demostrar la utilidad de la MRI cerebral para detectar posible maltrato infantil en niños con hallazgos neurológicos inexplicables.

Método: Entre los años 1990 y 1997, 208 niños fueron derivados por sospechas de maltrato físico a la Unidad de Protección Infantil del Hospital Ste-Justine, un hospital pediátrico de atención terciaria. Entre ellos, 39 niños se presentaron inicialmente con signos neurológicos. Para 27 de ellos, los resultados del CTS sugirieron hacer el diagnóstico de maltrato infantil. Sin embargo, en 12 niños, incluso cuando se llevó a cabo el CTS, el diagnóstico y/o los mecanismos del trastorno neurológico no quedaron claros. La investigación se completó con un estudio de MRI en 12 casos.

Resultados: Las hallazgos de MRI fueron motivo de diagnóstico en 8 casos. En dos casos más se llegó al diagnóstico de maltrato infantil combinando los hallazgos de la exploración de esqueleto y de MRI. En un caso, el estudio de MRI sugirió un diagnóstico de maltrato infantil pero no pudo ser confirmado. Un caso fue malinterpretado como normal.

Conclusiones: El MRI es el test de elección para descartar maltrato infantil cuando nos encontramos con un niño que presenta signos neurológicos inexplicados, que hayan durado varios días. El hecho de que el MRI pueda diferenciar mejor datos de diferentes edades hace que este test de imagen sea particularmente útil para identificar casos de maltrato infantil. Estos resultados, sin embargo, siempre deben ser integrados en una aproximación clínica multidisciplinaria bien conducida.