



ELSEVIER

Journal of the Neurological Sciences 163 (1999) 70–73

Journal of the
**Neurological
Sciences**

Akinetic mutism and mixed transcortical aphasia following left thalamo–mesencephalic infarction

Nages Nagaratnam*, Catriona McNeil, J.S. Gilhotra

Blacktown-Mount Druitt Health, Blacktown, NSW 2148, Australia

Received 26 May 1998; received in revised form 3 November 1998; accepted 14 December 1998

Abstract

A 54-year-old man developed somnolent akinetic mutism and acute mixed transcortical aphasia following a left thalamo–mesencephalic infarction. He also exhibited behavioural changes, namely apathy, slowness, lack of spontaneity, disinhibition, perseveration, gait apraxia and incontinence consistent with frontal lobe dysfunction. Presumably the akinetic mutism and language dysfunction were due to the thalamic stroke. All the manifestations could be related to interruption of the frontal-subcortical circuitry. © 1999 Elsevier Science B.V. All rights reserved.

Keywords: Thalamo–mesencephalic infarction; Frontal-like syndrome; Frontal-subcortical circuitry

1. Introduction

A number of clinical syndromes have been described with thalamic lesions depending on the size and location. They not only result from within or around the lesion but may embrace clinical features of a more widespread anatomic involvement. Language disorders together with non-linguistic behavioural abnormalities have occurred prominently with lesions of left subcortical structures [14]. According to Brown [8] there are two broad classes of behavioural manifestations associated with unilateral left thalamic lesions, one showing akinetic mutism often developing into a stuporous state and the other with a fluent-type of speech disorder.

Cairns et al. [9] described a young female with a cyst in the third ventricle with inability to speak and to move but who could react adequately to external stimuli. Since then akinetic mutism had been anatomically categorised into two forms namely frontal and mesencephalic, and furthermore on their clinical appearances, ‘hyperpathic’ akinetic mutism following bilateral frontal damage and ‘somnolent’ or ‘apathetic’ akinetic mutism to mesencephalic location [32].

Mixed transcortical aphasia is an unusual manifestation of stroke. It is characterised by a non-fluent aphasia with impaired comprehension, impaired naming with or without echolalia with reading and writing to dictation without understanding but with good repetition. It could result from lesions in a number of anatomical sites [5,6,19,24,25,30]. A wide range of behavioural alterations have been linked to frontal lobe dysfunction. This may result not only from damage to the frontal lobe but has also been observed with lesions in other parts of the brain [31,33]. There have been only a few reports emphasising the possibility of frontal lobe dysfunction as a prominent disturbance in thalamic stroke [7,31]. We wish to report on a patient with akinetic mutism (AM) and mixed transcortical aphasia (MTA) together with other behavioural manifestations, presumably due to frontal lobe dysfunction following a left mesencephalo–thalamic infarction.

2. Case report

OJ, a 54-year-old dextral English and Arabic speaking male of Syrian extraction, a retired engineer presented with drowsiness, blurred vision and numbness of the left half of

*Corresponding author. Tel.: +61-2-9830-8000; fax: +61-2-9830-8020.

the body of sudden onset. He gave a history of hypertension. On admission he was found to be extremely drowsy with low output of speech, described below. He had a regular heart rate and there was no evidence of cardiac decompensation. Initial evaluation of the nervous system revealed third nerve palsies with complete ptosis on the right and incomplete on the left. He had minimal weakness of all four limbs with hyperreflexia, ankle clonus and extensor plantar response on the right. Sensory function could not be ascertained as he was a poor sensory witness. He could walk with the help of two persons and veered to the left with an ataxic gait and had a tendency to fall backwards. He lacked spontaneity with perseveration of movements.

Routine haematological and biochemical tests were normal. The CT scan showed a hypodense area in the region of the left thalamus and midbrain bilaterally consistent with an infarction (Fig. 1). On subsequent days it was noticed that his level of attention fluctuated and he slept most of the time and occasionally fell into an unarousable sleep. He was impulsive at times and could not remain still, with inappropriate sexual behaviour masturbating frequently. Because of the language disorder, formal memory testing was not possible. He was doubly incontinent.

During the next three months he remained hypokinetic and slept up to several hours during the day. Verbal and motor spontaneity were reduced. He had to be fed. His ability to communicate fluctuated from reduced speech to mutism and hypophonia. At four weeks post-onset his expressive speech was almost completely unintelligible. He was able to answer yes/no verbally but needed prompting to speak. He was unable to name objects even with prompting but could repeat. He was dysarthritic. Auditory comprehension, yes/no was 75% reliable with some Arabic translation. He appeared to follow simple sentences. He was able to point to objects by name but had more difficulty with functions. He had moderate to severe aphasic receptivity. In short he had moderate to severe

receptive, expressive and word-finding difficulties together with decreased articulatory agility.

A month later, the Aphasia Language Performance Scales (ALPS), the listening subtest score was 3/10. He was able to comprehend and follow simple directions but comprehension broke down at two and three step commands. Talking was 2/10 and he was able to repeat vowels after the clinician's model but was unable to count a previous model and could not name simple objects. The phonation was quiet. The reading subtest was 2/10 and he was able to read name and single digits with comprehension but was unable to comprehend single body part names or a short phrase. Writing was 0/10. He was unable to copy a circle and could not trace it even with the clinician's assistance. Three pictures of common objects (toilet, water and chair) were introduced and he was unreliable in pointing to a choice of these three pictures. At the end of four months he had shown no significant recovery in the different linguistic functions with persistent impairments of behaviour.

3. Discussion

This patient presented with a left thalamo–mesencephalic infarction. The blood supply to the thalamus is complex and variable and this the reason why paramedian thalamic infarctions are usually accompanied by more extensive infarcts in the thalamus and midbrain [21] and are rarely isolated [10]. At the midbrain level the mesencephalic grey matter and the principal nucleus and the fibres of the third nucleus are affected in more than 75% of cases [10]. Some bilateral thalamic infarcts involved the midbrain only on one side and vice versa as in the patient described. There are several variations of the mesencephalo–thalamic syndrome. They include the Parinaud syndrome, unilateral or bilateral third nerve palsies or selective downward gaze paralysis associated with hypersomnolence and impairment of memory [21,23].

Our patient's findings were that of that of somnolent akinetic mutism of the mesencephalic type and this state can vary in its intensity [32]. Initially he was drowsy and was hypersomnolent with reduction in verbal and motor spontaneity and speech reduced to mutism. He also exhibited other behavioural manifestations such as apathy, lack of spontaneity, perseveration, disinhibition, incontinence and gait dyspraxia suggesting frontal lobe dysfunction. AM has been reported with thalamic lesions [11,17] and clearly AM is typically associated with other frontal signs despite the fact that AM has been more typically associated with bilateral anterior cingulate lesions [1,3,18,26]. It had been reported following bilateral globus pallidus lesions [15,20] bilateral subcortical paramedian diencephalic and midbrain lesions [9] and bilateral thalamo–capsular lesions [27].

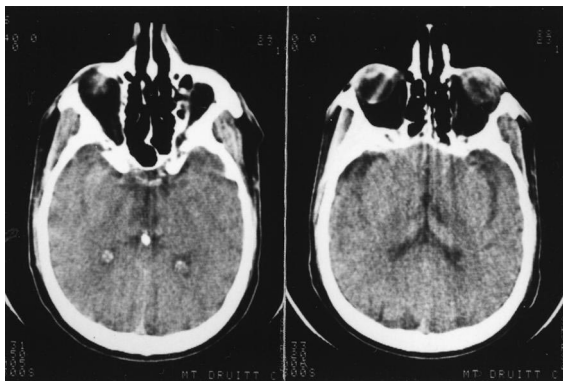


Fig. 1. CT scan showing a hypodense area in the midbrain (↖) and the left thalamus (↖) consistent with infarction.

The patient's language deficits fluctuated and were characterised by impairment of comprehension, non-fluency, anomia, nonperseveration of reading and writing. There was retention of the ability to repeat, a characteristic of transcortical aphasias. Mixed transcortical aphasia results from diffuse brain processes [13] with recurrent strokes [6], left anterior cerebral artery infarction [30], frontal lobe infarction [29] and subcortical lesions such as thalamic [19], putaminal [5,24] and in the superior periventricular white matter [25].

The mechanism of thalamic aphasias is still controversial [22]. Weisberg [34] described five patients with left-sided thalamic haemorrhage who were aphasic and exhibited mixed sensory and motor features with paraphasias, word-finding errors, impaired articulation with intact repetition features consistent with transcortical aphasia. Kawahara et al. [16] described a case with left-sided haematoma of the dorsal thalamus with aphasia of the mixed transcortical type. According to Alexander and LoVerme [2] in cases of thalamic lesions causing aphasia there is a likelihood of a more widespread involvement of the surrounding subcortical and cortical structures. They embrace a wide variety of subcortical syndromes. The clinical picture however is reasonably consistent. There is in the early stages a partial or complete mutism with various disturbances of language dysfunction, expression, comprehension or both but repetition is well preserved [19].

Initially the patient exhibited mutism and was hypophonic. Hypophonia and dysarthria have been noted following thalamotomy [4]. Bell [4] noted diminished verbal output, paraphasia, perseverations, difficulty in naming, a relative retention of comprehension, a normal ability to repeat together with decreased volume and dysarthria following ventrolateral thalamotomy. The articulatory disorders are very much related to lesions in all relevant subcortical structures [14] and are often severe with poor recovery [14] like in the case we report. It is reasonable to conclude that the AM and MTA in our patient were due to the thalamic stroke.

Our patient remained hypokinetic for more than two months with verbal and motor spontaneity decreased, together with perseveration at the level of single actions, non-motivation and lack of social restraint. He masturbated without shame as did the patient described by Park-Matsumoto et al. [27] who also had erotic delusions. They described a man with neuro-Behcet disease who developed mutism and neuro-imaging with CT and MRI showed bilateral thalamo-capsular lesions and it was postulated that the mutism was the result of frontal lobe dysfunction due to disconnection of the thalamo-cortical fibres from the thalamus to the frontal cortex.

Linking the frontal lobe and the subcortical structures are a series of parallel frontal-subcortical circuits [12], and behavioural changes have been attributed to interruption of these. Three prefrontal-subcortical circuits are associated

with three distinct frontal lobe neurobehavioural syndromes [12]. Irritability, tactlessness, alteration in interest are some of the features associated with the orbito-frontal syndrome. The anterior cingulate syndrome displays akinetic mutism, asportaneity, incontinence and lack of emotion. The dorsolateral prefrontal mediates executive behaviour and is characterised by reduced verbal and nonverbal fluency, poor recall and perseveration amongst others.

In our patient it is very likely there has been an interruption of the frontal projections from the mesencephalic–diencephalic reticular activating system which includes the midbrain, reticular formation, thalamus and hypothalamus [27,28,32]. The akinetic mutism, the mixed transcortical aphasia, the speech abnormalities and other behavioural characteristics in this patient could be explained by frontal lobe dysfunction resulting from a thalamo–mesencephalic-cortical disconnection.

References

- [1] Amyes EW, Neilson JM. Bilateral anterior cingulate gyrus lesions. *Bull Los Angeles Neuro Sci* 1953;18:48–57.
- [2] Alexander MIP, LoVerme Jr. SR. Aphasia after left hemispheric intracerebral haemorrhage. *Neurology* 1980;30:193–202.
- [3] Barris RW, Schuman HR. Bilateral anterior cingulate gyrus lesions. *Neurology* 1953;3:44–52.
- [4] Bell DS. Speech functions of the thalamus inferred from the effects of thalamotomy. *Brain* 1968;91:619–38.
- [5] Berthier ML, Starkstein SE, Leiguardia R, Ruiz A, Mayberg HS, Wagner H, Price TR, Robinson RG. Transcortical aphasia; importance of non-speech dominant hemisphere in language repetition. *Brain* 1990;113:631–41.
- [6] Bogousslavsky J, Ferrazzi NIM, Regli F, Assal G, Tanabe H, Delaloye-Bischof A. Manic delirium frontal-like syndrome with paramedian infarction of the right thalamus. *J Neurol Neurosurg Psychiatry* 1988;51:116–9.
- [7] Bogousslavsky J. Frontal stroke syndromes. *Eur Neurol* 1994;34:306–15.
- [8] Brown JW. Language cognition and the thalamus. *Confin Neurologica* 1979;36:35–60.
- [9] Cairns H, Oldfield HC, Pennybaker JB, Whineridge D. Akinetic mutism with an epidermoid cyst of the third ventricle. *Brain* 1941;34:273–90.
- [10] Castaigne P, Lhermitte F, Buge A, Escourolle R, Hauw JJ, Lyon-Caen O. Paramedian thalamic and midbrain infarcts: clinical and neuropathological study. *Ann Neurol* 1980;10:127–48.
- [11] Cravioto H, Silberman J, Fergin IA. A clinical and pathologic study of akinetic mutism. *Neurology* 1960;17:74–80.
- [12] Cummings JL. Frontal-subcortical circuits and human behaviour. *Arch Neurol* 1993;50:873–80.
- [13] Geschwind N, Quadfasel FA, Segarra JM. Isolation of the speech area. *Neuropsychologia* 1968;6:327–40.
- [14] Glosser G, Kaplan E, LoVerme S. Longitudinal neuropsychological report of aphasia following left subcortical haemorrhage. *Brain Lang* 1982;15:95–116.
- [15] Hawker K, Lang AF. Hypoxic-ischaemic damage of the basal ganglia. *Mov Disord* 1990;5:219–24.
- [16] Kawahara N, Sato K, Murak M, Tanaka K, Kaneko M, Uemura K. CT classification of small thalamic haemorrhages and their clinical implications. *Neurology* 1986;30:65–172.

- [17] Kemper TL, Romanul FCA. State resembling akinetic mutism in basilar artery occlusion. *Neurology* 1967;17:74–80.
- [18] Laplane D, Degos JD, Baulac M, Gray F. Bilateral infarction of the anterior cingulate gyrus and of the fornices. *J Neurol Sci* 1981;51:289–300.
- [19] McFarling D, Rothi LJ, Heilman KM. Transcortical aphasia from ischaemic infarcts of the thalamus. Report of two cases. *J Neurol Neurosurg Psychiatry* 1982;45:107–12.
- [20] Mega MS, Cohenour RC. Akinetic mutism: disconnection of frontal subcortical circuits. *Neuropsychiatry Neuropsychol Behav Neurol* 1997;10:254–9.
- [21] Meissner I, Sapir S, Kokmen E, Stein SD. The paramedian diencephalic syndrome: a dynamic phenomenon. *Stroke* 1987;18:380–5.
- [22] Mohr JP, Watters WC, Duncan GW. Thalamic haemorrhage and aphasia. *Brain Lang* 1975;2:3–17.
- [23] Nagaratnam N, Goughassian DF, Mugridge V. Syndrome of downward gaze palsy, amnesia and hypersomnolence. *Postgrad Med J* 1989;65:840–2.
- [24] Nagaratnam N, Gilhotra JS. Acute mixed transcortical aphasia following an infarction in the left putamen. *Aphasiology* 1998;12:489–93.
- [25] Nagaratnam N, Barnes R. Language dysfunction in white matter lesions without significant hemiparesis. *J Neurol Rehab* 1996;10:253–6.
- [26] Nemeth G, Hyedus K, Molnar L. Akinetic mutism associated with bicingular lesions: a clinicopathological and functional anatomic correlates. *Eur Arch Psychiatry Neuro Sci* 1988;237:218–22.
- [27] Park-Matsumoto YC, Ogawa K, Tazawa T, Ishiai S, Tei H, Yuasa T. Mutism developing after bilateral thalamo–capsular lesions by neuro-Behcet disease. *Acta Neurol Scand* 1995;91:297–301.
- [28] Plum F, Posner YB. in: *Diagnosis of stupor and coma*, F.A.Davis, Philadelphia, 1972, pp. 23–4.
- [29] Rapsack SZ, Krupp LB, Rubens AB, Reim MJ. Mixed transcortical aphasia without isolation of the speech area. *Stroke* 1990;21:953–6.
- [30] Ross ED. Left medial parietal lobe and receptive language functions; mixed transcortical aphasia after left anterior cerebral infarction. *Neurology* 1980;30:144–50.
- [31] Sandson TA, Daffner KR, Carvalho PA, Meslman MM. Frontal lobe dysfunction following infarction of the left-sided medial thalamus. *Arch Neurol* 1991;8:1300–3.
- [32] Segarra JM. Cerebral vascular disease and behaviour. I. The syndrome of the mesencephalic artery. *Arch Neurol* 1970;22:408–18.
- [33] Strub RL. Frontal lobe syndrome in a patient with bilateral globus pallidus lesion. *Arch Neurol* 1989;46:1024–7.
- [34] Weisberg LA. Thalamic haemorrhage: clinical-CT correlation. *Neurology* 1986;36:1382–6.