

Localized scleroderma associated with progressing ischemic stroke

Naomi Kanzato^{a,*}, Toshio Matsuzaki^b, Yukihiro Komine^c, Mineki Saito^b, Akiko Saito^b,
Taku Yoshio^d, Masahito Suehara^a

^aDepartment of Neurology, National Okinawa Hospital, Ganeko 3-20-14, Ginowan-shi, Okinawa 901-2214, Japan

^bThird Department of Internal Medicine, Kagoshima University, Kagoshima, Japan

^cThird Department of Internal Medicine, Ryukyus University, Okinawa, Japan

^dDepartment of Clinical Immunology, Jichi Medical School, Jichi, Japan

Received 30 March 1998; received in revised form 14 August 1998; accepted 14 August 1998

Abstract

We present a 73 year-old Japanese woman with localized scleroderma involving the right side of the scalp accompanied by continuous tingling pain, who developed insidiously progressive left hemiparesis. In magnetic resonance imaging of the brain, an infarct first appeared in the watershed region of the right middle cerebral artery territory and subsequently extended to deep white matter accompanied by scattered hemorrhages. Focal stenosis in the M2 portion of the right middle cerebral artery was revealed on magnetic resonance angiography, and the distal vessels were only shown faintly. A biopsy specimen from the sclerotic scalp lesion showed obvious thickening of vessel walls and mild mononuclear cell infiltration. We believe that the progressing ischemic stroke was caused by hemodynamic disturbances from localized sclerotic obstruction of the middle cerebral artery, with an autoimmune pathogenesis. © 1999 Published by Elsevier Science B.V. All rights reserved.

Keywords: Localized scleroderma; Cerebral infarction; Central nervous system vasculitis; Anti-endothelial cell antibody

1. Introduction

Systemic sclerosis (SS), a progressive multiorgan disorder, involves mainly the skin, joints, lungs, heart and kidneys, as well as other sites. Localized scleroderma (LS) is confined to the skin. In both SS and LS, primary sclerodermal involvement of cerebral vessels is exceedingly rare, possibly due to the paucity of adventitial fibrous tissues and limited fibrous elements in the normal media [7]. Only a few reports have described the histopathology of cerebral arteries in LS [5,9]; these have noted thickened sclerotic vessel walls but no vascular inflammation or fibrinoid degeneration.

We describe an elderly woman with sclerotic scalp and associated pain who insidiously developed hemiparesis. This ischemic stroke progressed over a few months, accompanied by foci of hemorrhage.

2. Case report

A 73 year-old, right-handed Japanese woman insidiously developed severe tingling pain, erythema and hair loss over the right side of the scalp from September 1995. She noted mild paresis in her left arm from November, then came to our outpatient clinic. We confirmed these findings, but magnetic resonance imaging (MRI) of the brain and cervical spinal cord were not contributory. By January 1996 she had developed complete palsy of the left arm with arthralgia and edema, and also mild paresis in the left

*Corresponding author. Tel.: +81-98-898-2121; fax: +81-98-897-9838.

leg. On admission in February, she had left supranuclear facial paresis.

On admission, she was alert and normotensive, with normal cardiac rhythm and body temperature. A regional sclerotic skin lesion accompanied by erythema and hair loss was noted extending from the right forehead to the parietal scalp (Fig. 1), where the patient felt continuous tingling pain. No swelling or tenderness over the temporal artery was apparent. Examination of the eye was normal, and no bruit was evident on the neck. Diffuse hyperpigmentation was noted over her trunk and extremities. Left hemiparesis including her left face was noted. In her paralyzed left arm, dysesthesia and painful joints with swelling and increased skin temperature were noted, which were considered to be shoulder-hand syndrome. Deep tendon reflexes were brisk except for the right arm. No pathologic reflexes were seen.

Results of routine hematologic and other laboratory tests showed eosinophilia ($1360/\text{mm}^3$; normal $<500/\text{mm}^3$), decreased platelets ($3.0 \times 10^4/\mu\text{l}$; normal $15\text{--}40 \times 10^4/\mu\text{l}$), slightly increased erythrocyte sedimentation rate, and elevated C-reactive protein. Elevated serum IgA (1090 mg/dl; normal 115–440 mg/dl) was evident, but an M protein was not detected. Anti-topoisomerase I antibody (Scl-70) was elevated slightly, and antinuclear antibody showed a speckled pattern. Antimitochondrial antibody was markedly increased (>320 ; normal <20) with a nonspecific immunofluorescence pattern, but the antimitochondrial M2 antibody was negative. A serologic test for syphilis was negative. Coagulation tests including activated partial thromboplastin time (APTT) and levels of antithrombin III (AT III) were normal. Tests for lupus anticoagulant and anticardiolipin antibody were negative.

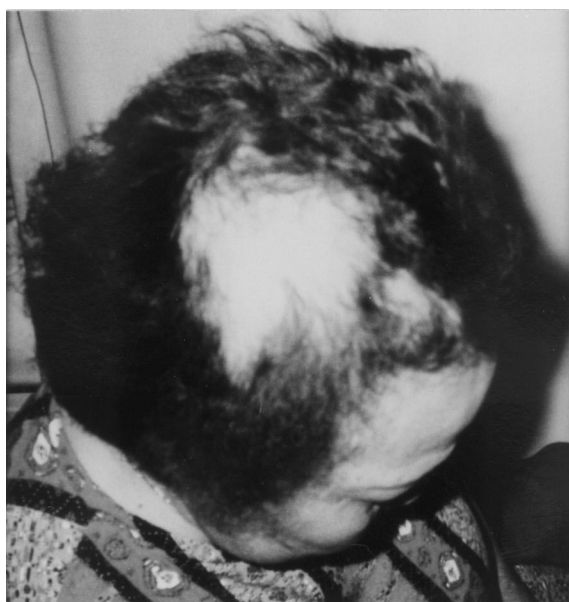

Fig. 1. Bandlike sclerotic lesion with erythema and hair loss extending from the right forehead to the parietal scalp.

Other serum biochemical tests and a urinalysis were all normal. Cerebrospinal fluid (CSF) examination revealed a slightly elevated opening pressure (225 mm H₂O) and myelin basic protein (4.9 ng/ml; normal <4 ng/ml), but other constituents such as cells and protein were normal. Oligoclonal IgG bands were not detected. Bone marrow findings included a slightly elevated proportion of plasma cells (3.7%, normal 0.3–1.5%). No pulmonary fibrosis was seen in radiographs of the chest, and no intracardiac thrombosis was evident in the echocardiogram. Electroencephalography, nerve conduction, and needle EMG were normal.

Anti-endothelial cell antibodies (AECA) were examined by cellular ELISA methods [11] using an antigen from cultured human vein endothelial cells (HUVEC). The patient's serum contained normal levels of both the IgM-AECA and IgG-AECA, the CSF contained significantly elevated levels of IgM-AECA (16.5 CSF unit/ml; normal, 0.8 ± 0.7) and IgG-AECA (5.8 CSF unit/ml; normal, 1.1 ± 0.9).

In a biopsy specimen from the right parietal scalp involving LS, erosive change with loss of epidermis was noted, together with swelling of connective tissues. Arteriolar lumens were narrowed by mural thickening with excessive numbers of collagen fibers. Mild mononuclear cell infiltration was present without amyloid deposition (Fig. 2).

MRI of the brain repeated on admission revealed lesions with high signal intensity in the right middle cerebral artery (MCA) territory, especially in the watershed region, in T2- and proton-weighted images (Fig. 3a). In T1-weighted images, multiple enhancements were evident within the cortical branches and the lenticulostriate branch of MCA by administration of gadolinium-DTPA (Fig. 3b,c). Magnetic resonance angiography (MRA) revealed focal stenosis at the insular portion (M2) of the right

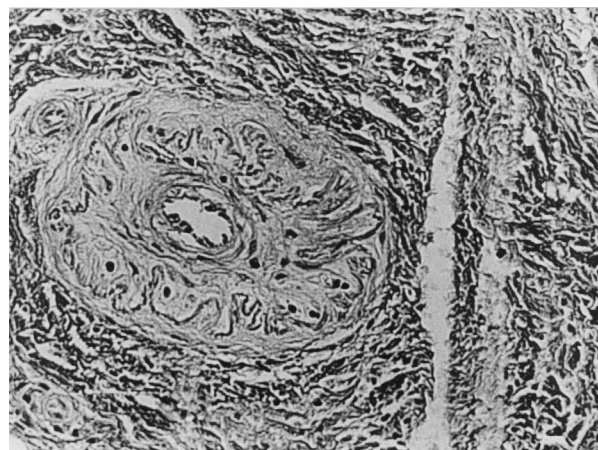


Fig. 2. Arteriolar lumens were narrowed by mural thickening with excessive numbers of collagen fibers accompanying mild mononuclear cell infiltration (Masson trichrome stain, $\times 40$).

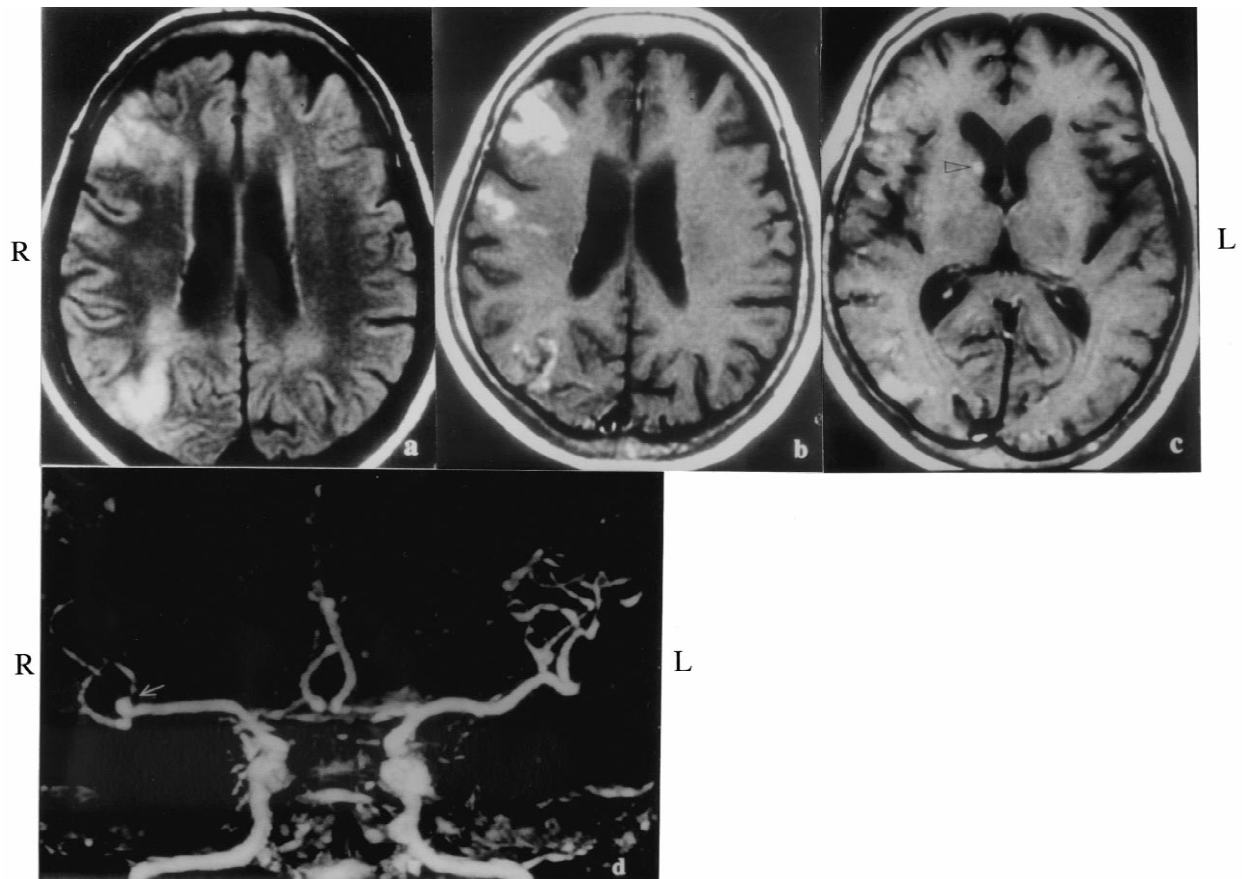


Fig. 3. MRI and MRA in February 1996: (a) proton-weighted (TR 2000/TE 40); (b) and (c) Gd-DTPA T1-weighted (TE 500/TE 20) image of spin echo sequences; (d) MRA. Ischemic changes were evident at the watershed region of the right MCA. Gd-enhancements were apparent within the region of cortical branches and lenticulostriate branch (Δ) of right MCA. MRA revealed focal stenosis of the M2 insular portion of the right MCA (\rightarrow), and obscure images of distal arteries.

MCA, and the distal arteries were poorly visualized (Fig. 3d).

We carried out hypervolemic hemodilution for the therapy of hemodynamic ischemia [1] with low molecular weight dextran solution for 2 weeks, but the head pain and left hemiparesis continued. Then we followed with oral prednisolone (30 mg/day) and intramuscular dexamethasone (1 mg/day) administration for 1 month, which relieved the paresis of the left face and leg, concurrently with the disappearance of continuous head pain and LS of the scalp. MRI of the brain was conducted after a course of steroid therapy, T2- and proton-weighted images showed an extensive lesion of high signal intensity in the deep white matter of the right MCA territory, accompanied by old scattered hemorrhages with low intensity. In conjunction with these findings, T1-weighted images revealed linear lesions of high intensity just beneath the cortex (Fig. 4a,b).

We treated her shoulder–hand syndrome with stellate ganglion blockade weekly for 4 weeks, and her joint pain and edema markedly decreased, although the paresis of the left arm accompanied with joint contractures in a Wernicke-Mann posture remained.

3. Discussion

The patient was diagnosed with LS based on the findings of a characteristic sclerotic lesion of the scalp [8], diffuse hyperpigmentation, and serum autoantibodies associated with scleroderma, but without visceral involvement.

Her left hemiparesis appeared insidiously and evolved over a few months. MRA findings of this case lacked the disease specificity for vasculitis, we could not distinguish it from the atherosclerotic lesion based solely on these findings [6]. However, MRI findings failed to show common atherosclerotic thrombosis or embolism, because of the insidious evolution of the infarct from the watershed region to the deep white matter accompanied by scattered enhancements and hemorrhages within the right MCA territory. We concluded that this atypically progressing ischemic stroke was most likely caused by a progressive hemodynamic process, arising from vulnerability to low perfusion at the proximal stenotic region demonstrated by MRA.

AECA have been demonstrated in serum as a pathogenesis of vasculitic organ damage in some connective tissue disease such as systemic lupus erythematosus and

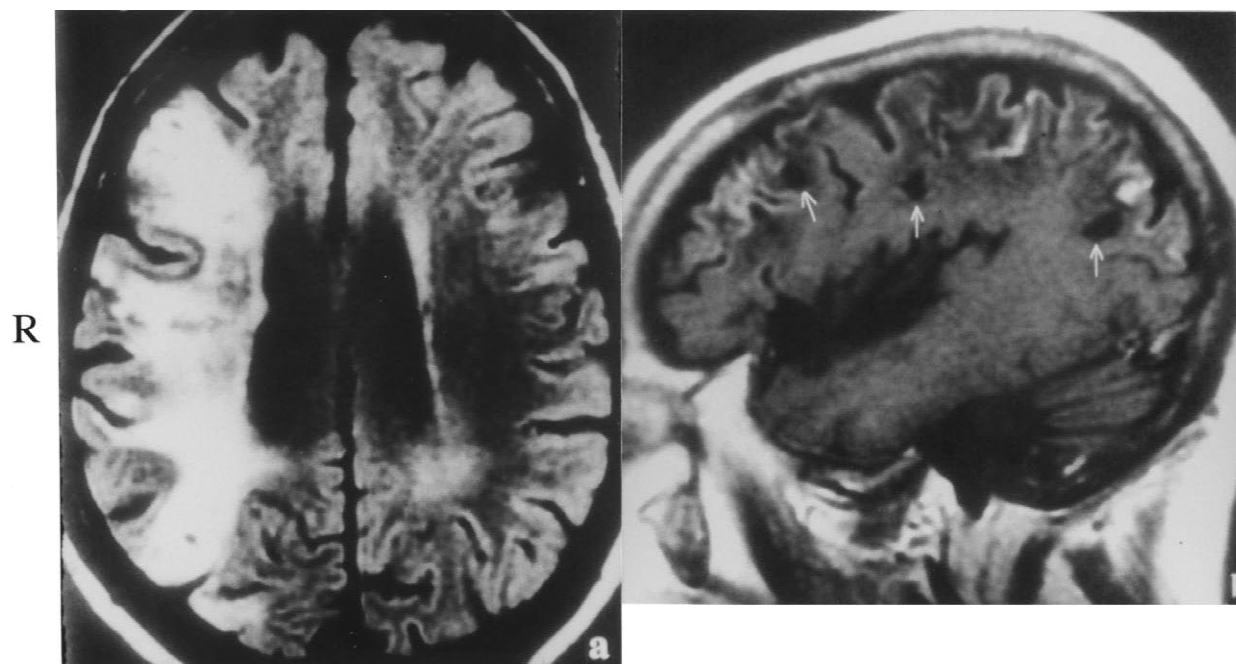


Fig. 4. MRI after the corticosteroid therapy in April 1996: (a) proton-weighted; (b) non-enhanced T1-weighted image. A high-intensity lesion had evolved to the deep white matter within the right MAC territory, in conjunction with old scattered hemorrhages of low intensity. T1-weighted images revealed linear intensity lesions just beneath the cortex.

SS [2]. Intrathecal AECA production was demonstrated in our case for the first time in LS, which supported an autoimmune pathogenesis of cerebrovascular injury in this case.

Most curiously, the ischemic cerebral infarction in this case occurred just subjacent to the LS lesion of the scalp. Chung et al. [5] and Lüer et al. [10] postulated that vascular dysgenesis may be underlying in the progressive gliosis of cerebral parenchyma just under an LS scalp lesion. Endothelial cell damage is believed to be the primary event in LS [3], following fibrotic change triggered by disordered regulation of genes affecting collagen formation [4]. LS is much less severe and carries a more favorable prognosis than SS, but associated vascular events may limit the functional outcome. Better understanding of the pathogenesis of LS should facilitate the tailoring of therapy in response to key events in the evolution of the disease.

References

- [1] Adams HP, Brott TG, Crowell RM. Guidelines for the management of patients with acute ischemic stroke. *Circulation* 1994;90:1588–601.
- [2] Baguley E, Hughes GRV. Antiendothelial cell antibodies. *J Rheumatol* 1989;16:716–7.
- [3] Black CM. The aetiopathogenesis of systemic sclerosis. *J Int Med* 1993;234:3–8.
- [4] Black CM, Denton CP, Korn JH, Crombrughe B. Systemic sclerosis: Current pathogenetic concepts and future prospects for targeted therapy. *Lancet* 1996;347:1453–8.
- [5] Chung MH, Sum J, Morrell MJ, Horoupian DS. Intracerebral involvement in scleroderma en coup de sabre: Report of a case with neuropathological findings. *Ann Neurol* 1995;37:679–81.
- [6] Fieschi C, Rasura M, Anzini A, Beccia M. Central nervous system vasculitis. *J Neurol Sci* 1998;153:159–71.
- [7] Gordon RM, Silverstein A. Neurologic manifestations in progressive systemic sclerosis. *Arch Neurol* 1970;22:126–34.
- [8] Jablonska S, Lovell CR. Localized scleroderma. In: Jayson MIV, Black CM (Eds.), *Systemic Sclerosis: Scleroderma*, Wiley: Chichester, 1988:303–318.
- [9] Lee JE, Haynes JM. Carotid arteritis and cerebral infarction due to scleroderma. *Neurology* 1967;17:18–22.
- [10] Lüer W, Jockel D, Henze T, Schipper HI. Progressive inflammatory lesions of the brain parenchyma in localized scleroderma of the head. *J Neurol* 1990;237:379–81.
- [11] Yoshio T, Masuyama J, Sumiya M, Minota S, Kano S. Antiendothelial cell antibodies and their relation to pulmonary hypertension in systemic lupus erythematosus. *J Rheumatol* 1994;21:2058–63.