

Hemangioma calcificans

Case report of an intraparenchymatous calcified vascular hematoma with epileptogenic potential

MICHAEL V. DiTULLIO, JR., M.D., AND W. EUGENE STERN, M.D.

Department of Surgery, Division of Neurosurgery, University of California at Los Angeles School of Medicine, Los Angeles, California

✓ A middle-aged woman, with a previous history of medically suppressed absence attacks, presented with mild changes in mental status and a skull film demonstrating several areas of mottled, granular, intracranial calcifications. These lesions, although readily visible on computerized tomography, appeared avascular during the course of cerebral angiography. At the time of surgery the masses, which were densely calcified and generally circular, demonstrated numerous areas of superficial, white, verrucous excrescences. Microscopic, pathological evaluation confirmed the diagnosis of hemangioma calcificans. The literature describing this rare entity is briefly reviewed.

KEY WORDS • hemangioma calcificans • intraparenchymatous calcification • cavernous hemangioma • calcified hamartoma • seizure

IN view of the potential pathological etiologies, it is evident that the identification of radiologically significant intracranial calcifications, whether single or multifocal, may present a diagnostic and therapeutic dilemma. A patient who was admitted to our hospital with several ossifying vascular hamartomas, at least one of which demonstrated epileptogenic potential, is a case in point. The first example of such an occurrence was reported in 1890, when Bremer and Carson² described a 23-year-old man with a similar lesion in the right Sylvian fissure. However, the clinical syndrome and pathological entity were not well defined until 1948, when Penfield and Ward⁶ reported five additional cases of characteristically calcified vascular tumors that they subsequently classified as hemangiomas calcificans. It was their impression that although the lesions were neither neoplasms nor malformations, they appeared capable of autonomous differentiation. Subsequent reports by Shafey, *et al.*,⁹ and Runnels, *et al.*,⁷ adding two more cases to the literature, have tended to confirm Penfield and Ward's previous observations.

The rarity of this pathological lesion is emphasized by the fact that only eight cases have been reported in the previous neurosurgical literature. Our patient represents the first example of multiple lesions of this type.

Case Report

This 59-year-old woman was in generally good health until March, 1976, when she accidentally fell and injured her right occipital region. Although there was no associated loss of consciousness, she complained of headache and transient blurred vision. When examined by her personal physician, the patient was described as neurologically intact. A routine screening skull series demonstrated two abnormal areas of mottled calcification (Fig. 1), one occupying the greater portion of the right middle fossa and the other localized to the midline just above the optic chiasm. Despite a negative technetium brain scan, these findings were later verified by computerized tomography (CT), which also showed similar lesions in the left occipital lobe and high right frontoparietal region (Fig. 2). Because of the patient's asymptomatic course, a period of careful observation was pursued, and during the subsequent 20 months serial scans raised the possibility of subtle enlargement of certain of these lesions.

In November, 1977, the patient was referred to UCLA Hospital by Dr. Avner I. Feldman for further evaluation. Further delineation of the patient's history revealed that during her 30's she suffered from some form of absence attacks. These episodes, which were

Hemangioma calcificans

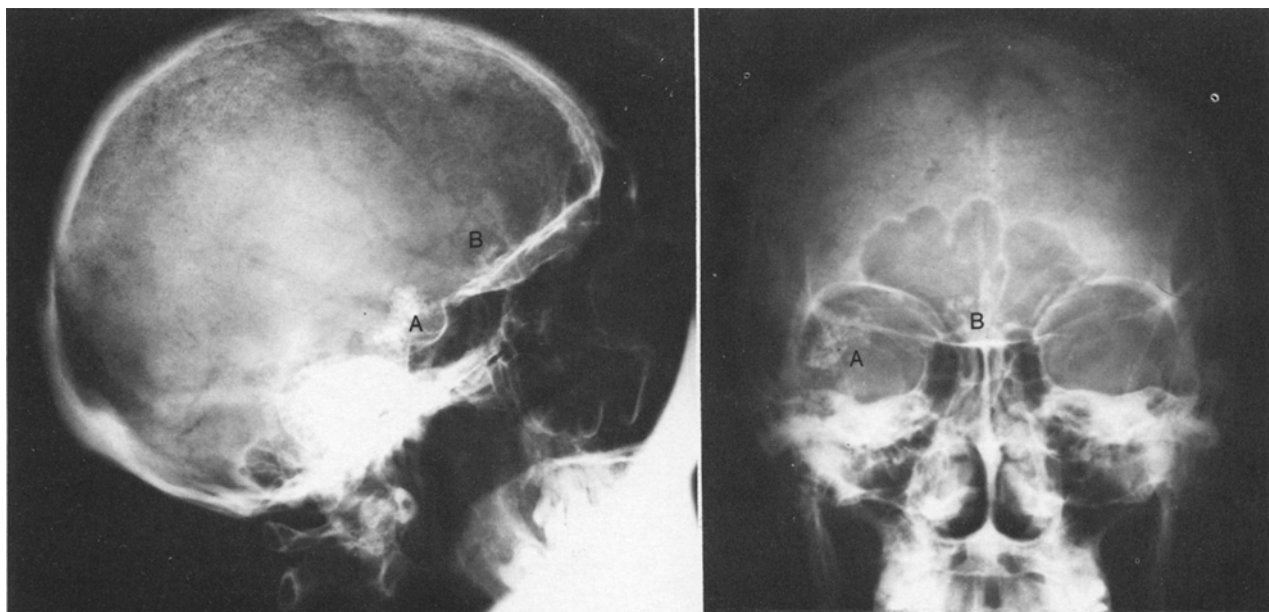


FIG. 1. Plain skull films, right lateral view (*left*) and anteroposterior view (*right*), demonstrating areas of calcification in the right middle fossa (A) and in the midline just above the area of the optic chiasm.

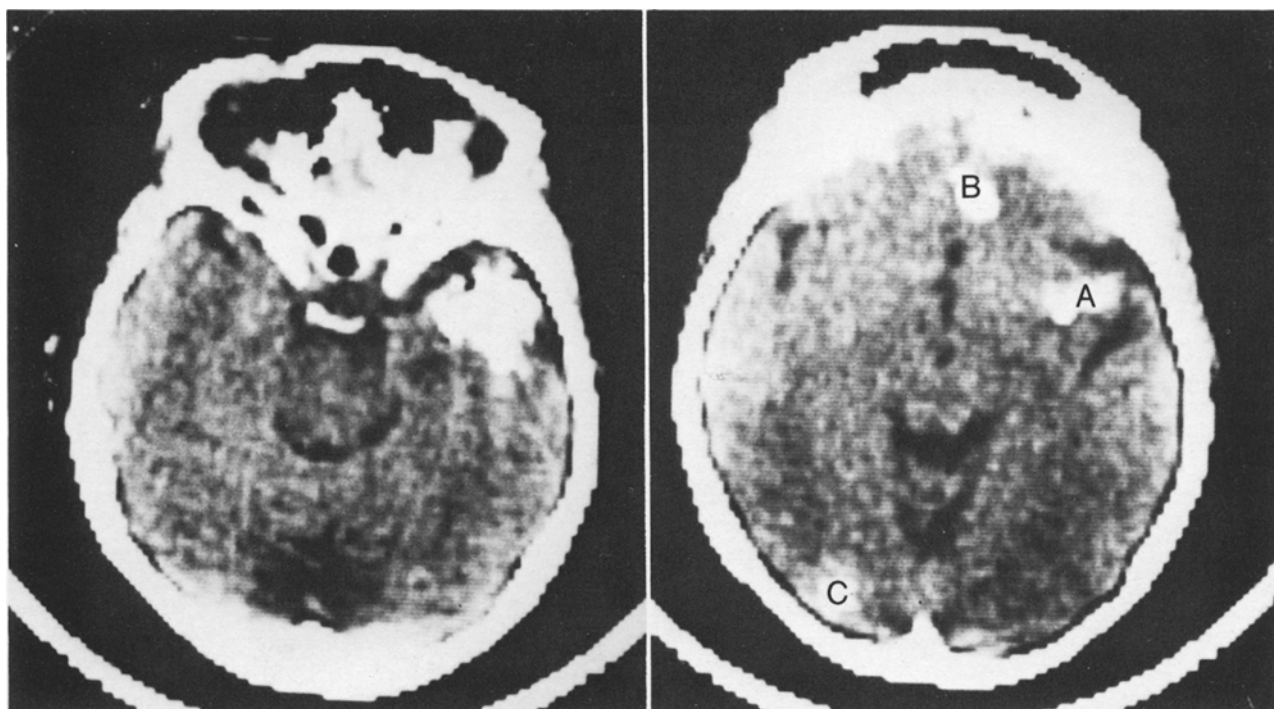


FIG. 2. Uninfused computerized tomograms. *Left*: Scan depicting a large calcified lesion in the anterior portion of the right temporal lobe. There is no evidence of edema in the surrounding tissue. *Right*: Scan taken at a higher level. The top of the initial lesion (A) is still evident in the region of the right middle fossa. Similar calcified hamartomas are seen on the medial aspect of the right frontal (B) and left occipital lobes (C). Despite the multiplicity of lesions, there is no evidence of any mass effect.

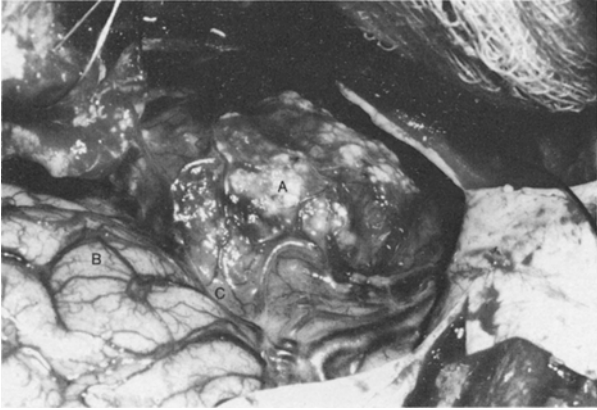


FIG. 3. Operative photograph of the surgical specimen *in situ*. This calcified lesion of the right anterior temporal lobe was covered by a thin gliotic rind of transparent cortical tissue, through which could be seen several white verrucous excrescences (A), the opercular region of the right frontal lobe (B), and the Sylvian fissure (C).

abrupt in onset, occurred several times each week, lasted 5 to 10 seconds, and were not associated with tongue biting, tonic-clonic activity, or incontinence. The patient had been seizure-free since 1963, when, despite the lack of electrophysiological or radiological evaluation, a daily regimen of phenobarbital was empirically begun. It is also important to note that in 1969 she underwent an abdominal exploration and right hemicolectomy for an adenocarcinoma that had involved the full thickness of the bowel and had spread to one adjacent lymph node.

Examination. The patient had difficulty with recent memory and defects in ability to calculate. Survey of the cranial nerves, motor systems, development, tone, power and coordination, and station and gait were all within normal limits. The sensory examination was also normal. Despite the previously noted extensive radiological involvement of the right temporal lobe, electroencephalography (EEG) and visual field examination were negative. The avascular nature of each of the individual calcified lesions was subsequently documented by complete internal and external carotid angiography.

In view of the patient's recent deterioration in mental status and the subtle tumor enlargement on serial CT, it was believed that the patient had a dynamic neoplastic process consisting of benign and/or metastatic lesions.

Operation. For the purpose of establishing a diagnosis, the two largest lesions were approached through a right frontotemporal craniotomy. Upon direct inspection of the brain a 3.8×2.8 cm, densely calcified, generally circular mass was noted to be replacing approximately 80% of the right anterior temporal lobe (Fig. 3). Although deeply embedded

within the temporal lobe, the mass was covered by only a thin gliotic rind of transparent cortical tissue. The tumor was obviously calcified, demonstrating numerous superficial white excrescences that were verrucous in appearance, rubbery to the touch, and readily separable from the main body of the lesion. Excision of the tumor was accomplished without difficulty. The second lesion, on the medial aspect of the right frontal lobe just above the gyrus rectus, was also removed. Although generally similar in appearance and consistency to the larger mass, this tumor was dumbbell-shaped and occupied a deeper subcortical position. As indicated in the earlier cerebral angiogram, neither of the lesions was associated with significant vascularity.

Postoperative Course. Despite receiving an adequate level of phenobarbital, the patient's postoperative course was complicated by frequent absence attacks. An EEG demonstrated activity of 3 to 5 cycles per second in the right temporal region and a spike focus originating within the ipsilateral frontal lobe. This seizure activity completely ceased within 36 hours after primidone was added to the medication regimen. On the tenth postoperative day the patient was discharged without any evidence of neurological deficit. At follow-up examinations, during a period of 9 months, her course has remained essentially unchanged.

Histological Study. Microscopic evaluation of the two surgical specimens disclosed large areas of variable-sized, thin-walled, non-arterial vascular structures lined with endothelial cells (Fig. 4 left). These vessels were separated by a matrix of densely fibrous, irregularly calcified tissue containing moderate degrees of hemosiderin and cholesterol (Fig. 4 right). The final pathological diagnosis was designated as hemangioma calcificans.

Discussion

The pathophysiological association of parenchymatous calcifications and seizure phenomena have been reported by a number of authors.^{1,3-7} In our patient the heavily calcified, multifocal, epileptogenic masses represented rare variants (hemangioma calcificans) of a broader category of cerebrovascular lesions known as cavernous hemangioma.

Russell and Rubinstein⁸ noted that although such hamartomas are not true neoplasms, they may nevertheless enlarge and damage adjacent nervous tissue. The mechanism of injury is hypothesized to involve engorgement of abnormal vessels with parasitization of surrounding vascular structures. Over a period of time progressive luminal stenosis causes degenerative sclerotic changes within the lesion itself as well as in previously normal contiguous tissue.

A review of the literature revealed only 165 reported cases of intracerebral cavernous hemangiomas.^{3,5,6,10} While frequently supratentorial (77% of cases) and

Hemangioma calcificans

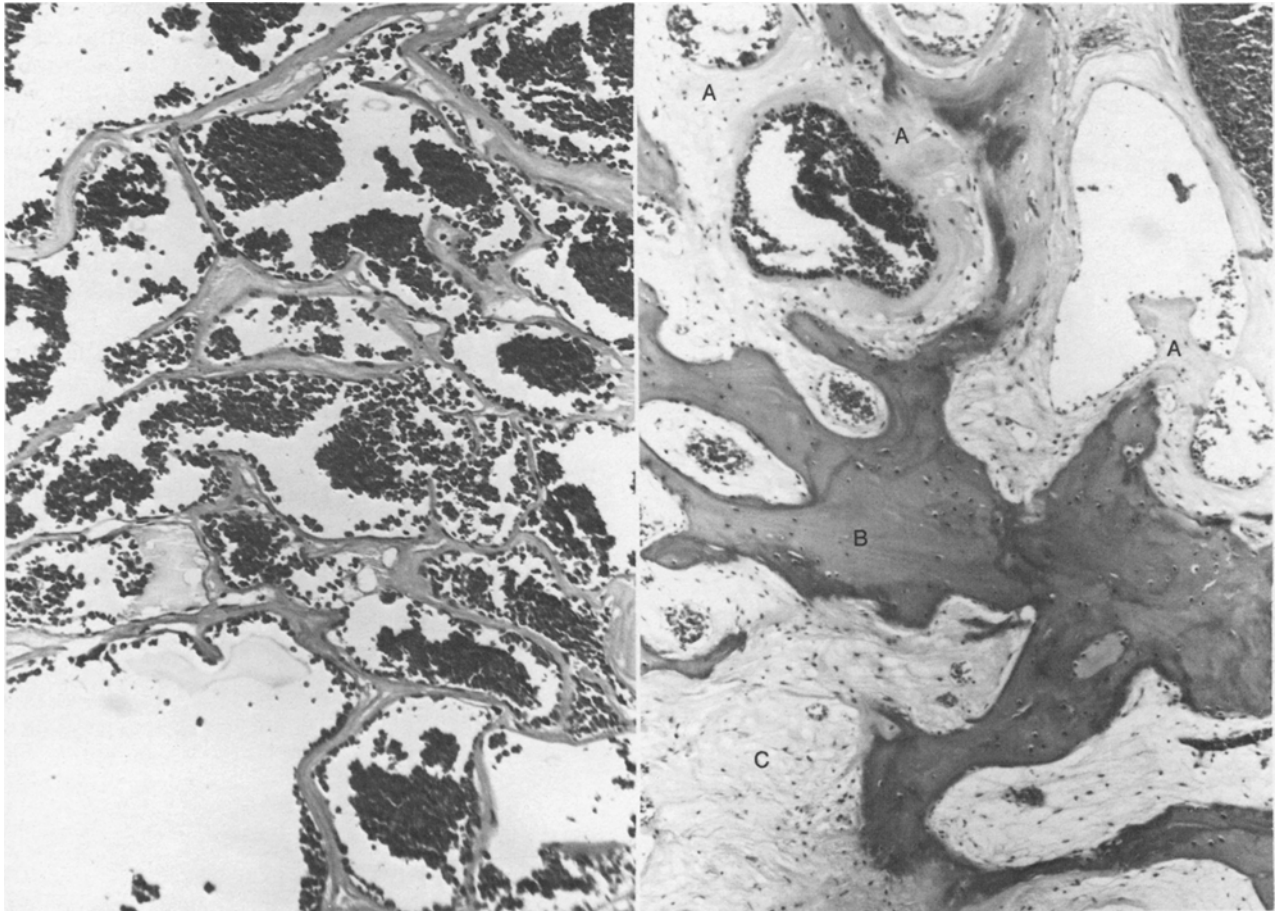


FIG. 4. Photomicrographs of the surgical specimen. *Left:* Large vascular channels can be seen lined by a single layer of endothelial cells and filled with numerous red blood cells. H & E, $\times 70$. *Right:* A section through a different portion of the same lesion showing several thicker-walled vessels (A), separated by calcified bony metaplasia (B), and dense fibrous tissue (C). H & E, $\times 175$.

solitary (87% of cases),¹⁰ such lesions demonstrate a definite predilection for subcortical localization in certain regions adjacent to the Rolandic fissure or the basal ganglia.⁸ Although not encapsulated, these masses present a well defined, lobulated appearance. As a probable consequence of minor episodes of recurrent bleeding, the surrounding tissue usually demonstrates fibrillary gliosis and hemosiderin discoloration. There is no evidence of normal neural elements, yet the hamartomatous lesions microscopically comprise variable-sized dilated vascular spaces lined by single layers of endothelial cells and separated by penetrating tongues of gliotic tissue.⁸ Because of progressive clinical symptomatology that may include seizure phenomena, headaches, or intracranial hemorrhage, a majority of patients are likely to be diagnosed between the third and fifth decades of life.¹⁰

Even though 11% of cases may demonstrate some evidence of macroscopic calcification, this is infrequently a prominent radiographic feature.¹⁰ The

densely calcified, epileptogenic lesions seen in our patient represent the rarest example of cavernous hamartoma, namely, hemangioma calcificans. Since 1948 only seven such cases have been reported.^{6,7,9} In the largest series reported, Penfield and Ward described five patients, 21 to 63 years of age, with clinically progressive, medically resistant temporal-lobe seizure disorders that had ranged from 1 to 30 years in duration.⁶ In each patient plain skull films demonstrated foci of temporal-lobe calcifications composed of discrete, loosely scattered granules. In four of the cases the lesions were solitary and localized to the right side of the brain, within close proximity to the Sylvian fissure. Conversely, in the fifth patient the single lesion was embedded within the anterior portion of the left temporal lobe. In each instance, pneumoencephalography and surgical exploration documented the degenerative and expansile nature of these vascular abnormalities, but failed to demonstrate any neoplastic infiltration. Microscopically, these hamartomas consisted of numerous,

variable-sized blood vessels (primarily veins and capillaries) lined by single layers of endothelial cells. The thicker vessels, comprising a major portion of each specimen and containing extensive areas of both intramural hyalinization and calcification, were surrounded by moderate amounts of gliotic tissue. Following the surgical removal of these vascular lesions, four (80%) of Penfield and Ward's patients returned to their original seizure-free status.⁶ Similar cases have subsequently been reported by Shafey, *et al.*,⁹ and Runnels, *et al.*⁷

Because of their tendency for intracranial hemorrhage, Voigt and Yaşargil¹⁰ proposed extirpation of all readily accessible solitary cavernous hemangiomas. Obviously, hemangioma calcificans represents a more benign spectrum of this disease since none of the reported cases demonstrated such a propensity. Despite the absence of bleeding, Penfield and Ward⁶ nevertheless advocated the removal of these lesions on the basis of their epileptogenic potential and questionably progressive growth patterns. Our patient was explored because of the diagnostic dilemma presented by the atypical multiplicity of her lesions as well as the complicating concern over the possibility of metastatic disease. In view of the current benefits of medical seizure therapy and the generally innocuous histological nature of these calcified lesions, we believe that this problem should be treated conservatively by frequent observation with CT scanning. Surgical intervention is best reserved for those individuals who are resistant to anticonvulsant therapy or who, as in this instance, may either represent a diagnostic problem or demonstrate obvious enlargement of the hamartomatous mass.

References

1. Alexander WS: Cerebral calcification epilepsy. Report of a case of epilepsy caused by a calcified hamartoma of the brain. *J Neurosurg* 10:69-73, 1953

2. Bremer L, Carson NB: A case of brain tumor (angioma cavernosum), causing spastic paralysis and attacks of tonic spasms. Operation. *Am J Med Sci* 100:219-242, 1890
3. Falconer MA, Pond DA: Temporal lobe epilepsy with personality and behaviour disorders caused by an unusual calcifying lesion. *J Neurol Neurosurg Psychiatry* 16:234-244, 1953
4. Geyelin HR, Penfield W: Cerebral calcification epilepsy. Enderteritis calcificans cerebri. *Arch Neurol Psychiatr* 21:1020-1043, 1929
5. Jain KK: Intraventricular cavernous hemangioma of the lateral ventricle. Case report. *J Neurosurg* 24:762-764, 1966
6. Penfield W, Ward A: Calcifying epileptogenic lesions. Hemangioma calcificans, report of a case. *Arch Neurol Psychiatr* 60:20-36, 1948
7. Runnels JB, Gifford DB, Forsberg PL, et al: Dense calcification in a large cavernous angioma. Case report. *J Neurosurg* 30:293-298, 1969
8. Russell DS, Rubinstein LJ: *Pathology of Tumours of the Nervous System*, ed 3. Baltimore: Williams and Wilkins, 1971, pp 93-98
9. Shafey S, Gargano F, Mackey E: Angiomatous malformation as a cause of cerebral calculus. Case report. *J Neurosurg* 24:898-900, 1966
10. Voigt K, Yaşargil MG: Cerebral cavernous haemangiomas or cavernomas. Incidence, pathology, localization, diagnosis, clinical features and treatment. Review of the literature and report of an unusual case. *Neurochirurgia* 19:59-68, 1976

Address reprint requests to: Michael V. DiTullio, Jr., M.D., 65 Columbian Street, South Weymouth, Massachusetts 02190.