

SYMPTOMATIC VASOSPASM AFTER RESECTION OF A SUPRASellar PILOCYTIC ASTROCYTOMA: CASE REPORT AND POSSIBLE PATHOGENESIS

Steven D. Chang, M.D., O. W. Stephanie Yap, M.D., and John R. Adler, Jr., M.D.
Department of Neurosurgery, Stanford University Medical Center, Stanford, California

Chang, SD, Yap OWS, Adler JR, Jr. Symptomatic vasospasm after resection of a suprasellar pilocytic astrocytoma: Case report and possible pathogenesis. *Surg Neurol* 1999;51:521-7.

BACKGROUND

Cerebral vasospasm from pathology other than subarachnoid hemorrhage is uncommon. A case of severe vasospasm after resection of a suprasellar pilocytic astrocytoma is reported.

METHODS

A 45-year-old male presented with headache, left facial numbness, bilateral visual loss, and ataxia. Evaluation revealed a large suprasellar tumor, which was resected. Pathologic examination showed pilocytic astrocytoma. The patient developed hemiparesis and aphasia on the fifth postoperative day. Vascular spasm was documented on angiography and by transcranial Doppler.

RESULTS

Intraarterial papaverine resulted in moderate angiographic improvement. Attempts to open middle cerebral artery branches with angioplasty were unsuccessful. The patient subsequently developed a left middle cerebral artery infarct.

CONCLUSIONS

To our knowledge, this is the first description of vasospasm after resection of an astrocytoma. Possible mechanisms contributing to this unusual complication after resection of tumors are discussed.

KEY WORDS

Astrocytoma, infarction, tumor, vasospasm.

Symptomatic vasospasm after subarachnoid hemorrhage from aneurysm rupture is common [4,19,29]. Although less common, vasospasm after head trauma is also well described [1]. In contrast, vasospasm rarely occurs after resection of brain tumors. Furthermore, the low number of previous reports describing this phenomenon have

been limited largely to pituitary tumors [2,3,7,25] and acoustic neuromas [9,21].

We describe a case of delayed symptomatic vasospasm after resection of a vascular pilocytic astrocytoma. Neurologic deterioration in association with vasospasm, as documented by transcranial Doppler (TCD) and angiography, began on the fifth postoperative day, mirroring the timing observed after subarachnoid hemorrhage. Although the pathogenesis of this phenomenon is unknown, we speculate that narrowing of the internal carotid artery, demonstrated on preoperative angiograms, predisposed this patient to severe vasospasm. Furthermore, we discuss numerous other factors that might also be implicated in the development of vasospasm in such a patient.

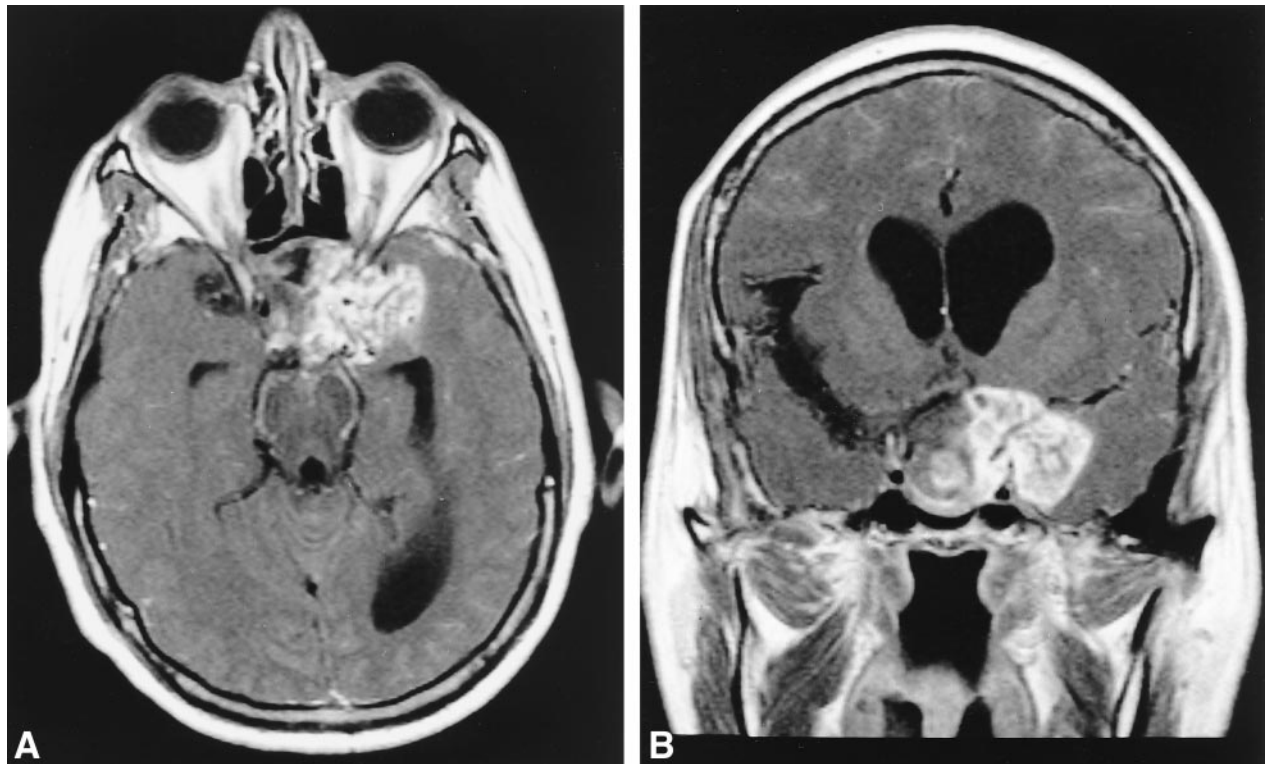
CASE REPORT

A 45-year-old right-handed man presented with a 2-year history of severe "migraine" headaches, accompanied by an indeterminant period of visual deterioration. Three months before admission, he developed left facial numbness around his mouth and jaw. Shortly after, the vision in his left eye progressed to complete blindness with only light perception in the right eye. There was also difficulty with coordination, dizziness, and episodic (15-min) "loss of control of limbs and disorientation."

On neurological exam light perception was absent on the left, and visual acuity was markedly impaired in the right eye. Right papilledema, left optic atrophy, and a left Marcus-Gunn pupil were noted. There was decreased corneal and facial sensation on the left. His left temporalis muscle was weak and his gait wide-based.

Magnetic resonance imaging (MRI) demonstrated a suprasellar mass impinging on the optic chiasm

Address reprint requests to: Dr. John R. Adler, Room R-205, Department of Neurosurgery, Stanford University Medical Center, Stanford, CA 94305.
Received November 22, 1996; accepted May 5, 1997.



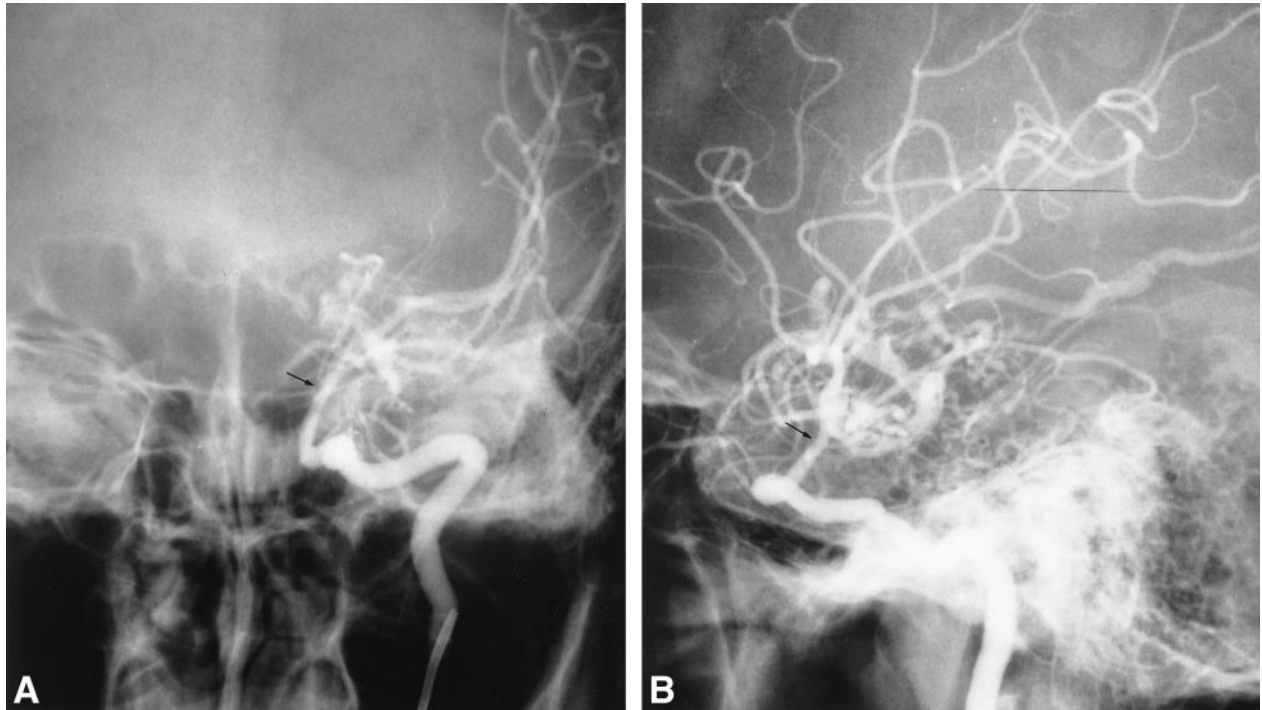
1 T1 weighted images with gadolinium contrast in axial (A) and coronal (B) images show the extent of the tumor around the left cavernous sinus. Note the encasement of arterial vessels best seen on the coronal image (B).

with encasement of the left internal carotid artery (ICA) and its major branches. There was hydrocephalus and bony remodeling of the sella and sphenoid wing (Figure 1). Cerebral angiography showed a hypervascular lesion. Significant constriction of the left intracranial ICA was noted (Figure 2). Serum prolactin was elevated at 41.5 ng/mL.

The tumor was approached via a left pterional craniotomy. It was grayish-yellow, soft, and encased both optic nerves and chiasm. Tumor extended into the hypothalamus and cavernous sinus. The entire supraclinoid carotid including M1 and A1 segments were encased and narrowed, and the tumor was removed carefully from these structures. A subtotal resection was performed, leaving the tumor in and around the hypothalamus.

The tumor consisted of two distinct histological patterns. The first contained astrocytes resembling pilocytic cells, hemorrhage, organized clot, and necrosis. The second consisted of sheets of small, round cells with occasional scant processes separated by myxoid material. Electron microscopy revealed neoplastic cells with abundant intermediate filaments, arranged in parallel bundles without evidence suggestive of ependymal differentiation. These findings were consistent with a pilocytic astrocytoma (Figure 3).

The patient's initial postoperative neurologic condition was unchanged from his preoperative status. An MRI scan done on the first postoperative day revealed residual suprasellar tumor and a small amount of postoperative blood. Five days postoperatively the patient developed aphasia and a right hemiparesis. Computed tomography (CT) showed an irregular, 1.5-cm hypodense lesion in the left basal ganglia adjacent to the head of the caudate, and a smaller less well-defined hypodensity in the left putamen consistent with an evolving infarct. Immediate angiography demonstrated narrowing of the supraclinoid left ICA and left MCA. TCD studies showed elevated flow velocities in the right (170 cm/sec) and left (114 cm/sec) MCAs. Hyperdynamic hemodilutional therapy and nimodipine were started, with initial resolution of his symptoms. However, profound right arm weakness was noted on postoperative Day 8 and a concurrent angiogram demonstrated poor filling of the left MCA vessels. Four courses of intraarterial papaverine were administered with only modest improvement (Figure 4). Angioplasty of the left M1 segment was aborted when it proved impossible to navigate the balloon/guidewire complex distal to the regions of stenosis. The patient went on to develop a large left MCA distribution infarct. His neurologic exam included a



2 Anteroposterior (A) and lateral (B) angiography studies show preoperative vascular structure. The left supraclinoid internal carotid artery seemed to be stenotic (arrows). The left anterior cerebral artery filled from the contralateral side.

profound global aphasia and right hemiparesis, from which the patient made a partial recovery.

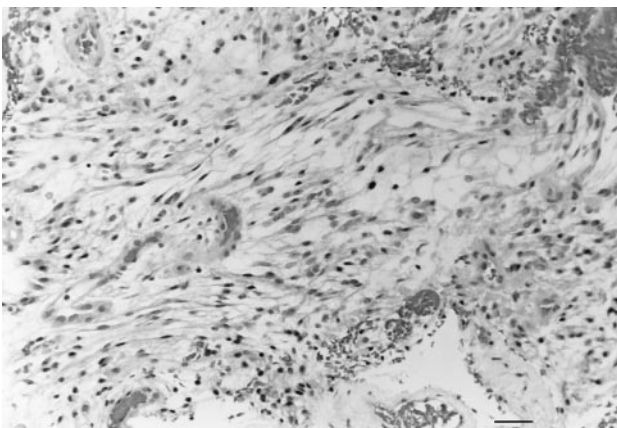
DISCUSSION

Only 25 cases of vasospasm complicating tumor resection have been documented previously [1,29,37]. Most reports describe this phenomenon after removal of pituitary adenomas [2,3,7,25]. Less frequently reported cases involved acoustic neuroma

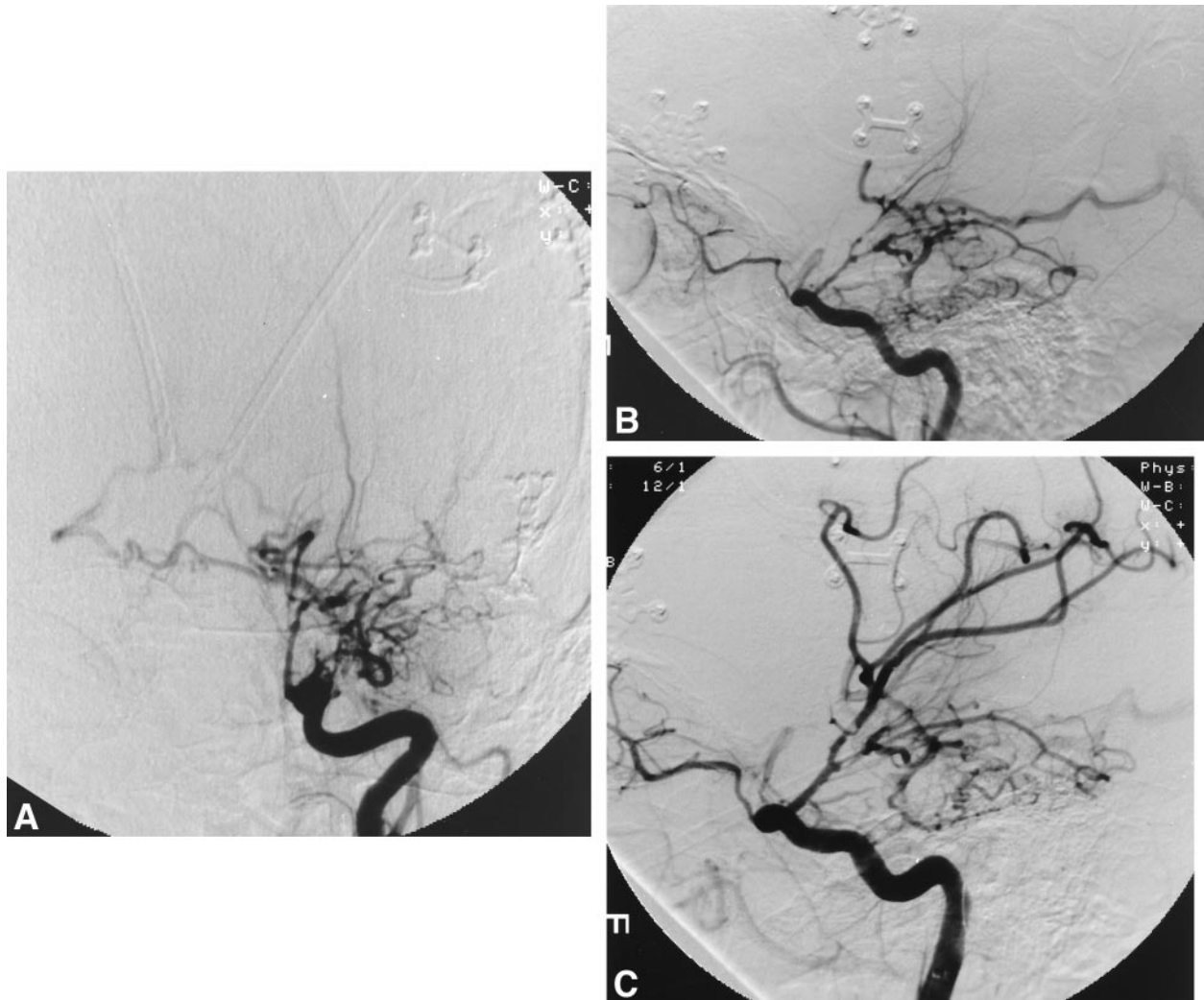
[9,21], meningioma [21], craniopharyngioma [2], or adenocarcinoma [2]. This report is, to the best of our knowledge, the first reported case of vasospasm occurring after the resection of a glial tumor.

Most hypotheses traditionally advanced to explain the occurrence of vasospasm, especially that which occurs after aneurysm rupture, implicate blood in the subarachnoid space [11,19] and vascular factors such as hemoglobin [12], oxyhemoglobin [6,14,19,23], and bilirubin [10]. However, vasospasm in the setting of tumor resection is an odd occurrence, and given its rarity, may or may not share a similar pathogenesis with other better known types of vasospasm. Although subarachnoid blood or hemorrhage within the tumor resection bed could be a causative factor, its significance is less clear in a patient, such as that being reported, where there is little blood in the resection bed (Fisher Grade 1). Alternatively, it is possible that intraoperative blood clots, subsequently irrigated or aspirated away, may have initiated a cascade of events leading to vasospasm along classic pathways [6,11]. The amount of intraoperative bleeding, hypothesized previously to be related to the likelihood of vasospasm [2,21], may be the critical variable.

Mechanical trauma to blood vessels, which inev-



3 Photomicrograph of the tumor specimen. Pathology was consistent with pilocytic astrocytoma.



4 Anteroposterior (A) and lateral (B) left internal carotid artery injections show evidence of severe vasospasm in both the anterior and middle cerebral artery distributions. The patient was treated with papaverine with resultant improvement in vascular diameter as noted in the lateral left internal carotid artery viewed status post papaverine (C). A left M1 angioplasty was attempted but aborted secondary to inability to navigate the balloon guidewire complex distally to the desired location.

itally occurs during tumor resection, has been implicated in vasospasm. Symon demonstrated that mechanical force could cause vasospasm in the MCA [34]. Mechanical trauma may also explain vasospasm in patients with head trauma (particularly those without subarachnoid hemorrhage) [28,34]. However, if mechanical trauma were the primary cause, one would expect the resultant vasospasm to occur immediately after surgery, not after a delay of several days. Alternatively, mechanical trauma might contribute to vasospasm by releasing chemical substances from surrounding tissue that may act in a delayed fashion [26].

An imbalance of vascular tone seems to contribute to vasospasm. The physiologic stress of surgery may increase cerebrovascular reactivity to nor-

adrenalin and serotonin [22] or prostaglandins [24]. Others have shown increased levels of norepinephrine in the cerebrospinal fluid of patients with vasospasm [31]; the degree of vasospasm may be dose-related to the levels of these vasoactive substances. Additionally, the impairment of endothelial derived relaxant factor (EDRF) has been implicated in the mechanism of vasospasm [35]. Normal vessels play an obligatory role in vasodilatation by releasing EDRF; surgical manipulation or sacrifice of such vessels may impair EDRF release and shift the balance of vascular tone towards vasospasm.

It has been postulated that the hypothalamus plays a role in the genesis of vasospasm [20,36,38,39]. In vivo experiments demonstrate that hypothalamic extracts produce diffuse vasospasm [39].

Other studies implicate the median eminence as the critical portion of the hypothalamus involved in this phenomenon. Selective lesioning of the median eminence in primate and rat models prevents the development of both acute and late vasospasm [32, 33]. The median eminence receives projections from the A1 and A2 nucleus of the medulla [33], and these nuclei have also been implicated in vasospasm; selective lesioning of these nuclei and projecting fibers prevents vasospasm after subarachnoid hemorrhage [32,33]. In the majority of reported cases of vasospasm after tumor resection, the tumor was located in the suprasellar region with invasion or compression of the hypothalamus (as in our case). These tumors, perhaps through disinhibition or stimulation of the median eminence, may predispose to vasospasm. Similarly, surgery for acoustic neuromas could disrupt the projections from the A1 and A2 nuclei of the medulla, thereby predisposing to vasospasm.

Given that this is the first reported case of vasospasm after a glial tumor resection, it may be relevant to address specific chemical factors that have been hypothesized to modulate vasospasm in such a setting. Platelet derived growth factor (PDGF) is a potent vasoconstrictor, acting through a well characterized pathway involving the release of intracellular calcium [5,15]. Vasospasm from PDGF has been shown in several animal models [8,17]. Other studies have shown increased production of PDGF and PDGF-related peptides in gliomas [13,16,27]. Recent data show upregulation of PDGF receptor- β expression on endothelial tissue of vessels that supply these tumors [30]. Because glial tumors are known to express PDGF [13,16,27], the release of significant amounts of this growth factor during surgery could possibly cause adjacent vessels to spasm by altering intracellular calcium homeostasis.

Cytokines are also produced by glial tumors. Although no specific studies have been performed in benign tumors, malignant glial tumors produce IL-1, IL-6, and IL-8, all of which seem to be involved in vasospasm. IL-1 activates PDGF [18]. IL-6 and IL-8 are elevated in the CSF and serum of patients after a subarachnoid hemorrhage, and may play a role in vasospasm through a yet undefined pathway [20]. The release of these cytokines during tumor resection could by themselves, or with other factors, precipitate vasospasm in adjacent vessels.

Although the occurrence of vasospasm in the setting of tumor resection is a curious phenomenon, it nevertheless may shed some light on the mechanism by which all vasospasm is produced. In the case being presented, it is interesting to speculate that causes other than subarachnoid blood

were critical in causing the severe vasospasm suffered by this patient.

REFERENCES

1. Adams CBT. Vasospasm: occurrence in conditions other than subarachnoid hemorrhage from a bleeding aneurysm. In: Wilkins RH, eds. Cerebral arterial spasm. Baltimore, MD: Williams & Wilkins, 1980: 471-5.
2. Aoki N, Origiano TC, al-Mefty O. Vasospasm after resection of skull base tumors. *Acta Neurochir (Wien)* 1995;132:53-8.
3. Barrow DL, Tindall GT. Loss of vision after transsphenoidal surgery. *Neurosurgery* 1990;27:60-8.
4. Bloomfield SM, Sonntag VK. Delayed cerebral vasospasm after uncomplicated operation on an unruptured aneurysm: case report. *Neurosurgery* 1985;17: 792-6.
5. Bornfeldt KE, Raines EW, Graves LM, Skinner MP, Krebs EG, Ross R. Platelet-derived growth factor. Distinct signal transduction pathways associated with migration versus proliferation. *Ann NY Acad Sci* 1995; 766:416-30.
6. Boullin DJ, Tagari P, du Boulay G, Aitken V, Hughes JT. The role of hemoglobin in the etiology of cerebral vasospasm. An in vivo study of baboons. *J Neurosurg* 1983;59:231-6.
7. Camp PE, Paxton HD, Buchan GC, Gahbauer H. Vasospasm after trans-sphenoidal hypophysectomy. *Neurosurgery* 1980;7:382-6.
8. Cirillo M, Quinn SJ, Romero JR, Canessa ML. Regulation of Ca^{2+} transport by platelet-derived growth factor-BB in rat vascular smooth muscle cells. *Circ Res* 1993;72:847-56.
9. de Almeida GM, Bianco E, Souza AS. Vasospasm after acoustic neuroma removal. *Surg Neurol* 1985;23:38-40.
10. Duff TA, Feilbach JA, Yusuf Q, Scott G. Bilirubin and the induction of intracranial arterial spasm. *J Neurosurg* 1988;69:593-8.
11. Fisher CM, Kistler JP, Davis JM. Relation of cerebral vasospasm to subarachnoid hemorrhage visualized by computerized tomographic scanning. *Neurosurgery* 1980;6:1-9.
12. Foley PL, Takenaka K, Kassell NF, Lee KS. Cytotoxic effects of bloody cerebrospinal fluid on cerebral endothelial cells in culture. *J Neurosurg* 1994;81:87-92.
13. Guha A, Dashner K, Black PM, Wagner JA, Stiles CD. Expression of PDGF and PDGF receptors in human astrocytoma operation specimens supports the existence of an autocrine loop. *Int J Cancer* 1995;60:168-73.
14. Hall AV. Oxyhemoglobin-induced vasospasm [letter; comment]. *J Neurosurg* 1992;76:725-6.
15. Heldin CH, Westesson A, Westermark B. Platelet-derived growth factor. *Mol Cell Endocrinol* 1985;39: 169-87.
16. Hermansson M, Nister M, Betsholtz C, Heldin CH, Westermark B, Funa K. Endothelial cell hyperplasia in human glioblastoma: coexpression of mRNA for platelet-derived growth factor (PDGF) B chain and PDGF receptor suggests autocrine growth stimulation. *Proc Natl Acad Sci USA* 1988;85:7748-52.
17. Hughes AD. Increase in tone and intracellular Ca^{2+} in

- rabbit isolated ear artery by platelet-derived growth factor. *Br J Pharmacol* 1995;114:138-42.
18. Ito A, Shimokawa H, Kadokami T, Fukumoto Y, Owada MK, Shiraishi T, Nakaike R, Takayanagi T, Egashira K, Takeshita A. Tyrosine kinase inhibitor suppresses coronary arteriosclerotic changes and vasospastic responses induced by chronic treatment with interleukin-1 beta in pigs in vivo. *J Clin Invest* 1995; 96:1288-94.
19. Kassell NF, Sasaki T, Colohan AR, Nazar G. Cerebral vasospasm following aneurysmal subarachnoid hemorrhage. *Stroke* 1985;16:562-72.
20. Kikuchi T, Okuda Y, Kaito N, Abe T. Cytokine production in cerebrospinal fluid after subarachnoid haemorrhage. *Neurol Res* 1995;17:106-8.
21. LeRoux PD, Haglund MM, Mayberg MR, Winn HR. Symptomatic cerebral vasospasm following tumor resection: report of two cases. *Surg Neurol* 1991;36:25-31.
22. Lobato RD, Marin J, Salaices M, Rivilla F, Burgos J. Cerebrovascular reactivity to noradrenalin and serotonin following experimental subarachnoid hemorrhage. *J Neurosurg* 1980;53:450-85.
23. Macdonald RL, Weir BK. A review of hemoglobin and the pathogenesis of cerebral vasospasm. *Stroke* 1991; 22:971-82.
24. Maeda Y, Tani E, Miyamoto T. Prostaglandin metabolism in experimental cerebral vasospasm. *J Neurosurg* 1981;55:779-89.
25. Mawc JR, Ausman JJ, Erickson DL, Maxwell RE. Vasospasm following transcranial removal of large pituitary adenomas. Report of three cases. *J Neurosurg* 1979;50:229-32.
26. Nilsson B. Vasospasm and the pathophysiology of concussive head injury. In: Wilkins RH, ed. *Cerebral arterial spasm*. Baltimore, MD: Williams & Wilkins, 1980:488-95.
27. Nister M, Libermann TA, Betsholtz C et al. Expression of messenger RNAs for platelet-derived growth factor and transforming growth factor-alpha and their receptors in human malignant glioma cell lines. *Cancer Res* 1988;48:3910-8.
28. Pasqualin A, Vivenza C, Rosta L, Licata C, Cavazzani P, Da Pian R. Cerebral vasospasm after head injury. *Neurosurgery* 1984;15:855-8.
29. Peerless SJ. Postoperative cerebral vasospasm without subarachnoid hemorrhage. In: Wilkins RH, ed. *Cerebral arterial spasm*. Baltimore, MD: Williams & Wilkins, 1980:496-8.
30. Plate KH, Breier G, Farrell CL, Risau W. Platelet-derived growth factor receptor-beta is induced during tumor development and upregulated during tumor progression in endothelial cells in human gliomas. *Lab Invest* 1992;67:529-34.
31. Shigeno T. Norepinephrine in cerebral spinal fluid of patients with cerebral vasospasm. *J Neurosurg* 1982; 56:344-9.
32. Svendgaard NA, Delgado TJ, Brun A. Effect of selective lesions in the hypothalamic-pituitary region on the development of cerebral vasospasm following an experimental subarachnoid hemorrhage in the rat. *J Cereb Blood Flow Metab* 1986;6:650-7.
33. Svendgaard NA, Shiokawa Y, Delgado-Zygmunt TJ, Arbab MA, Skagerberg G, Brun A. Effect of lesioning of medullary catecholamine neurons or the median eminence on the development of cerebral vasospasm in the squirrel monkey. *Acta Neurochir (Wien)* 1992;118: 137-45.
34. Symon L. An experimental study of traumatic cerebral vascular spasm. *J Neurol Neurosurg Psychiatry* 1967;30:497-505.
35. Wilkins RH. Cerebral Vasospasm. *Contemp Neurosurg* 1988;(10)4:1-6.
36. Wilkins RH. Hypothalamic dysfunction and intracranial arterial spasms. *Surg Neurol* 1975;4:472-80.
37. Wilkins RH. Intracranial arterial spasm after procedures other than operations for intracranial aneurysm. In: Wilkins RH, ed. *Cerebral arterial spasm*. Baltimore, MD: Williams & Wilkins, 1980:505-9.
38. Wilkins RH. The possible role of the hypothalamus in the development of intracranial arterial spasm. In: Wilkins RH, ed. *Cerebral arterial spasm*. Baltimore, MD: Williams & Wilkins, 1980:266-9.
39. Wilson JL, Feild JR. The production of intracranial vascular spasm by hypothalamic extract. *J Neurosurg* 1974;40:473-9.

COMMENTARY

Chang and colleagues present a case of symptomatic arterial narrowing occurring after removal of a suprasellar pilocytic astrocytoma that encased a carotid and middle cerebral artery. Vasospasm, or arterial narrowing, has been reported after head injury, removal of intracranial tumors, rupture of arteriovenous malformations and aneurysms, in association with tuberculous and purulent meningitis, ophthalmoplegic migraine, hypertensive encephalopathy, arteriolar embolization or removal of an embolus from the MCA, myelography, electroconvulsive therapy, eclampsia, and with unruptured and sometimes unoperated aneurysms [1]. In the majority of cases blood has been demonstrated in the cerebrospinal fluid. In many there was no CT scan, MRI, or lumbar puncture done after surgery to determine whether there was blood present in the subarachnoid space or, in some cases, to rule out the remote possibility of infection. Therefore it is often difficult to say whether or not the spasm was attributable to subarachnoid blood or to some other cause. Subarachnoid blood clots cause reversible arterial constriction that is vasospasm. The pathology and pathogenesis of arterial narrowing in association with other diseases such as infection, eclampsia, migraine, after radiation therapy, and possibly in association with lesions in the area of the hypothalamus, is probably different.

The authors review 25 cases of vasospasm occurring after removal of an intracranial tumor. The majority of these have been in the sellar region or have been acoustic schwannomas. In a review of 20 such cases, blood was documented in the cerebrospinal fluid in 8 cases of 20. In 11 cases, lumbar puncture or CT scan was not obtained, and in one

case the CSF was clear, although interpretation of the cause of arterial narrowing in this patient was complicated by the presence of chronic inflammation and the thick yellow membrane in the suprasellar area at postmortem examination suggested the possibility of infection. In the case presented by Chang et al there was blood in the operative site noted on postoperative imaging studies and this could have been the cause of the arterial narrowing. Alternatively, Symon noted that arterial thrombosis may develop secondary to arterial manipulation at surgery and it doesn't seem impossible for this to occur in a delayed fashion attributable to thrombosis on an artery with damaged endothelium that was damaged intraoperatively.

The authors discuss other potential causes of narrowing such as a hypothalamic etiology. There is some evidence that weighs against this being a significant factor, such as the fact that vasospasm

does not occur commonly after surgery for non-hemorrhagic lesions in this area. I suspect that the majority of these cases are attributable to subarachnoid hemorrhage. In some cases, however, other etiologies may be present such as atherosclerosis, mechanical spasm, thrombosis of the artery secondary to manipulation (especially in a case like this where the artery is already narrowed and abnormal), radiation damage, or other causes.

R. L. Macdonald, M.D., Ph.D.

*Section of Neurosurgery
University of Chicago
Chicago, Illinois*

REFERENCE

1. Macdonald RL, Hoffman HJ. Subarachnoid hemorrhage and vasospasm following removal of craniopharyngioma. J Clin Neurosci 1997.

A majority of depressed people are seen initially in primary care settings, where the depression is not diagnosed and its symptoms frequently are inappropriately treated.

—DEPRESSION FACT SHEET
NATIONAL INSTITUTE OF MENTAL HEALTH