

L. Bachmann
J. Dressler
T. Pinzer
G. Schackert

Human hypersensitivity angiitis: an uncommon cause of death after trauma

Received: 14 July 1998;
in revised form 21 December 1998
Accepted: 5 January 1999

L. Bachmann (✉)
Department of Traumatology,
Medical School of Technical University,
Fetscherstraße 74,
D-01307 Dresden, Germany
(Tel.: +49-351-4582700,
Fax: +49-351-4584307)

J. Dressler
Department of Legal Medicine,
Medical School of Technical University,
Fetscherstraße 74,
D-01307 Dresden, Germany

T. Pinzer
Department of Neurosurgery,
Medical School of Technical University,
Fetscherstraße 74,
D-01307 Dresden, Germany

G. Schackert
Department of Neurosurgery,
Medical School of Technical University,
Fetscherstraße 74,
D-01307 Dresden, Germany

Abstract *Introduction:* The article demonstrates, using a case report, that death following an accident may have rarely encountered causes that are not a direct result of trauma and that can only be detected by autopsy. *Case:* An unconscious woman aged 57 years was admitted to hospital. Despite immediate surgery for intracranial haemorrhage diagnosed by means of cranial computed tomography, the patient died showing clinical symptoms of circulatory depression after a brief period of stabilisation. The autopsy established myocardial infarction with hypersensitivity angiitis as the cause of death. *Conclusion:* In this case, the authors hold the opinion that the intravenous application of antibiotics during the patient's stay in hospital resulted in hypersensitivity angiitis. The factors causing hypersensitivity angiitis, the

morphological picture (clinical, histological) and therapeutic measures are described.

Key words Hypersensitivity vasculitis · Immune complex disease · Cerebral haemorrhage · Myocardial infarction

Introduction

Hypersensitivity angiitis is a leucocytoclastic vasculitis primarily of the venules, but also of the capillaries and arterioles. It is mainly a skin disease, but can also affect all other organs [1, 10]. The disease may be initiated by immune complexes being deposited in blood vessels after a multitude of exogenous and endogenous antigens have been found, thereby causing occlusive vasculitis. Bacterial constituents [11, 15] and drugs [7, 13, 16], such as antibiotics, are among the antigens, but paraproteins and cryoglobulins may also precipitate in the blood vessels [3, 14]. This report describes the fatal course of the disease in a

clinical case in which diagnosis was possible only by forensic autopsy.

Case report

An unconscious woman, aged 57 years, found lying on the street was admitted to the hospital by the emergency physician. An alcoholic fetor was observed during the examination on admission; the blood alcohol concentration was 1.90 mg/ml. This and the presence of benzodiazepine in the urine were indicative initially of combined intoxication as the cause of unconsciousness. The liver function

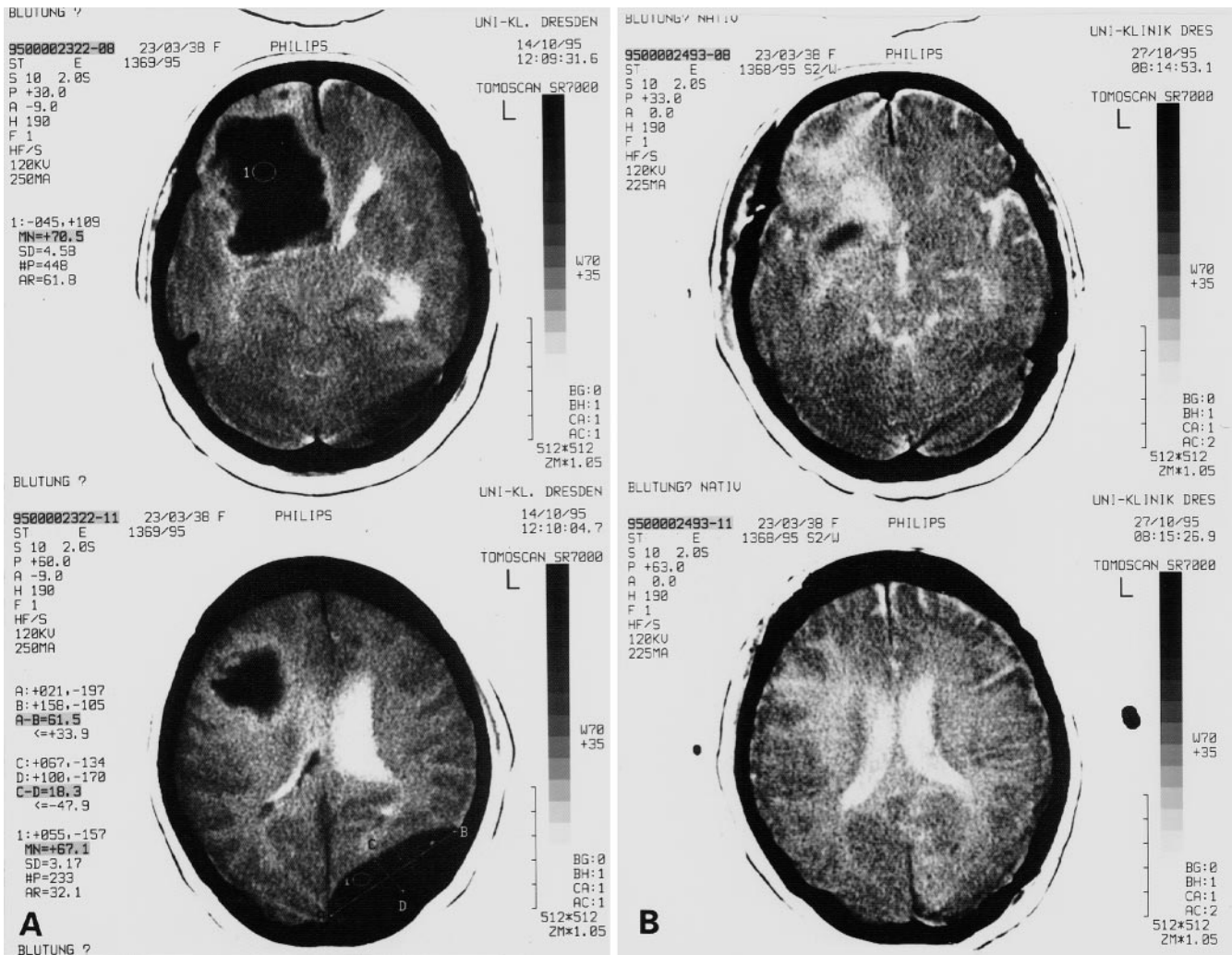


Fig. 1 **A** Cranial computed tomography (CCT) on the day of admission showing epidural and subdural haematomas on the left side and intracerebral haemorrhage on the right front side. **B** Control CCT after osteoplastic trepanation, removal of the haematomas, stoppage of the haemorrhage and introduction of an intracranial pressure probe

data [lactate dehydrogenase (LDH), aspartate aminotransferase (ASAT), alanine aminotransferase (ALAT) and gamma-glutamyltransferase (GGT)] were elevated and the haemocoagulation parameters were abnormal [thrombocytopenia, reduced thromboplastin time and low angiotensin (AT) III activity].

Cranial computed tomography (CCT) revealed an acute epidural haematoma on the left side and a large intracerebral haemorrhage on the right front side. The surgical treatment consisted of osteoplastic trepanation, removal of the haematomas, stopping of the haemorrhage and the introduction of an intracranial pressure probe type (Fig. 1).

Shortly thereafter, the patient became responsive and could be extubated. During the further course of treatment,

consciousness deteriorated again. The control CCT established a right frontotemporal subdural hygroma. An emergency operation was performed to relieve and drain the hygroma. During her stay in the intensive care unit, the patient received successively and, at times, combined cefotiam, tobramycin, ceftriaxon, cotrimoxazol, cefazolin, imipenem and ciprofloxazin as treatment for pneumonia, which was detected by X-rays, and a bacterial infection of the urinary tract. The subsequent circulatory depression required the massive administration of catecholamines. The patient's general practitioner had not diagnosed heart disease. Similarly, relatives of the patient were unaware of a heart-disease condition.

The patient died with symptoms of acute left ventricular heart failure after a total of 19 days of treatment. As an unnatural death of unclear aetiology was suspected (possible effects of falling impact), an autopsy in the Department of Legal Medicine was ordered.

As well as confirming numerous older fronto-temporal cerebral contusions, the autopsy revealed a left occipito-

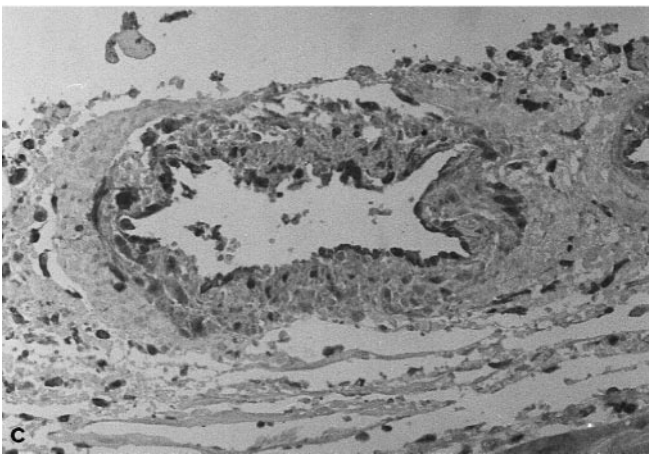
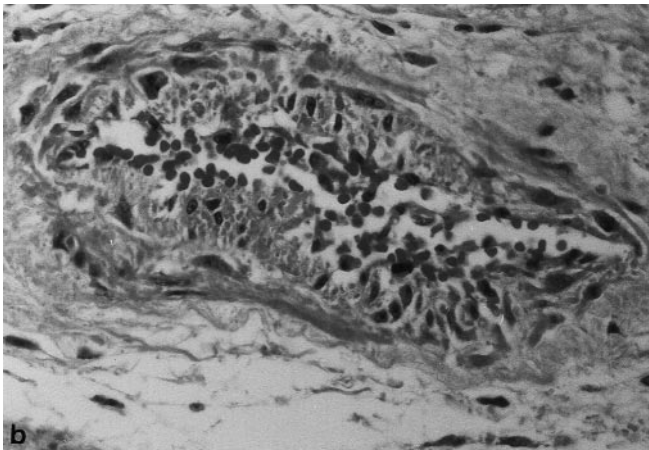
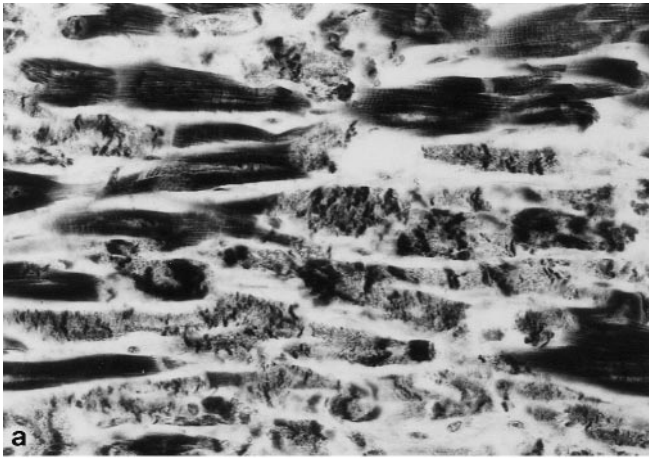


Fig. 2 **a** Acute myocardial fibre necroses with karyolysis and contraction bands [phosphotungstic acid-haematoxylin (PTAH), $\times 360$]. **b** Necrosis and endothelial cell proliferation of several coronary artery branches with leucocytic activation and haemorrhage from the blood vessel walls [Haematoxylin & Eosin (HE), $\times 360$]. **c** Severe reaction (grade 3) for ELAM-1 (CD 62 E) on the inflamed endothelium (ABC, mAK Dianova, $\times 360$)

temporal basal skull fracture. The type of fracture (direct fracture) and its location (below the so-called brim line) suggested that it had been caused by a fall. Operations were performed under standard conditions. The direct cause of death, however, was an acute 50 \times 30-mm anterior and posterior myocardial infarction of the left ventricle of the heart with hypersensitivity angiitis leading to occlusion of multiple coronary arteries (Fig. 2).

A full-blown fine-noded pseudolobular cirrhosis of the liver with evidence of alcoholic hyaline was established as a concomitant disease.

The ischaemic myocardial infarction, determined by autopsy, was the cause of the circulatory depression observed in the clinic. The first electrocardiogram (ECG) carried out immediately following admission to the hospital indicated a sinus rhythm with no reason to suspect a previous myocardial infarction. During the patient's stay in the intensive care unit, continual ECG monitoring recorded the appearance of occasional supraventricular and ventricular extrasystoles. In contrast, the ECG following the circulatory depression and prior to the death of the patient indicated a peripheral low voltage and signs of an anterolateral myocardial infarction. Whilst in the intensive care unit, the patient was given a cardiac catheterisation. Initially, cardiac output, central venous pressure (CVP), mean pulmonary arterial pressure and mixed venous oxygen saturation were within the normal ranges. In the circulatory depression phase, cardiac output decreased, CVP and mean pulmonary arterial pressure rose and mixed venous oxygen saturation declined.

Discussion

The clinical case described here exemplifies that apparently unambiguous symptoms often do not lead immediately to the ultimately established diagnosis. The patient's unconsciousness was originally thought to be due to intoxication. The laboratory findings, however, showed pathological coagulation parameters. The CCT ordered by the neurosurgeon consulted in this case finally established that unconsciousness was due to acute epidural haematoma and intracerebral haemorrhage. After her condition had been stabilised for some time, however, the patient died of circulatory depression of an initially unclear origin.

The autopsy established that the acute heart failure was caused by extensive myocardial infarction macroscopically and a hypersensitivity angiitis histologically and immunohistologically. The phosphotungstic acid-haematoxylin (PTAH) reaction permits myocardial necroses to be detected only a few hours after the onset of ischaemia. Typically, so-called contraction bands can be observed in which the transverse striation of the myocardial cell is compressed and the cells are swollen [9]. The increased expression of adhesion molecules (among them ICAM-1,

ELAM-1) at the inflamed endothelial cells of the blood vessels is a new diagnostic criterion of hypersensitivity vasculitis [2]. Its diagnosis, however, often requires the immunohistological examination of frozen sections. The time at which the disease occurred (before the trauma or possibly due to the administration of an antibiotic during the ward treatment) cannot be clarified retrospectively in this case.

Hypersensitivity angiitis is an uncommon immune complex disease [11] which can occur together with systemic diseases [4]. It can be caused by bacterial substances [15] or medication [5]. In retrospective examination of the case, the authors hold the opinion that, in this case, the intravenous application of antibiotics during the patient's stay in hospital resulted in hypersensitivity angiitis.

Though the disease shows typical symptoms [6, 8, 16], which enable a differential diagnosis to be made with respect to other clinical pictures, it is often not considered in differential diagnoses, even where the symptoms are relatively typical, because it is so rarely encountered and its clinical picture is therefore relatively unknown. In cases with less-typical clinical signs, the diagnosis is sometimes only established by histological examination (biopsy material) [5] or by autopsy, as described here. Therapeutic action consists of guarding against the causal substances, administration of anti-inflammatory drugs [12], intravenous gamma globulin application and immunosuppressive therapy [3].

References

1. Buss H (1984) Blut- und Lymphgefäße. In: Remmele W (ed) Pathologie, vol 1. Springer, Berlin Heidelberg New York, pp 251–252
2. Burrows NP, Molina FA, Terenghi G, Clark PK, Haskard DO, Polak JM, Jones RR (1994) Comparison of cell adhesion molecule expression in cutaneous leucocytoclastic and lymphocytic vasculitis. *J Clin Pathol* 47:939–944
3. Gedalia A, Correa H, Kaiser M, Sorensen R (1995) Case report: steroid sparing effect of intravenous gamma globulin in a child with necrotizing vasculitis. *Am J Med Sci* 309:226–228
4. Gonzalez EB (1995) Arteriitis associated with systemic disease. *Coron Artery Dis* 6:207–212
5. Lie JT (1990) Illustrated histopathologic classification criteria for selected vasculitis syndromes. American College of Rheumatology Subcommittee on Classification of Vasculitis. *Arthritis Rheum* 33:1074–1087
6. Martinez-Taboada VM, Blanco R, Garcia-Fuentes M, Rodriguez-Valverde V (1997) Clinical features and outcome of 95 patients with hypersensitivity vasculitis. *Am J Med* 102:186–191
7. Ong AC, Handler CE, Walker JM (1988) Hypersensitivity vasculitis complicating intravenous streptokinase therapy in acute myocardial infarction. *Int J Cardiol* 21:71–73
8. Ratnam KV, Boon YH, Pang BK (1995) Idiopathic hypersensitivity vasculitis: clinopathologic, correlation of cases. *Int J Dermatol* 34:786–789
9. Remmele W (1984) Pathologie, vol 1. Springer, Berlin Heidelberg New York, pp 101–117
10. Riede UN, Schaefer HE (1995) Allgemeine und spezielle Pathologie. Thieme, Stuttgart, pp 934–935
11. Sams WM (1995) Human hypersensitivity angiitis, an immune complex disease. *J Invest Dermatol* 85 [Suppl 1]: 144–148
12. Sams WM (1989) Hypersensitivity angiitis. *J Invest Dermatol* 93 [Suppl 2]: 78–81
13. Singhal PC, Faulkner M, Venkatesan J, Molho L (1989) Hypersensitivity angiitis associated with naproxen. *Ann Allergy* 63:107–109
14. Tomino Y (1994) Hypersensitivity angiitis, Henoch-Schönlein-Purpura. *Nippon Rhinso* 52:2077
15. Weiss M, Schmidt M, Hess T, Mumenthaler M (1987) Extrapulmonary complications in Mycoplasma pneumoniae infections. *Dtsch Med Wochenschr* 112:1896–1901
16. Woss E, Neyer U (1988) Hypersensitivitätsangiitis nach Allopurinol-Therapie. *Fortschr Med* 106:729–731