

Stroke-Associated Stuttering

Arthur C. Grant, MD, PhD; Valerie Biousse, MD; Albert A. Cook, MD; Nancy J. Newman, MD

Objective: To present patients with stuttering speech in association with stroke.

Design: Case series with follow-up for 5 years, or until the stuttering resolved.

Setting: University and community hospital neurology wards, and ambulatory neurology clinics.

Patients: Four patients who developed stuttering speech in association with an acute ischemic stroke. A 68-year-old man acutely developed stuttering with a large left middle cerebral artery distribution stroke. A 59-year-old man who

had stuttered as a child began to stutter 2 months after a left temporal lobe infarction, as nonfluent aphasia was improving. Another childhood stutterer, a 59-year-old originally left-handed man developed severe but transient stuttering with a right parietal infarction. A 55-year-old man with a left occipital infarction had a right hemianopia and an acquired stutter, for which he was anosognosic.

Conclusion: The clinical presentation of stroke-associated stuttering is variable, as are the locations of the implicated infarctions.

Arch Neurol. 1999;56:624-627

THE APPEARANCE, "reappearance," and disappearance of stuttering speech in association with brain injury are rare and poorly understood. Stuttering has been described as a symptom of stroke in both the dominant¹⁻⁷ and nondominant^{2,5,8-10} hemispheres, and in all lobes except the occipital. We describe 4 cases of stuttering acquired in association with stroke. Two of the patients were former childhood stutterers. In another case the only lesion noted on brain magnetic resonance imaging (MRI) was in the occipital lobe. Moreover, this patient had anosognosia for his stutter.

complained of slurred speech but not of stuttering. An MRI of the brain 3 days after the event revealed a lesion in the left frontotemporoparietal region consistent with infarction (**Figure 1**). Four months later the stuttering and sensorimotor deficits had resolved, leaving only a mild dysarthria.

CASE 2

A 59-year-old right-handed man acutely developed nonfluent aphasia and mild right hemiparesis. Workup revealed new-onset atrial fibrillation. The aphasia was characterized by intact comprehension with impaired naming, repetition, and severely impaired fluency. An MRI of the brain 3 days after presentation showed a left posterior temporal and bilateral cerebellar subacute infarctions (**Figure 2**). Over the next few months the aphasia improved, although normal language was never achieved.

This patient had stuttered as a child, but had had normal speech for decades prior to the stroke. Two months after the infarction a severe stutter developed, and persisted during 5 years of follow-up. It was characterized by multiple repetitions and blocks predominantly on the first

REPORT OF CASES

CASE 1

A 68-year-old right-handed man presented with acute onset of mild right-sided weakness and difficulty speaking. On examination he was drowsy but responsive. He was dysarthric, with severe stuttering characterized by multiple repetitions and blocks. There was no aphasia. On the right there was a mild hemiparesis, mild sensory loss on the arm and face, and brisk reflexes. He

From the Departments of Neurology (Drs Grant, Biousse, Cook, and Newman) and Ophthalmology and Neurosurgery (Dr Newman), Emory University School of Medicine, Atlanta, Ga, and Hospital Saint-Antoine, Paris, France (Dr Biousse).

METHODS

Language was assessed with repeated bedside evaluation of comprehension, fluency, naming, and repetition, while speech was assessed during extended periods of casual conversation, and during singing, as indicated. Except as otherwise noted, handedness was determined using the 14 items of the Edinburgh handedness questionnaire with the highest validity.¹¹

phoneme or syllable of the first word in a phrase. Stuttering occurred with monosyllabic or polysyllabic words, and with initial vowel or consonant sounds. During singing of a familiar nursery rhyme the stutter was absent. Reading speech could not be tested because the patient was illiterate.

CASE 3

A 59-year-old man who had stuttered severely as a child awoke with unintelligible speech and a mild left facial droop. A few hours later he developed a severe stutter with multiple blocks and repetitions almost exclusively on first syllables of both monosyllabic and polysyllabic words. Language function was entirely intact. There was mild left facial weakness. Serial speech assessment revealed that by the following day the stutter had improved dramatically, and 1 week after the infarction his speech was normal. A computed tomographic scan of the head 2 days after the event demonstrated a small hypodensity in the right parietal cortex consistent with subacute infarction.

The patient had been left-handed as a child but was forced to write with his right hand when he entered grade school. As an adult he wrote and held a fork with his right hand, but still used his left hand for other activities.

CASE 4

Moments after a nighttime awakening, a 55-year-old right-handed man experienced a "rushing" sensation with tingling over the right side of his body, rapid concentric visual loss progressing to tunnel vision, and a bitemporal headache. After 2 minutes the symptoms resolved, except for the peripheral visual loss, which improved toward the left while the right visual field remained "dark." No cognitive changes, speech abnormalities, or weakness were noted by the patient.

Two weeks after the event a frequent stutter characterized by multiple repetitions was noted on examination. There were no other speech or language abnormalities. He was unaware of the stutter and was surprised to learn of its presence when asked about it, but stated that it must have occurred in association with the presenting event. He had been previously known as a dynamic and articulate speaker. Visual fields revealed

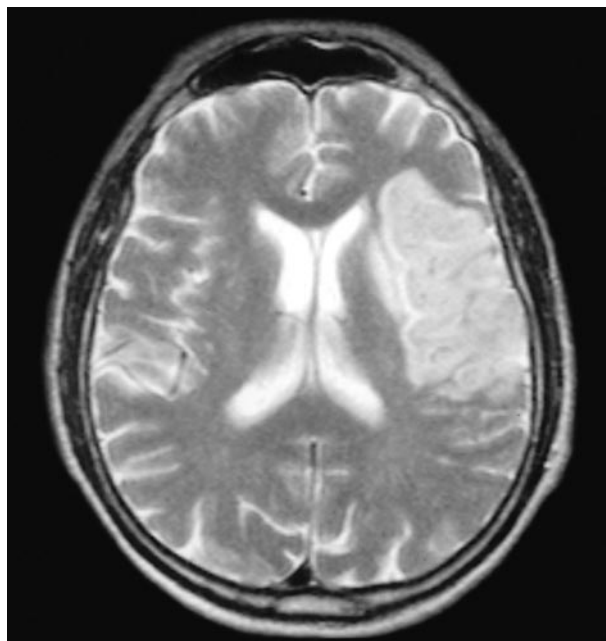


Figure 1. Axial T₂-weighted magnetic resonance imaging scan from patient 1 three days after his stroke showing increased signal in the left frontal and parietal lobes. Similar signal changes were seen in the left temporal lobe (not shown).

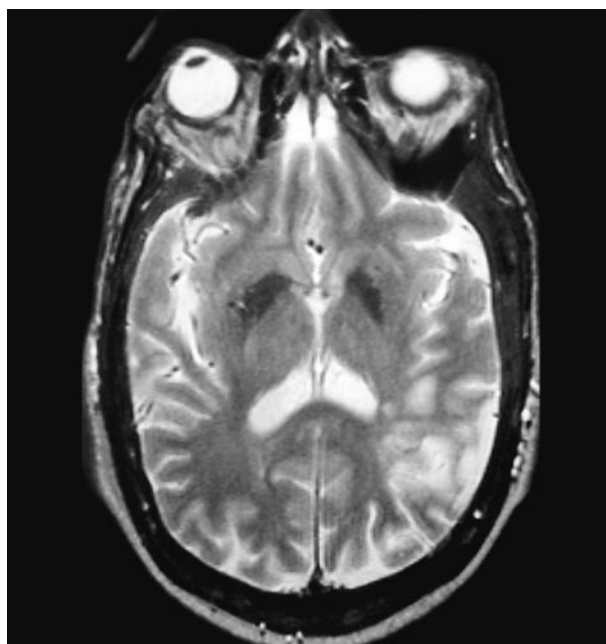


Figure 2. Axial T₂-weighted magnetic resonance imaging scan from patient 2 three days after his stroke illustrating increased signal in the left posterior parietal lobe. Similar signal changes were seen in both cerebellar hemispheres (not shown).

a congruous, macular-sparing, right homonymous hemianopia. Results of the remainder of his neurologic examination, including ocular motility and pupillary reactivity, were normal. An MRI of the brain 1 week later revealed signal changes along the medial left occipital lobe consistent with subacute infarction (**Figure 3**). One month after the stroke the stutter had resolved.

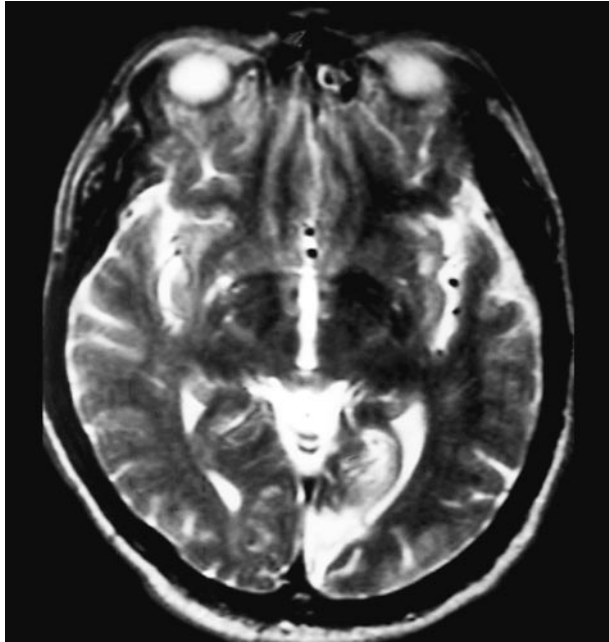


Figure 3. Axial T₂-weighted magnetic resonance imaging scan from patient 4 obtained 3 weeks after his stroke showing increased signal along the medial aspect of the left occipital lobe.

COMMENT

As opposed to developmental stuttering,^{12,13} which affects as many as 5% of preschool children,¹² acquired stuttering is rare. The distinction between acquired and developmental stuttering is phenomenologic: acquired stuttering occurs in association with a clear precipitating event. It has been described most commonly with stroke in both adults and children,¹⁻¹⁰ but head trauma¹ and even certain medications^{14,15} have been implicated. Retrospective group comparison of subjects with acquired or developmental stuttering has revealed frequent characteristic differences in the stutter qualities.^{1,16} For example, in the acquired group, stuttering is not restricted to initial sounds or syllables, can occur on monosyllabic as well as longer words, has no adaptation effect (does not improve with repeated reading of the same passage), continues during singing, and is rarely associated with secondary phenomena such as facial grimacing or fist clenching.^{1,16} Whether any of these differences, singly or in combination, is a reliable predictive test of stutter origin remains to be determined.

Given the diverse insults in both hemispheres that can produce acquired stuttering and the clinical variations in its presentation, it is unlikely that acquired stuttering reflects a specific focal cerebral dysfunction.^{1-10,14,15} Nonetheless, there appear to be some common features. Most cases of acquired stuttering result from injury to the dominant hemisphere, as was probably the case in our 4 patients. Our third patient had a right parietal lobe infarct, but he was left-handed as a child, and may well have been right-hemisphere dominant. When not a component of recovery from aphasia, as was the situation in case 2, stroke-associated stuttering usually, but not always, occurs acutely, as was true in our other 3 cases. In the 3 cases with transient stuttering the speech defect was

initially severe, but resolved substantially within days and completely within a few weeks to months. These cases demonstrate that acquired stuttering may occur with or without an associated aphasia or dysarthria, and may be transient or permanent.

Patients 2 and 3 had stuttered as children, decades before their respective strokes. Comprehensive analyses of the childhood stutters of these 2 patients were never made. However, the acquired stutter of patient 2 had qualities typical of both developmental^{12,13} and acquired stuttering. For example, the stutter vanished when the patient sang a familiar nursery rhyme, which is suggestive of developmental stuttering. Both patients 2 and 3 stuttered with monosyllabic and polysyllabic words, and did not have secondary phenomena features common to acquired stuttering. These 2 cases suggest that some former childhood stutterers with acquired stuttering may have a recurrence of their childhood stutter, while others may develop a fairly typical acquired type of stutter without many features commonly associated with developmental stuttering.

In similar cases other authors^{4,6} have generally assumed that a childhood stutter had reemerged with the stroke, as if the stroke “released” a learned inhibition of a lifelong stutter tendency,^{4,6} despite absence of a formal analysis of the stutter qualities. Indeed, arguments concerning genetics and stuttering, as well as hemispheric rivalry and dominance, have been made based on just this assumption. Until such detailed and comprehensive analysis is performed on those rare cases of acquired stuttering in former childhood stutterers, we urge caution in assuming that a lifelong stutter tendency is released in such patients, as opposed to the notion that the 2 events, ie, childhood developmental stuttering and adult-acquired stuttering, are coincidental.

Our fourth patient is most intriguing. The right side of the body sensory changes and concentric visual loss suggest that the initial area of ischemia was bilateral and substantially larger than the small, medial, left occipital infarct seen on MRI (Figure 3). The patient’s macular-sparing right homonymous hemianopia is accounted for by the stroke. With regard to stroke location and stutter, Rosenbek et al² stated that “The only innocent lobe to date appears to be the occipital.” No subsequent cases have challenged this occipital innocence until now. Although it is conceivable that the stutter represented a conversion reaction to the neurologic event, rather than a direct symptom of it (a theory of acquired stuttering that once had substantial popularity), this patient made no effort to bring the stutter to the attention of anyone else, and demonstrated no other unusual behaviors in coping with his stroke. It is possible that there was concurrent ischemia to more anterior brain regions, ie, the left posterior parietal lobe, a region well implicated in stroke-associated stutter. Indeed, such a mechanism is suggested by the brief but definite initial symptom of the right side of the body sensory abnormalities. The rapid resolution of the stutter is also consistent with this theory.

Another peculiar feature of case 4 was the patient’s unawareness of his new stutter. Patient 1 similarly did not specifically complain of stutter, although he noted difficulty speaking. While anosognosia for focal deficits is more common with right hemispheric lesions, it is not uncom-

mon with left hemisphere damage. The infarction in patient 1 was fairly large and extended into the parietal lobe (Figure 1). However, in case 4 there was absence of extra-occipital involvement, at least based on MRI.

The neural circuits underlying stuttering associated with brain injury remain unknown. The numerous regions of implicated cortex, and the peculiar phenomenon of stutter disappearance after closed head injury,⁶ carotid endarterectomy,³ and neurosurgical procedures¹⁷ suggest that the relationship between stuttering and brain anatomy and physiology is complex. The cases described herein highlight some common features of acquired stuttering and help to confirm previous hypotheses about this rare event. They also add some new insights, including that stroke-associated stutter can occur with an associated anosognosia, and may occur in association with an isolated occipital lobe lesion as demonstrated on MRI. Furthermore, acquired stuttering in adults who had also stuttered as children may or may not have features typical of childhood stuttering. Whether acquired stuttering in a former childhood stutterer truly represents a recurrence of the childhood stutter or is coincidental awaits further careful and detailed study of this rare phenomenon.

Accepted for publication July 24, 1998.

This study was supported in part by a departmental grant (ophthalmology) from Research to Prevent Blindness Inc, New York, NY.

Corresponding author: Nancy J. Newman, MD, 1365-B Clifton Rd, Atlanta, GA 30322.

- Helm NA, Butler RB, Benson DF. Acquired stuttering. *Neurology*. 1978;28:1159-1165.
- Rosenbek J, Messert B, Collins M, Wertz RT. Stuttering following brain damage. *Brain Lang*. 1978;6:82-96.
- Donnan GA. Stuttering as a manifestation of stroke. *Med J Aust*. 1979;1:44-45.
- Riggs JE, Nelson LJ, Lanham JE. Reemergence of stuttering after focal cerebral insult. *Arch Neurol*. 1983;40:260.
- Aram DM, Ekelman BL, Rose DF, Whitaker HA. Verbal and cognitive sequelae following unilateral lesions acquired in early childhood. *J Clin Exp Neuropsychol*. 1985;7:55-78.
- Helm-Estabrooks N, Yeo R, Geschwind N, Freedman M, Weinstein C. Stuttering: disappearance and reappearance with acquired brain lesions. *Neurology*. 1986;36:1109-1112.
- Nass R, Schreter B, Heier L. Acquired stuttering after a second stroke in a two-year-old. *Dev Med Child Neurol*. 1994;36:73-78.
- Fleet WS, Heilman KM. Acquired stuttering from a right hemisphere lesion in a right-hander. *Neurology*. 1985;35:1343-1346.
- Ardila A, Lopez MV. Severe stuttering associated with right hemisphere lesion. *Brain Lang*. 1986;27:239-246.
- Soroker N, Bar-Israel Y, Schechter I, Solzi P. Stuttering as a manifestation of right-hemispheric subcortical stroke. *Eur Neurol*. 1990;30:268-270.
- Raczkowski D, Kalat JW, Nebes R. Reliability and validity of some handedness questionnaire items. *Neuropsychologia*. 1974;12:43-47.
- Leung AKC, Robson WLM. Stuttering. *Clin Pediatr*. 1990;29:498-502.
- Perkins WH. What is stuttering? *J Speech Hear Disord*. 1990;55:370-382.
- Nurnberg HG, Greenwald B. Stuttering: an unusual side effect of phenothiazines. *Am J Psychiatry*. 1981;138:386-387.
- Meghji C. Acquired stuttering. *J Fam Prac*. 1994;39:325-326.
- Rosenfield DB, Viswanath NS, Callis-Landrum L, DiDanato R, Nudelman HB. Patients with acquired dysfluencies: what they tell us about developmental stuttering. In: Peters HFM, Hulstijn W, Starkweather CW, eds. *Speech Motor Control and Stuttering*. New York, NY: Elsevier Science Inc; 1991:277-284.
- Jones RK. Observations on stammering after localized cerebral injury. *J Neurol Neurosurg Psychiatry*. 1966;29:192-195.