

Peter Rene Mertens^a
Thomas Schönfelder^b
Stefan Handt^c
Horst Kierdorf^a
Hanns-Ulrich Marschall^b
Norbert Busch^b
Bernhard Heintz^a
Heinz-Günter Sieberth^a

^a Medical Clinic II,

^b III and

^c Institute of Pathology, University
of Aachen, Germany

Long-Term Extracorporeal Bilirubin Elimination: A Case Report on Cascade Resin Plasmapheresis

Abstract

Acute hepatic failure develops as a disease entity of rather diverse origin. With disease progression, toxic bilirubin levels may cause severe complications which include AV-nodal blockage, cardiac arrhythmia, impaired consciousness, generalized seizures, and status epilepticus. Treatment choices to prevent clinical deterioration comprise of costly and limited available orthotopic liver transplantation, utilization of extracorporeal bioartificial liver support devices and haemoperfusion/plasmapheresis treatment with activated charcoal/anion exchange filters. Here, we present a patient with acute drug-induced cholestatic hepatitis. Excessively elevated bilirubin levels were accompanied by cardiac and cerebral complications. Extracorporeal resin perfusion treatment (Plasorba, BR-350) was successfully performed over a 50-day period without activation of the coagulation system or side effects. Bilirubin levels were lowered to a minimum of 225 µmol/l, with concurrent clinical improvement. In conclusion, extracorporeal anion exchange plasmapheresis may be a viable long-term treatment for hyperbilirubinaemic side effects in overt cholestatic hepatitis.

Key Words

Hepatic failure
Hyperbilirubinaemia
Bioartificial liver
support device
Haemoperfusion
Plasmapheresis

Introduction

It is well recognized that sepsis, hepatitis, and severe inflammatory diseases are frequently associated with bilirubin and bile acid

elimination disorders [1–3]. As a result, elevated serum bilirubin levels may eventually lead to clinical hyperbilirubinaemic signs, consisting of impaired consciousness, generalized seizures, and cardiac arrhythmia. Fur-

KARGER

Fax +41 61 306 12 34
E-Mail karger@karger.ch
www.karger.com

© 1999 S. Karger AG, Basel
0253-5068/98/0166-0341\$17.50/0

Accessible online at:
<http://BioMedNet.com/karger>

Peter Rene Mertens, MD
Medizinische Klinik II, RWTH Aachen
Pauwelsstrasse 30
D-52057 Aachen (Germany)
Tel. +49 241 8089332, Fax +49 241 8888446

thermore, excessively hyperbilirubinaemic patients are prone to toxic renal failure, e.g. the hepatorenal syndrome [4–6]. The exact pathophysiologic mechanisms underlying these concurrent diseases remain unclear, although experimental studies implicate toxic bilirubin effects in disruption of cellular membranes [7] and in dysregulated oxygen metabolism [8]. Taking these findings together, it is not surprising that elevated serum bilirubin levels predict a poor outcome in acute liver failure, as demonstrated by O’Grady et al. [9].

Therapeutic choices with complicated cholestasis consist of the (a) costly and limited available orthotopic liver transplantation (OLT) [10]; (b) use of the bioartificial liver device [11–13], and (c) extracorporeal detoxification with activated charcoal or anion exchange resins [14–17]. Despite their relative universal availability, limited data are available concerning the long-term utility of extracorporeal bilirubin elimination by anion exchange resins. In this report, we describe a patient with (likely) drug-induced cholestasis and hyperbilirubinaemic systemic complications. Detoxification was achieved using cascade plasmapheresis through activated charcoal and anion exchange filters. Emphasis has been put on clinicohistopathological findings, bilirubin elimination efficiencies, side effects and possible long-term applicability in comparison to alternative extracorporeal elimination methods.

Case Report

A 40-year-old morbidly obese woman (weight 124 kg, height 171 cm) was admitted to an outlying hospital with dyspnoea, right lower extremity erythema, and oedema. Her past medical history was significant for recurrent episodes of bilateral lower extremity deep vein thrombosis and asymptomatic cholecystolithiasis. She was the mother of 3 healthy children, which were

delivered by cesarean section. Diagnosis of deep vein thrombosis and pulmonary embolism was confirmed with Doppler studies of the legs and ventilation perfusion scanning of the lungs. She developed pulmonary infarction, pneumonia with septicaemia and disseminated intravascular coagulation, and was transferred to the intensive care unit (ICU) for respiratory support. In addition to respiratory failure, acute oligoanuric renal failure developed. Therapy of sepsis included broad spectrum antibiotics (using piperazine, clavulanic acid, tobramycin), infusion of fresh frozen plasma, and antithrombin III replacement. Initially, high doses of vasopressors were required to maintain sufficient blood pressure.

Her bilirubin was elevated on admission (90 $\mu\text{mol/l}$), and rose steadily to >1,000 $\mu\text{mol/l}$ from day 22 to day 70 of treatment in the ICU. Eighty percent of the bilirubin was conjugated. Both obstructive cholestasis and infectious hepatitis were excluded (by abdominal ultrasound/ERCP and negative serology for hepatitis A, B, C and D; CMV; EBV, respectively). We concluded that drug-induced liver toxicity was the most likely cause for this patient’s intrahepatic cholestasis [18]. Since the patient’s first admission, several putative causative drugs including omeprazole, ranitidine, doxycycline and erythromycin [19–25] had been administered. In the further treatment, notoriously hepatotoxic drugs were avoided. Ursodeoxycholic acid, a hydrophilic bile acid with possible beneficial effects on cholestasis, was administered via a nasogastric tubing over 7 days ($3 \times 250 \text{ mg/day}$) without clinical improvement. Third-degree atrioventricular block and low blood pressure developed when bilirubin levels exceeded 560 $\mu\text{mol/l}$, and a temporary cardiac pacemaker was inserted.

Charcoal Filter Plasmapheresis

On day 70, persisting generalized tonic-clonic seizures developed, although treatment with benzodiazepines and phenytoin had previously been initiated. Convulsions were thought to be the result of excessively elevated bilirubin levels (>1,000 $\mu\text{mol/l}$). In the following 29-day period, 17 haemoperfusion treatments were performed using activated charcoal filters (Haemosorba, CH 350; Asahi Medical, Japan), each for 5 h at a blood flow rate of 180 ml/min. Anticoagulation was achieved by heparin infusion, which was adjusted according to activated clotting time (range 120–140 s). Seizures ceased when bilirubin levels fell below 800 $\mu\text{mol/l}$. Bilirubin levels were eventually lowered to a minimum of 390 $\mu\text{mol/l}$. At this time, fibrin split products appeared, and fibrinogen levels and thrombocyte counts (109,000/ μl) dropped, most likely as a side

effect of plasma charcoal contact. Treatment was discontinued when the patient developed a biparietal subdural bleed. A neurosurgical intervention was not necessary due to the nonprogressive character of the bleed and lack of increased intracranial pressure.

Cascade Filtration with Plasmaseparation and Plasmaperfusion

Without extracorporeal bilirubin elimination treatment, bilirubin levels resumed to a new peak value exceeding 1,500 $\mu\text{mol/l}$ within a week with recurrence of generalized seizures and third-degree atrioventricular blockage. Seizures continued despite phenytoin treatment. Additional measures were required for the treatment of status epilepticus, which lasted for more than 36 h. At this time, cascade plasma separation (Plasmaflux membrane P-2-S; Fresenius, Bad Homburg, Germany) and plasmaperfusion (Plasorba, BR-350; Asahi Medical, Japan) was started. These filters consist of 0.45- μm cellulose acetate membranes that permit plasma contact to styrol-divinyl-copolymer resin. Cascade resin plasmaperfusion time was 4–8 h with blood flow and plasma flow rates at 120–150 and 20–30 ml/min, respectively. Anticoagulation was achieved by heparin infusion, with activated coagulation time adjusted to 140 s. During the following 50 days, cascade filtration was performed 42 times without activation of the coagulation cascade, as indicated by the absence of fibrin split products/D-dimers and stable thrombocyte counts. After the first two treatments, generalized seizures resolved and the patient regained full consciousness without cognitive impairment. Similarly, cardiac arrhythmias were no longer detectable. Serum bilirubin levels were measured at 30-min intervals during treatment, as shown in table 1. During one 8-hour treatment, bilirubin levels were lowered by 212 $\mu\text{mol/l}$ at the most, with a minimum serum bilirubin level of 222 $\mu\text{mol/l}$ (fig. 1).

Determination of Bile Acids in Serum and Filter Eluates

Serum bile acids were determined hourly by standard enzymatic methods (Merckotest 14352; E. Merck, Darmstadt, Germany) before, during and after plasmaperfusion treatment. Serum bile acid levels were elevated excessively up to 143 $\mu\text{mol/l}$ (normal range 0–5). During plasmaperfusion treatment, bile acid levels fluctuated and showed no trend towards reduction (table 1). In addition, resin filters were eluted with methanol posttreatment. These eluates did not contain bile acids.

Table 1. Serum bilirubin and systemic bile acid levels during an 8-hour treatment by cascade plasma resin perfusion

Time, h	Total bilirubin $\mu\text{mol/l}$	Conjugated bilirubin $\mu\text{mol/l}$	Bile acid $\mu\text{mol/l}$
0	515	446	117
0.5	514	457	
1	492	436	124
1.5	487	420	
2	433	381	118
2.5	454	401	
3	431	378	85
3.5	398	354	
4	402	349	112

Serum bilirubin and bile acid levels were measured during a 4-hour period while extracorporeal treatment with resin filter plasmaperfusion (BR-350) was performed.

Clinical Course

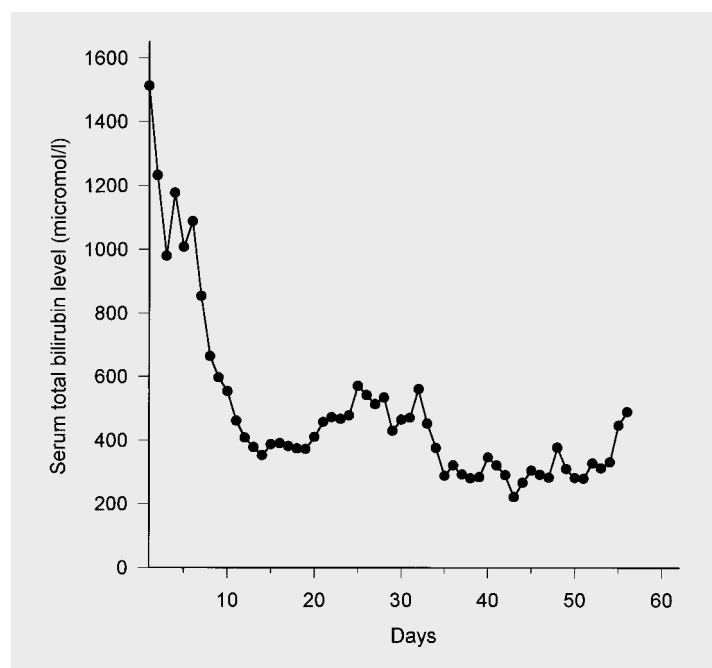
After 151 days in the ICU, the patient's condition deteriorated with respiratory insufficiency, requiring endotracheal intubation and assisted ventilation. Chest X-rays revealed recurrent bilateral pneumonic infiltrates, which were refractory to antibiotics. Subsequently, overt septicemia developed and the patient expired due to shock on ICU day 158.

Autopsy

The liver was of grey-green colour and weighed 3,700 g. Microscopic examination demonstrated a focal fatty liver with disseminated intracellular green-brown pigment, predominantly within hepatocytes (fig. 2). Iron staining revealed large amounts of haemosiderin. Minimal neutrophilic and lymphocytic cellular infiltrates were found in portal tracts and lobular zones. Fibrotic and cirrhotic changes were absent, and bile ducts were normal in number. The hepatic zonular architecture was completely intact, however (fig. 3).

The heart was brownish-yellow in colour. Microscopically, it contained large amounts of coarse bile pigment in the extracellular space (fig. 4). Focal tissue damage was apparent, indicative of cellular necrosis. Iron staining was negative. Lungs were remarkable for alveolar septal thickening, oedema and pneumonic infiltrates without detectable organisms.

Fig. 1. Serum bilirubin levels were measured in daily intervals. The graph starts at the time of initiation of resin plasmapheresis therapy. Plasmapheresis is repeated 42 times during a 50-day period. Cardiac arrhythmias and grand mal seizures ceased on day 10, with serum bilirubin levels lowered to 540 $\mu\text{mol/l}$.



Discussion

OLT has greatly improved the outcome of fulminant hepatic failure [10], but limited resources have restricted this therapy to a relatively small number of patients. The need for organs has led to the search for alternative treatment modalities. Xenograft transplantation has been performed with discouraging results because of severe hyperacute rejections [26]. As a consequence, the focus of recent research has been the development of liver support systems. These are designed as a bridging therapy for patients while awaiting organs for transplantation, or in cases with potentially reversible liver injury, until recovery of liver function. In this respect, reports on hybrid bioartificial liver support device (BLSD) development give a promising outlook [13, 27, 29]. BLSD consist of encapsulated allogeneic and xenogeneic matrix-bound

hepatocyte cultures [29, 30] that enable liver microstructural organization, which is critical for optimal bioartificial function. Furthermore, recent approaches include matrix-induced liver cell aggregate/spheroid formation using collagen-coated beads as a nidus [11, 31]. Most importantly, matrix-bound hepatocytes retain polarity, gap junctions, and bile canaliculi and might therefore fulfil complex, even unidentified, detoxification pathways. The use of semipermeable membranes with molecular weight cut-offs ranging from 50,000 to 100,000 has proven an efficient immunoisolation barrier to immunocompetent proteins and cells, allowing for the use of xenogeneic cells. Drawbacks of BLSD include difficulties with long-term maintenance of hepatocyte function, the potential for xenozoonosis, limited supply of human hepatocytes, as well as with the high costs incipient in cell isolation from mammalian liver. One obstacle to

Fig. 2. Liver needle biopsy. HE. $\times 100$. Bile accumulation is mainly found in acinar zone three. The distribution of steatosis is patchy.

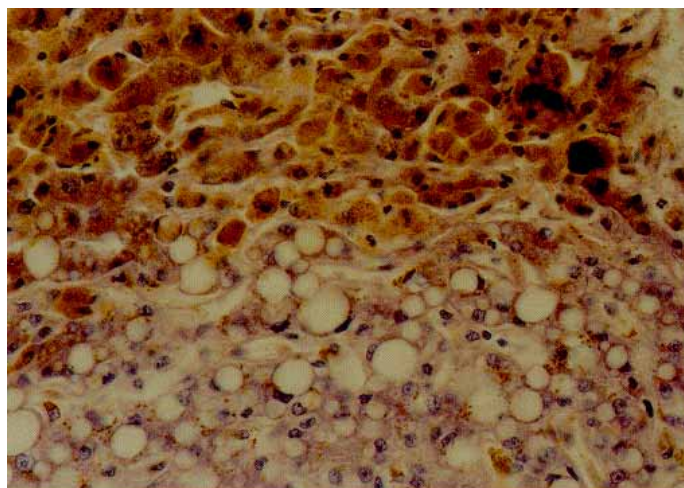


Fig. 3. Liver needle biopsy. HE. $\times 400$. Centrolobular hepatocytes (zone 3) are present with intracytoplasmatic bile accumulation. This zone is clearly demarcated from an area with hepatocytes containing fat vacuoles.

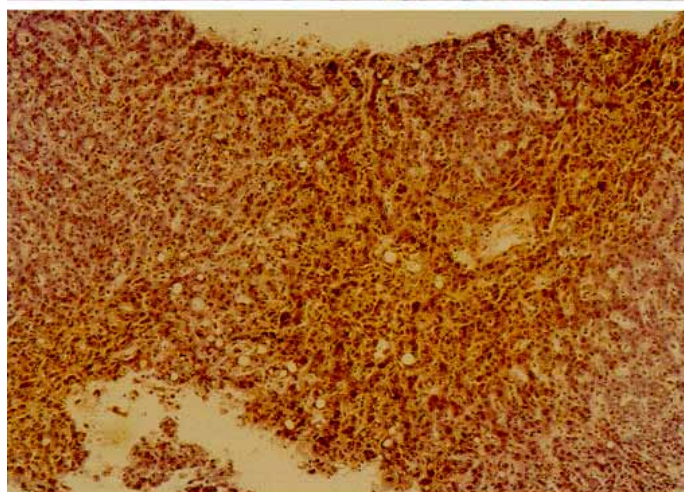
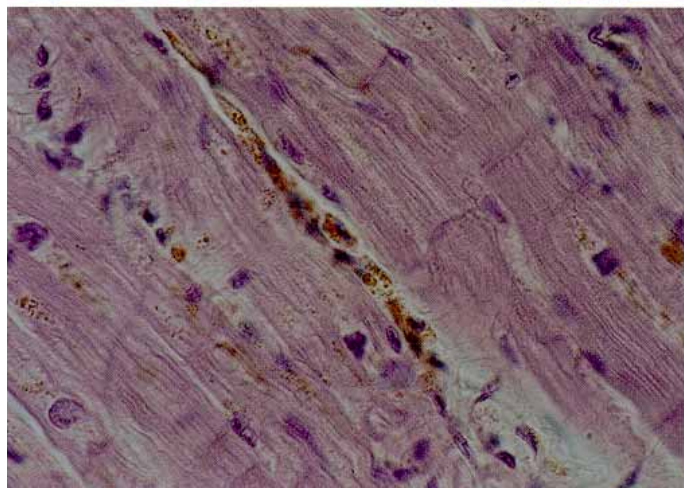


Fig. 4. Needle biopsy from left heart tissue. HE. $\times 630$. Cardiomyocytes containing lipofuscin with interspersed bile-laden phagocytic cells in the interstitium.



the general availability of these devices may be overcome with the establishment of immortalized liver cell cultures that perform most liver functions [32]. A major concern regarding this approach is that these cells derive from malignant cell lines with tumorigenic potential. However, clinical studies to evaluate the efficiency and side effects of BLSD have mostly yielded unsatisfactory results [32–35]. The only study until now demonstrating encouraging results with the use of a porcine hepatocyte BLSD was reported by Watanabe et al. [36] and will be followed by a randomized controlled prospective multicentre trial (phase II–III).

The effect of charcoal haemoperfusion therapy on survival from fulminant liver failure has been previously evaluated in a controlled clinical trial by O'Grady et al. [14]. In this unique study, a total of 135 patients with a broad range of liver diseases were enrolled. As the most significant results, no survival differences were apparent between haemoperfusion and intensified conservative treatment groups, and disease outcome was mainly influenced by the primary cause of liver failure. Criticism concerning this study focused on the possibility of a type II statistical error, although more than 100 patients were enrolled. In addition to this study and the one by Hughes et al. [17], few data on clinical trials and differences of adsorbent efficiencies are available.

The finding of prolonged clinical stabilization of a patient with severe cholestatic hepatitis supports the notion that this therapeutic approach may be beneficial in bridging patients. This effect is remarkable in that absorption therapy with resin filter plasmapheresis only partially substitutes for hepatocyte functions. It does not substitute for complex hepatic detoxification functions which require biotransformation. Neuberger [21] and Kaplowitz et al. [22] have reported that

drug-induced cholestatic hepatitis may persist for up to 1 year. In our present case, charcoal filter treatment led to activation of the coagulation cascade, thrombocytopenia and the development of an intracranial bleed. In contrast, resin filters may have the advantage of superior biocompatibility compared to charcoal filters with equal efficiency in bilirubin removal. In the presented case, the resin filter did not activate the coagulation system, as demonstrated by normal thrombocyte counts and the absence of fibrin split products. Bilirubin levels during treatment were 225 $\mu\text{mol/l}$ at their lowest. The inability to lower bilirubin further may be due to the relative balance between bilirubin synthesis, redistribution and extracorporeal elimination. Another explanation for this incomplete elimination may be that only negatively charged, hydrophilic β - and γ -bilirubin fractions are quantitatively bound by BR-350 resin filters [37]. The lipophilic δ -bilirubin fraction remains covalently bound to albumin [16] and demonstrates only low affinity resin binding. Conjugated and unconjugated bilirubin was equally eliminated [16]. Concomitantly, elevated bile acids may have contributed to the perpetuating liver damage [38]. Interestingly, and contrary to previous reports, efficient elimination of bile acids was not achieved using plasmapheresis.

Heparin was efficient during plasmapheresis to prevent filter clotting and does not increase intrathecal pressure. As such, its use as an anticoagulant is preferable to prostaglandin analogues, e.g. prostacyclin, which can raise intracranial pressure [39]. In addition, prostaglandin analogues may decrease systemic mean arterial pressure [39], which can be especially disadvantageous with cardiac failure. In the present case, transient clinical improvement correlated well with bilirubin elimination. Despite the poor overall outcome from multiple organ failure and septic

caemia [40], when compared to treatment with charcoal filters, long-term cascade filtration with resin plasmapheresis was both effective and well tolerated.

We conclude that larger prospective studies are warranted to study limited plasmapheresis/resin bilirubin elimination in the treatment of acute cholestatic liver disorders.

References

- 1 Miller D, Keeton G, Webber B, Saunders S: Jaundice in severe bacterial infections. *Gastroenterology* 1976;71:1799–1805.
- 2 Green RM, Beier D, Gollan JL: Regulation of hepatocyte bile salt transporters by endotoxin and inflammatory cytokines in rodents. *Gastroenterology* 1996;111:193–198.
- 3 Green RM, Whiting JF, Rosenbluth AB, Beier D, Gollan JL: Interleukin-6 inhibits hepatocyte taurocholate uptake and sodium-potassium-adenosinetriphosphatase activity. *Am J Physiol* 1994;267:G1094–G1100.
- 4 Dawson JL: Acute postoperative renal failure in obstructive jaundice. *Ann R Coll Surg Engl* 1968;42:163–170.
- 5 Kew MC, Brunt PW, Varma RR, Hourigan KJ, Williams HS, Sherlock S: Renal and intrarenal blood flow in cirrhosis of the liver. *Lancet* 1971;2:504–510.
- 6 Papper S: Hepatorenal syndrome; in Epstein M (ed): *The Kidney in Liver Disease*, ed 2. New York, Elsevier Biomedical, 1983, pp 87–106.
- 7 Cowger ML, Labbe RF: Bilirubin toxicity in cultured mammalian cells. *Fed Proc* 1964;23:233–238.
- 8 Wiessman G: Studies of lysosomes. IV. The effect of neutral steroids and bile acids on lysosomes in vitro. *Biochem Pharmacol* 1965;14:525–529.
- 9 O'Grady JG, Alexander GJ, Hayllar KM, Williams R: Early indicators of prognosis in fulminant hepatic failure. *Gastroenterology* 1989;97:439–445.
- 10 Ascher NL, Lake JR, Emond JC: Liver transplantation for fulminant hepatic failure. *Arch Surg* 1993;128:677–682.
- 11 Kong LB, Chen S, Demetriou AA, Rozga J: Matrix-induced liver cell aggregates for bioartificial liver use. *Int J Artif Organs* 1996;19:72–78.
- 12 Rozga J, Demetriou AA: Artificial liver. Evolution and future perspectives. *ASAIO J* 1995;41:831–837.
- 13 Gerlach JC: Development of a hybrid liver support system: A review. *Int J Artif Organs* 1996;19:645–654.
- 14 O'Grady JG, Gimson AES, O'Brien CJ, Pucknell A, Hughes RD, Williams R: Controlled trials of charcoal hemoperfusion and prognostic factors in fulminant hepatic failure. *Gastroenterology* 1988;94:1186–1192.
- 15 Suenaga M, Yoshikatsu O, Sugiura H, Kokuba Y, Uehara S, Mori K, Yamaguchi S, Yamanaka N, Oda O: Effect of therapeutic plasma exchange and bilirubin adsorption on serum bilirubin subfractions in hepatic failure. *Ther Plasmapher* 1993;12:175–179.
- 16 Geiger H, Klepper J, Lux P, Heidland A: Biochemical assessment and clinical evaluation of a bilirubin adsorbent column (BR-350) in critically ill patients with intractable jaundice. *Int J Artif Organs* 1992;5:35–39.
- 17 Hughes RD, Pucknell A, Routley D, Langley PG, Wendon JA, Williams R: Evaluation of the BioLogic-DT sorbent-suspension dialyser in patients with fulminant hepatic failure. *Int J Artif Organs* 1994;17:657–662.
- 18 Lee MG, Hanchard B, Williams NP: Drug-induced acute liver disease. *Postgrad Med J* 1989;65:367–370.
- 19 Jochem V, Kirkpatrick R, Greenson J, Brogan M, Sturgis T, Cook-Glen C: Fulminant hepatic failure related to omeprazole. *Am J Gastroenterol* 1992;87:523–525.
- 20 Hautekeete ML: Hepatotoxicity of antibiotics. *Acta Gastroenterol Belg* 1995;58:290–296.
- 21 Neuberger J: Drug-induced jaundice. *Gastroenterology* 1989;3:447–466.
- 22 Kaplowitz N, Aw TY, Simon FR, Stolz A: Drug-induced hepatotoxicity. *Ann Intern Med* 1984;104:826–839.
- 23 Vial T, Goubier C, Bergeret A, Cabrera F, Evreux JC, Descotes J: Side effects of ranitidine. *Drug Saf* 1991;6:94–117.
- 24 Lienart F, Morissens M, Jacobs P, Ducobu J: Doxycycline and hepatotoxicity. *Acta Clin Belg* 1992;47:205–208.
- 25 Gholson CF, Warren GH: Fulminant hepatic failure associated with intravenous erythromycin lactobionate. *Arch Intern Med* 1990;150:215–216.
- 26 Makowka L, Cramer DV, Hoffman A, Breda M, Sher L, Eiras-Hreha G, Tusio PJ, Yasunaga C, Cosenza CA, Cosenza CA, Wu GD, Chapman FA, Podesta L: The use of a pig liver xenograft for temporary support of a patient with fulminant hepatic failure. *Transplantation* 1995;59:1654–1659.
- 27 Nyberg SL, Peshwa MV, Payne WD, Hu WS, Cerra FB: Evolution of the bioartificial liver: The need for randomized clinical trials. *Am J Surg* 1993;166:512–521.
- 28 Nyberg SL, Misra SP: Hepatocyte liver-assist systems – A clinical update. *Mayo Clin Proc* 1998;73:765–771.
- 29 Matthew HW, Basu S, Peterson WD, Salley SO, Klein MD: Performance of plasma-perfused, microencapsulated hepatocytes: prospects for extracorporeal liver support. *J Pediatr Surg* 1993;28:1423–1427.

- 30 Rozga JR, Holzman MD, Ro M-S, Griffin DW, Neuzil DF, Giorgio T, Moscioni AD, Demetriou AA: Development of a hybrid bioartificial liver. *Annals Surg* 1993;217:502–511.
- 31 Gerlach J, Encke J, Hole O, Muller C, Courtney J, Neuhaus P: Hepatocyte culture between three dimensional arranged biomatrix-coated independent artificial capillary systems and sinusoidal endothelial cell coculture compartments. *Int J Artif Organs* 1994;17:301–306.
- 32 Sussmann NL, Gislason G, Conlin CA, Kelly JH: The Hepatix extracorporeal liver assist device: Initial clinical experience. *Artif Organs* 1994;18:390–396.
- 33 Catapano G: Mass transfer limitations to the performance of membrane bioartificial liver support devices. *Int J Artif Organs* 1996;19:18–35.
- 34 Rozga J, Podesta L, LePage E, Morisani E, Moscioni AD, Hoffman A, Sher L, Villamil F, Woolf G, McGrath M, Kong L, Rosen H, Lanman T, Vierling J, Makowka L, Demetriou AA: A bioartificial liver to treat severe acute liver failure. *Ann Surg* 1994;5:538–546.
- 35 Ellis AJ, Hughes RD, Wendon JA, Dunne J, Langley PG, Kelly JH, Gislason GT, Sussman NL, Williams R: Pilot-controlled trial of the extracorporeal liver assist device in acute liver failure. *Hepatology* 1996;24:1446–1451.
- 36 Watanabe FD, Mullon CJ, Hewitt WR, Arkadopoulos N, Kahaku E, Eguchi S, Khalili T, Arnaout W, Shackleton CR, Rozga J, Sobmon B, Demetriou AA: Clinical experience with a bioartificial liver in the treatment of severe liver failure: A phase I clinical trial. *Ann Surg* 1997;225:484–491.
- 37 Wu TW: Bilirubin analysis – state of the art and future prospects. *Clin Biochem* 1984;17:221–229.
- 38 Schiff L, Schiff ER: *Diseases of the Liver*, ed 7. Philadelphia, Lippincott, 1993.
- 39 Davenport A, Will EJ, Davison AM: Adverse effects on cerebral perfusion of prostacyclin administered directly into patients with fulminant hepatic failure and acute renal failure. *Nephron* 1991;59:449–454.
- 40 Hawker F: Liver dysfunction in critical illness. *Anaesth Intensive Care* 1991;19:165–181.