

## Cerebral Venous Thrombosis in Patients with Nephrotic Syndrome

### Case Reports

Sheng-Feng Sung, MD  
Jiann-Shing Jeng, MD  
Ping-Keung Yip, MD  
and Kou-Mau Huang, MD\*

TAIPEI, TAIWAN

---

#### ABSTRACT

The authors describe two cases of cerebral venous thrombosis (CVT) in patients with nephrotic syndrome. The main clinical features of CVT were persistent headache, hemiparesis, and seizure, and the diagnosis was based on magnetic resonance imaging and magnetic resonance angiography. Both showed acquired deficiency of free protein S. The neurologic symptoms remained stationary in the first patient, who received no anticoagulation therapy, but resolved rapidly in the second, treated with intravenous heparin and supplemented with fresh frozen plasma. CVT should be suspected in patients with nephrotic syndrome who present with symptoms of intracranial hypertension or any focal neurologic deficit.

---

From the Departments of Neurology and \*Radiology, National Taiwan University Hospital, Taipei, Taiwan.

©1999 Westminster Publications, Inc., 708 Glen Cove Avenue, Glen Head, NY 11545, U.S.A.

*Introduction*

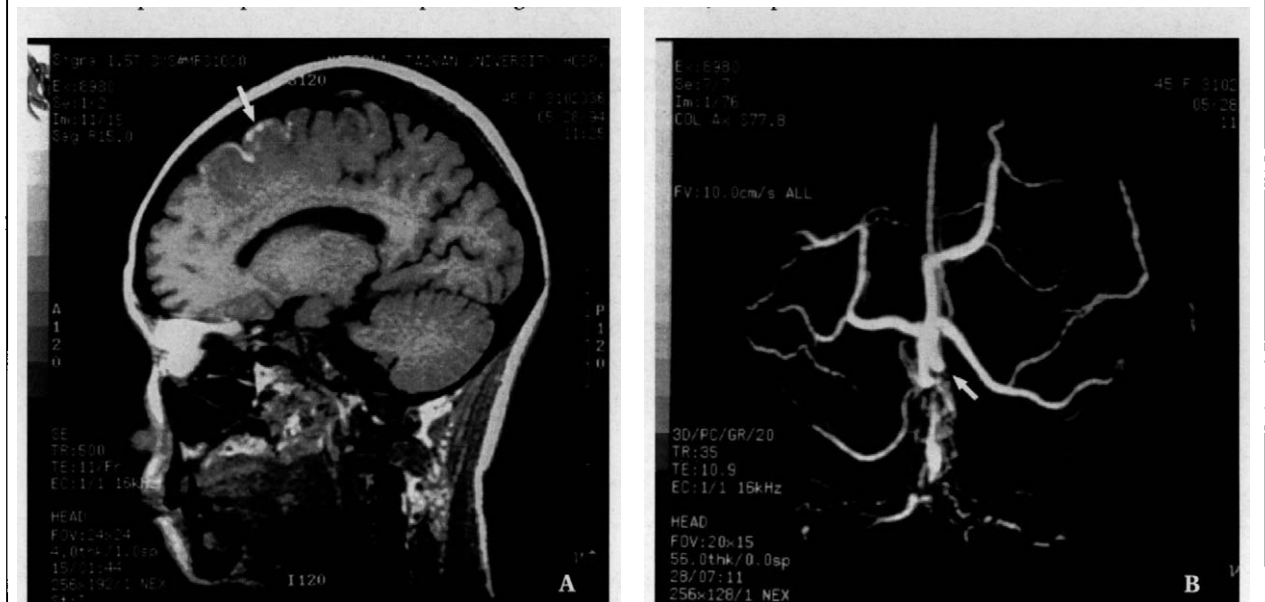
The association between nephrotic syndrome and thromboembolic complications is well established.<sup>1,2</sup> The overall incidence of renal vein thrombosis in patients with nephrotic syndrome is 35% and that of thromboembolism other than renal vein thrombosis (including deep vein thrombosis, pulmonary embolism, cerebral infarction, and peripheral arterial thrombosis) is 20%.<sup>2</sup> However, cerebral venous thrombosis (CVT) has been rarely reported in patients with nephrotic syndrome. Over a period of 12 years (1984–1995), 38 patients, aged 15 years and over, with CVT documented by conventional angiography or magnetic resonance imaging (MRI)/angiography (MRA) were seen in our hospital. In two of them, the etiology of CVT was probably a hypercoagulable state secondary to nephrotic syndrome.

*Case Reports*

*Case 1.* A 45-year-old woman had sustained progressive left-sided weakness, accompanied by per-

sistent headache, for 3 days and was transferred to our hospital 2 weeks after onset. Her medical history showed hypertension and hypoalbuminemia over the previous 2 months. She did not take oral contraceptives. The family history was unremarkable. On arrival, vital signs and physical examination produced normal findings except for pitting edema in the lower legs. Neurologic examination showed left hemiparesis and decreased sensory perception on the left side. MRI demonstrated an area of abnormal signal intensity in the right frontal region and thrombosis of the superior sagittal sinus (Figure 1A). MRA confirmed thrombosis of the superior sagittal sinus with establishment of collateral circulation (Figure 1B). Routine blood biochemistry results were normal, except for hypercholesterolemia and hypoalbuminemia (24 g/L, normal 37–52). The 24-hour urine protein content was 3 g. Coagulation studies, including prothrombin time, partial thromboplastin time, thrombin time, fibrinogen, antithrombin III, protein C, total protein S, and plasminogen yielded normal results, except for a slightly lowered free protein S level (71%, normal 75%–136%). Antinuclear antibody titers were mildly elevated

**Figure 1.** **A.** Parasagittal T1-weighted image shows low signal intensity in the right frontal region with high signal intensity along the gyri (arrow) indicating petechial hemorrhage. **B.** Axial three-dimensional phase contrast magnetic resonance angiography reveals frayed appearance in the posterior portion of the superior sagittal sinus (arrow) and prominent cortical veins.



(320×). Serum complements were normal. Anticardiolipin antibody were negative for both immunoglobulin G (IgG) and IgM.

A renal biopsy, taken 1 month after admission, demonstrated chronic tubulointerstitial nephritis. Prednisolone (100 mg on alternate days) was initially prescribed, and the proteinuria gradually decreased. She was maintained on aspirin and low-dose prednisolone and has remained stable for 2 years.

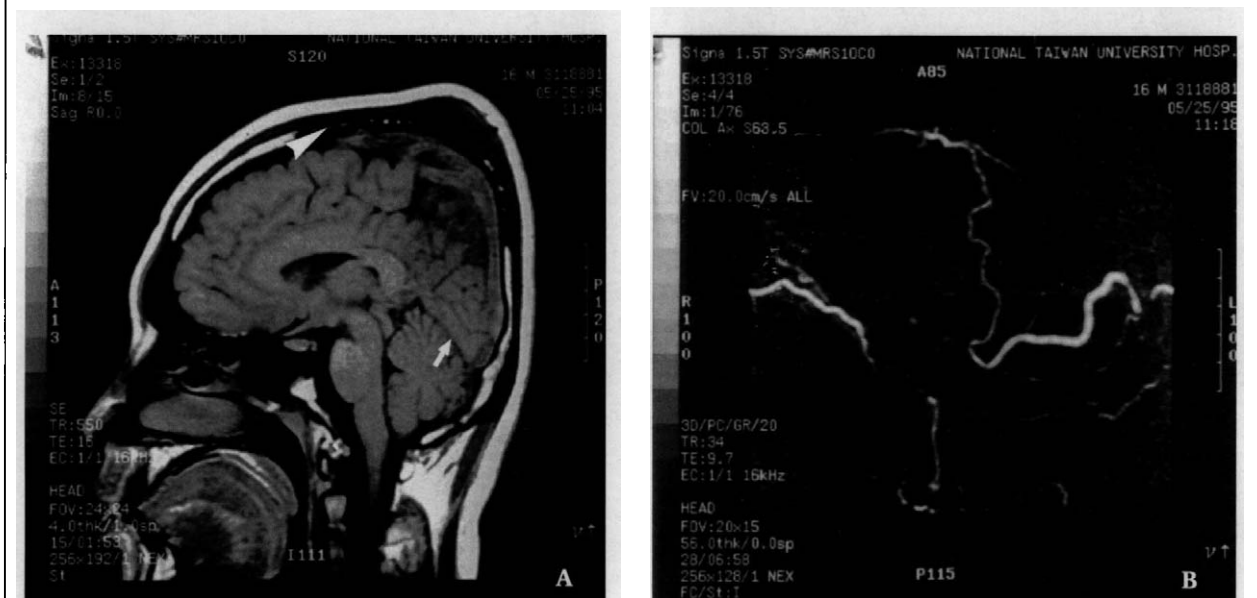**Case 2.** A 16-year-old man was admitted to our hospital because of a 5-day history of headache, nausea, and vomiting, followed by an episode of generalized seizure. A diagnosis of nephrotic syndrome had been made 7 months earlier, and he had received corticosteroid therapy; otherwise his medical history was not remarkable. Upon initial evaluation, he was afebrile with normal vital signs. Physical examination revealed mild peripheral edema. No abnormal neurologic signs were present.

MRI demonstrated thrombosis in the superior sagittal sinus, straight sinus, and bilateral lateral sinuses (Figure 2A). MRA confirmed

absence of flow in the straight sinus and superior sagittal sinus (Figure 2B). The levels for blood urea nitrogen, creatinine, and total cholesterol were elevated. Serum albumin concentration was decreased to 14 g/L. The 24-hour urine protein loss was 24 g. Complete blood counts, electrolytes, other blood chemistry parameters, antinuclear antibody, and serum complements yielded normal results. He had normal levels of fibrinogen, total protein S, and protein C. Plasminogen activity was 66% (normal 74%–134%). Free protein S content was decreased to 66%, functional protein S activity to 51% (normal 72%–124%), and antithrombin III to 56% (normal 76%–135%). The prothrombin time and partial thromboplastin time were normal, but the thrombin time was prolonged. Lupus anticoagulant was negative. Anticardiolipin antibody levels were increased for IgM and negative for IgG.

He was initially treated with intravenous heparin and fresh frozen plasma to replace antithrombin III, then was gradually shifted to oral warfarin. Glycerol was administered to relieve intracranial hypertension. Pulse therapy with

**Figure 2.** **A.** Midsagittal T1-weighted image shows slightly heterogeneous iso- to low-signal intensity along the straight sinus (arrow) and the posterior two thirds of the superior sagittal sinus (arrowhead). **B.** Axial three-dimensional phase contrast magnetic resonance angiography shows complete loss of flow signal from the superior sagittal sinus.



**Table I**  
 Summary of Adult Cases of Cerebral Venous Thrombosis Associated with Nephrotic Syndrome

Authors	Age/Sex	Clinical Features	Site of Venous Occlusion	Protein S	Other Coagulation Profiles
<b>Reported cases</b>					
Levine et al <sup>9</sup>	32/M	Headache, left trochlear palsy	SSS and <b>SS</b>	NA	Positive lupus anticoagulant
Tovi et al <sup>10</sup>	46/M	Swelling of right arm and cervical area	Right LS	NA	Increased fibrinogen
Burns et al <sup>11</sup>	20/M	Personality change, seizure, coma	SSS	NA	Decreased AT III
	35/M	Headache, left oculomotor palsy	SSS	Normal	Increased fibrinogen
	17/M	Headache, seizure	<b>SSS</b>	Normal	Increased fibrinogen, von Willebrand factor, decreased AT III
Laversuch et al <sup>12</sup>	42/F	Headache, confusion, seizure	<b>Right LS</b>	Decreased free PS	
<b>Present series</b>					
Case 1	45/F	Headache, left hemiparesis	SSS	Decreased free PS	
Case 2	16/M	Headache, seizure	SSS and SS	Decreased free PS and functional PS	Decreased AT III, plasminogen, positive anticardiolipin antibody

AT III: antithrombin III; LS: lateral sinus; NA: not available; PS: protein S; SS: straight sinus; SSS: superior sagittal sinus.

methylprednisolone (1,000 mg three times a day on alternate days) was used to treat his nephrotic syndrome. The response was favorable, with resolution of the peripheral edema and improvement of the proteinuria. A follow-up MRI and MRA 2 weeks later showed partial recanalization of the thrombosed sinuses. He has now been well during 8 months of outpatient follow-up.

### Discussion

Nephrotic syndrome is associated with a hypercoagulable state, resulting in venous or arterial infarction of various organs.<sup>2</sup> Several disorders of hemostasis have been demonstrated in patients with nephrotic syndrome, including thrombocytosis and platelet hyperaggregability; increased plasma levels of factors V, VII, VIII, X, and XIII and fibrinogen; hyperviscosity of blood; lowered fibrinolytic activity; and decreased plasma concentrations of natural anticoagulants, such as free protein S and antithrombin III.<sup>2-5</sup> The mechanisms responsible for these hemostatic disorders probably involve the urinary loss of anticoagulants, increased liver synthesis of procoagulants stimulated by hypoalbuminemia, or consumption of coagulation factors by intravascular thrombin formation.<sup>5</sup>

Free protein S, but not bound protein S, acts as a cofactor for activated protein C, a major inhibitor of blood coagulation.<sup>6</sup> Urinary loss of free protein S and increased synthesis of C4b binding protein, which shifts free protein S to bound form, contribute to low free protein S levels in patients with nephrotic syndrome.<sup>7</sup> Reduction of plasma volume and hemoconcentration due to nephrotic syndrome may also account for thrombosis. The risk of thrombosis is higher at the onset of the disease or during relapse.<sup>8</sup> Intensity of hypercoagulability is related to the degree of hypoalbuminemia, and these hemostatic abnormalities tend to revert toward normal on clinical remission of the nephrotic syndrome.<sup>4</sup>

In our first patient, illness began when she did not receive any treatment for nephrotic syndrome. In the other patient, the thrombotic events began during a period of poorly controlled nephrosis, as shown by marked proteinuria, low albumin concentration, and high cholesterol levels, despite taking corticosteroid. Both had some kind of clotting disorder. Reduced free protein S

or functional protein S activity was a consistent feature in both patients. The second patient showed additional deficiencies in antithrombin III and plasminogen.

In reviewing the English literature, six additional adult cases of CVT accompanying nephrotic syndrome were found (Table I).<sup>9-12</sup> The common clinical features included headache, seizure, diplopia, and disturbance of consciousness. Superior sagittal sinus was involved in most of them. Only five cases (including our two cases) had available data on protein S. Among them, three had deficiency of free protein S. Other common coagulation abnormalities are decreased antithrombin III and increased fibrinogen. The loss of free protein S may be an important factor in the pathogenesis of CVT in patients with nephrotic syndrome.

### Conclusion

Dural sinus thrombosis is a rare complication of nephrotic syndrome, often resulting in significant neurologic deficits and even death. In our series of 38 cases of CVT, 5.3% were due to nephrotic syndrome, and it seems that complications such as CVT may not be uncommon, but, being difficult to diagnose, may have simply gone unnoticed in the past. We suggest that any neurologic deficits, or even headache, in a nephrotic patient should prompt the clinician to search for possible CVT and to start treatment as soon as possible. Acquired protein S deficiency is a common finding in patients of nephrotic syndrome who develop CVT and may play an important role in the pathogenesis of CVT.

Ping-Keung Yip, MD  
Department of Neurology  
National Taiwan University Hospital  
7, Chung-Shan South Road  
Taipei, 100, Taiwan

### References

1. Cameron JS: The nephrotic syndrome and its complications. *Am J Kidney Dis* 10:151-171, 1987.
2. Llach F: Hypercoagulability, renal vein thrombosis, and other thrombotic complications of nephrotic syndrome. *Kidney Int* 28:429-439, 1985.
3. Andre E, Voisin Ph, Andre JL, et al: Hemorheological and hemostatic parameters in children with nephrotic syndrome undergoing steroid therapy. *Nephron* 68:184-191, 1994.
4. Alkjaersig N, Fletcher AP, Narayanan M, et al: Course and resolution of the coagulopathy in nephrotic children. *Kidney Int* 31:772-780, 1987.
5. Kanfer A: Coagulation factors in nephrotic syndrome. *Am J Nephrol* 10(suppl 1):63-68, 1990.
6. Kemkes-Matthes B: Acquired protein S deficiency. *Clin Invest* 70:529-534, 1992.
7. Vigano-D'Angelo S, D'Angelo A, Kaufman CE, et al: Protein S deficiency occurs in the nephrotic syndrome. *Ann Intern Med* 107:42-47, 1987.
8. Mattia DD, Penza R, Giordano P, et al: Thromboembolic risk in children with nephrotic syndrome. *Haemostasis* 21:300-304, 1991.
9. Levine SR, Kieran S, Puzio K, et al: Cerebral venous thrombosis with lupus anticoagulants. Report of two cases. *Stroke* 18:801-804, 1987.
10. Tovi F, Hirsch M, Gatot A: Superior vena cava syndrome: Presenting symptom of silent otitis media. *J Laryngol Otol* 102:623-625, 1988.
11. Burns A, Wilson E, Harber M, et al: Cerebral venous sinus thrombosis in minimal change nephrotic syndrome. *Nephrol Dial Transplant* 10:30-34, 1995.
12. Laversuch CJ, Brown MM, Clifton A, et al: Cerebral venous thrombosis and acquired protein S deficiency: An uncommon cause of headache in systemic lupus erythematosus. *Br J Rheumatol* 34:572-575, 1995.