



## Case report

## Neurogenic ST depression in stroke

Hoe Chin Chua <sup>a,\*</sup>, Souvik Sen <sup>a</sup>, Rosalie F. Cosgriff <sup>c</sup>, Gary Gerstenblith <sup>c</sup>,  
Norman J. Beauchamp Jr <sup>b</sup>, Stephen M. Oppenheimer <sup>a</sup>

<sup>a</sup> Department of Neurology, The Johns Hopkins University School of Medicine, Johns Hopkins Hospital, Meyer 5-185, 600 N Wolfe Street, Baltimore, MD 21287, USA

<sup>b</sup> Department of Neuroradiology, The Johns Hopkins University School of Medicine, Johns Hopkins Hospital, Meyer 5-185, 600 N Wolfe Street, Baltimore, MD 21287, USA

<sup>c</sup> Department of Medicine, The Johns Hopkins University School of Medicine, Johns Hopkins Hospital, Meyer 5-185, 600 N Wolfe Street, Baltimore, MD 21287, USA

Received 28 October 1998; received in revised form 23 December 1998; accepted 23 December 1998

**Abstract**

**Background:** Stroke is occasionally associated with ECG repolarization changes including ST depression. Recent evidence suggests a neurogenic contribution to these abnormalities in stroke patients. Animal studies implicate the insular cortex in cardiovascular control. We describe a patient with a left insular infarct and without cardiac or coronary artery disease, who developed ST depression indicating a neurogenic etiology. **Case description:** A 48 year-old female, with no risk factors for stroke, developed sudden expressive aphasia. MRI brain showed an infarct in the left insular cortex. Twenty-four hour Holter monitoring on the third day revealed transient ST depression more than 1.5 mm, which was not reproducible on subsequent monitoring. Transesophageal echo-cardiography (TEE) was normal. She had no cardiac symptoms and serial ECGs, cardiac enzymes (CKMB) and adenosine–thallium scan were normal. To-date, there had been no cardiac events like congestive heart failure or myocardial ischemia. **Conclusion:** These findings suggest neurogenic ST depression is related to the left insular infarct in view of the normal adenosine–thallium scan, non-reproducibility and evanescence of the ST segment changes and lack of associated cardiac symptoms. When neurogenic ST depression is combined with underlying coronary artery disease, it may adversely influence cardiac outcome after stroke. © 1999 Elsevier Science B.V. All rights reserved.

**Keywords:** Stroke; ST depression; Neurogenic; Insular cortex; Adenosine–thallium scan; Holter

**1. Introduction**

Electrocardiographic abnormalities have been reported after stroke [1]. Chiefly, these comprise repolarization changes including T wave inversion, QT prolongation and ST segment elevation or depression [1]. Whereas these changes are most commonly re-

ported after subarachnoid hemorrhage, their incidence after acute ischemic stroke is unclear but may be as high as 15–30% [2]. Similar repolarization abnormalities are commonly encountered in patients with coronary artery disease and can be associated with malignant ventricular arrhythmias. Therefore, when found in stroke patients, they may indicate an underlying ischemic heart condition contributing to the increased cardiac morbidity and mortality reported on the longer term follow-up of stroke patients [3–5]. However, it has been shown that repolarization abnormalities may be seen in stroke patients without demon-

\* Corresponding author. Present address: Department of Neurology, Tan Tock Seng Hospital, 2, Mandalay Road, Singapore 308206, Singapore. Tel.: + 65-359-5436; fax: + 65-359-5503.

E-mail address: hschua@singnet.com.sg (H. Chin Chua)

strable coronary artery disease or cardiomyopathy and may be due to neurogenic influences on the heart, for instance, ST segment elevation has been reported after subarachnoid hemorrhage in patients who have angiographically-confirmed normal coronary arteries [6]. In addition, we have produced a rat model in which ST segment depression is produced by insular stimulation and is associated with increased cardiac sympathetic nerve activity [7]. Recently, we showed that left insular lesions in humans shift cardiac autonomic tone towards increased cardiovascular sympathetic predominance, a condition known to be associated with the production of malignant ventricular arrhythmias [8]. We now report a patient, who suffered a left insular cortex infarct, who had normal coronary arteries and a normal baseline ECG and who developed a single episode of significant ST depression, identified only on Holter monitoring. The case underlies the importance of cardiac monitoring in stroke patients in whom such abnormalities may be undetected otherwise and the importance of the insular cortex in the generation of cardiovascular changes after stroke.

## 2. Methods

One hundred and twenty five patients with a first stroke or transient ischemic attack, received a comprehensive cardiac evaluation, including serial ECGs, chest X-rays, cardiac enzymes, multiplanar transesophageal echocardiography and Holter monitoring. An adenosine–thallium scan was performed on patients without any symptoms, history or ECG findings suggestive of coronary artery disease. The latter is a non-invasive test with high specificity and sensitivity for the presence of coronary artery stenosis [9–12]. ST depression was defined as deviation  $>1.0$  mm from the baseline, with horizontal or downward sloping ST segment 0.08 s after the J point, with at least 1 min duration [13]. A normal interval of at least 2 min was required after the resolution of each episode before another episode was counted.

## 3. Results

We identified one patient with a normal adenosine–thallium scan, who had transient asymptomatic ST depression.

## 4. Case report

The patient, a 48 year-old right-handed African–American female, was admitted for acute onset of an expressive aphasia with some comprehension deficits.

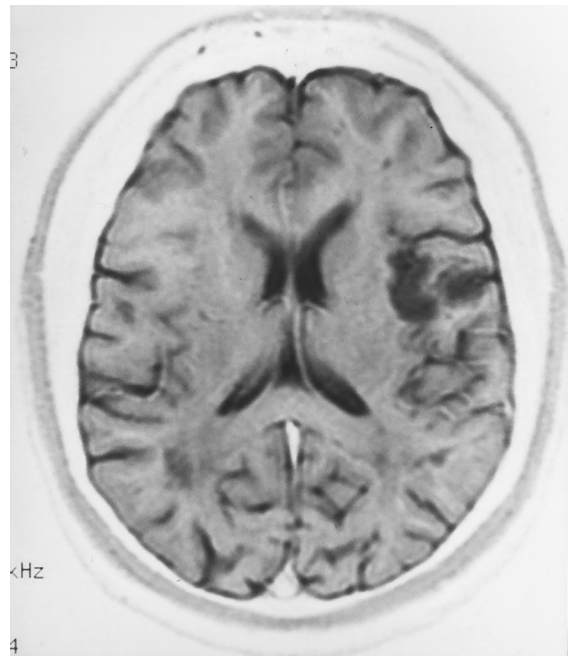


Fig. 1. T2 weighted MRI image showing infarction of the left superior insular cortex and surrounding parietal operculum.

There were no other neurological deficits. The patient had no history of hypertension, diabetes or cardiac disease and was a non-smoker without relevant family history. There was no history of drug abuse and tests for cocaine and other illicit drug metabolites were negative. MRI of the brain showed a small left insular infarct (Fig. 1). Transesophageal echo-cardiography (TEE) 5 days after stroke showed normal left ventricular function without left ventricular hypertrophy or regional wall motion abnormalities, indicating the absence of significant hypertension or cardiomyopathy (Table 1). Serial ECGs in the first week were within normal limits and 24-h Holter monitoring on the third post-stroke day revealed ST depression  $>1.0$  mm lasting 30 min (Fig. 2A). This was associated with an increase in heart rate from 70 beats per minute to a mean of 100 beats per minute (Fig. 2B). There were no

Table 1  
TEE results at baseline and 9 months post-stroke

Measurements (normal range)	TEE	
	Baseline	9 months
Left atrial diameter (15–40 mm)	40	38
Septal wall thickness (6–12 mm)	11	11
Posterior wall thickness (6–12 mm)	9	10
Left ventricle end-diastolic diameter (33–58 mm)	44	47
Left ventricle end-systolic diameter (10–35 mm)	20	29
Left ventricle hypertrophy	No	No

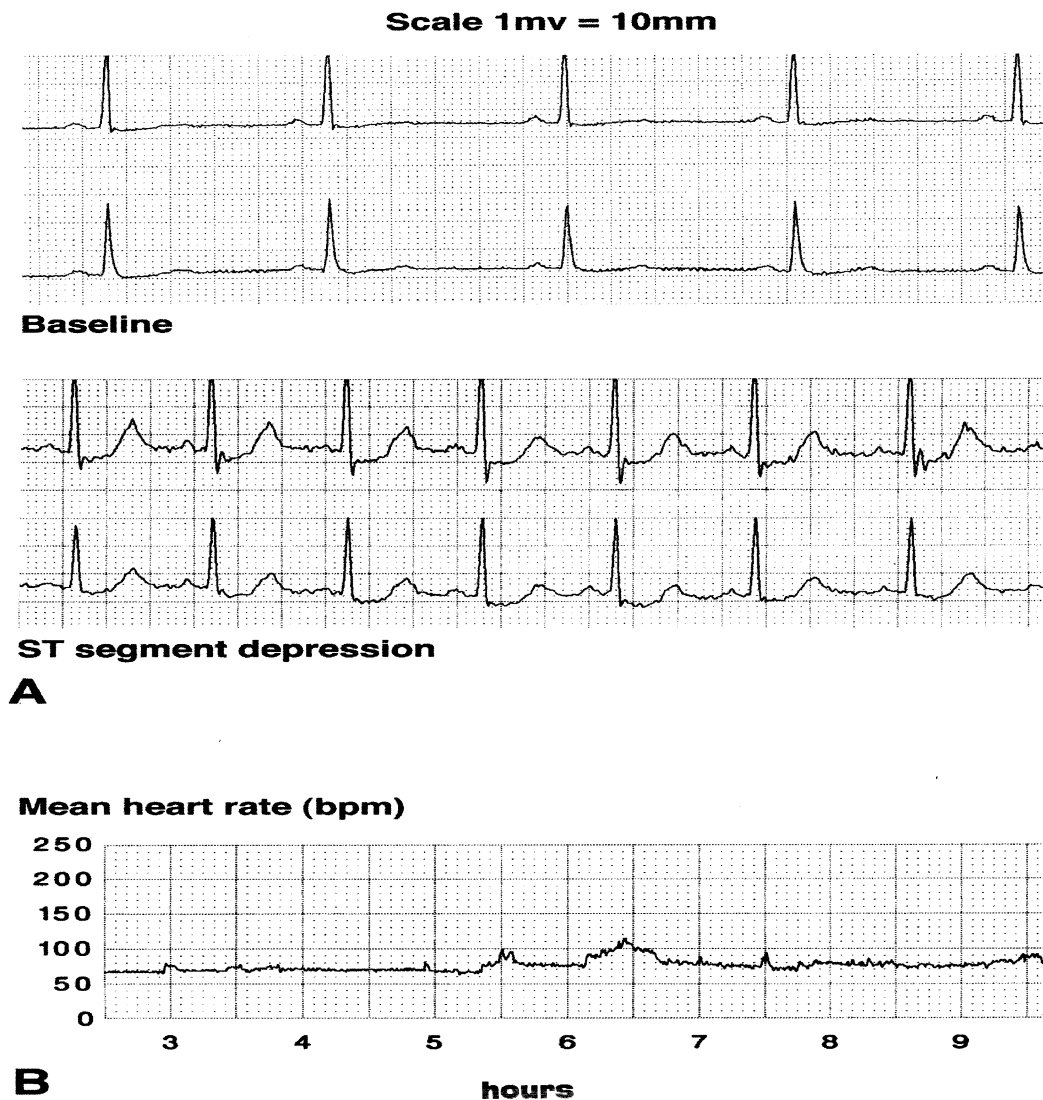


Fig. 2. (A) Holter recording on day three after stroke, showing baseline and a following episode of asymptomatic ST segment depression, with a cardiac rate of 90–100 beats per minute. (B) Graph of trends in heart rate with a mean cardiac rate of 100 beats per minute between 06:00 and 07:00 h, at the time of asymptomatic ST depression.

cardiac symptoms. Serum potassium, calcium and cardiac enzymes were normal. Subsequent Holter monitoring on day 7 and months 1, 3, 9 and 12 did not show any ST changes. Serial ECGs, chest X-rays and cardiac enzymes performed at the same time intervals were also normal. An adenosine–thallium scan performed 9 months after stroke onset did not show any evidence of coronary artery disease. A young stroke work-up was negative (lupus anticoagulant, anticardiolipin antibody, PT/PTT, antinuclear antibody, erythrocyte sedimentation rate, homocysteine, VDRL, TPHA, protein C, protein S, antithrombin III, fibrinogen and factor V Leiden) and serum lipids were within normal range. There have to date been no significant cardiac events, including congestive cardiac failure or myocardial ischemia.

## 5. Discussion

We identified one patient among 46 subjects with normal adenosine–thallium scans, who developed transient ST depression on Holter monitoring within 1 week of left insular infarction. We suggest, that the episode of ST segment depression was neurogenic in nature and resulted from increased sympathetic tone for the following reasons. (1) There is no evidence of coronary artery disease or cardiac pathology to account for these changes. Indeed, transient ST segment changes are reported in subarachnoid hemorrhage patients in whom coronary arteriography did not show underlying coronary atheroma [6]. (2) Similar repolarization changes can be induced by systemic catecholamine infusion [14]. (3) Human stimulation data indicates lateralization of

cardiovascular control. The left insula is concerned mainly with control of parasympathetic cardiac drive and the right, with control of cardiovascular sympathetic tone [15]. Damage to the left insular cortex by stroke may shift sympathovagal balance towards increased cardiac sympathetic tone. This was observed in a small group of stroke patients in a previous report [8]. Finally, similar changes have been produced in the rat on stimulation of the insula and are associated with increased plasma norepinephrine levels and increased cardiac sympathetic nerve activity [16]. In this patient, increased cardiac sympathetic drive during the ST depression episode was suggested by the elevated heart rate observed during the period of ST segment depression (Fig. 2B).

Asymptomatic ST segment depression has been reported in the adult population during 24 h Holter monitoring. The incidence varies between 2 and 30% [17–21]. It could, therefore, be argued that the patient demonstrated no more than the normal variation seen in patients without symptomatic coronary artery disease. Further inspection of these early reports reveals that, in all cases, inadequate attempts were made to investigate the presence of underlying coronary artery disease by either coronary arteriography or by adenosine–thallium scanning (which has a high sensitivity and specificity for the detection of cardiac ischemia [9–12]). In the majority of cases, the changes occurred during exercise and could be reproduced under conditions of physical exertion. In other cases, the changes were associated with posture. In yet others, the criteria for ST depression included J point depression and an immediate upward slope of the ST segment, which is considered to be a non-significant finding. In the majority of cases, ST depression was recorded during episodes of significant tachycardia (> 120 beats per minute) not seen in our patient. We argue that these same objections do not apply to our patient: (a) coronary artery disease was ruled out by a highly specific and sensitive test; (b) the recordings were made at rest taking care that the patient was not stressed or active; and (c) the episode was limited to the acute stroke period and was not reproducible under similar conditions during 1 year of follow-up. This accumulated evidence suggests that the changes observed are due to a neurogenic cause and likely reflect oscillations in cardiac sympathetic tone following left insular infarction. We did not perform an exercise stress test during follow-up as adenosine–thallium scan has high sensitivity and specificity in detecting coronary artery disease. Amanullah et al. found a sensitivity, specificity and predictive accuracy of 93, 78 and 88%, respectively, for detecting coronary artery disease ( $\geq 50\%$  diameter stenosis) [9]. Miyagawa et al. found that the sensitivity and specificity for detecting coronary artery disease was 88 and 80%, respectively, by visual analysis and 91 and

86% by computer quantification [10]. In contrast, the mean sensitivity and specificity of exercise stress test for detecting coronary artery disease is 68 and 77%, respectively [22]. In patients with multivessel coronary disease, the mean sensitivity and specificity is increased to 81 and 66%, respectively [23].

The significance of these asymptomatic episodes of ST depression is unclear. Lavy et al. reported a significantly increased mortality in acute stroke patients whose admission ECG showed new onset ST changes [24]. While the subject of this case report did not experience an adverse cardiac outcome during 1 year of follow-up, the significance of these changes must be determined in a larger group of patients. We suggest that, when combined with underlying coronary artery disease, left insular infarction may adversely influence cardiac outcome after stroke. Neurogenic changes may underlie the mechanism.

### Acknowledgements

This work was supported by grants from the National Institute of Health (PHS Grants NS 3370-03 and RR-00052).

### References

- [1] Oppenheimer SM, Hachinski VC. The cardiac consequences of stroke. *Neurol Clin North Am* 1992;10:167–76.
- [2] Oppenheimer SM. Neurogenic cardiac effects of cerebrovascular disease. *Curr Opin Neurol* 1994;7:20–4.
- [3] Nascet. Beneficial effect of carotid endarterectomy in symptomatic patients with high grade stenosis. *New Engl J Med* 1991;325:445–53.
- [4] Hass WK, Easton JD, Adams HP, Pryse-Phillips W, Molony BA, Anderson S, et al. A randomized trial comparing ticlopidine hydrochloride with aspirin for the prevention of stroke in high risk patients. *New Engl J Med* 1989;321:501–7.
- [5] Schmidt EV, Smirnov VE, Ryabova VS. Results of the seven-year prospective study of stroke patients. *Stroke* 1988;19:942–9.
- [6] Kono T, Morita H, Kuroiwa T, Onaka H, Takatsuka H, Fujiwara A. Left ventricular wall motion abnormalities in patients with subarachnoid hemorrhage: neurogenic stunned myocardium. *J Am Coll Cardiol* 1994;24:636–40.
- [7] Oppenheimer SM, Wilson JX, Guiraudon C, Cechetto DF. Insular cortex stimulation produces lethal cardiac arrhythmias: a mechanism of sudden death? *Brain Res* 1991;550:115–21.
- [8] Oppenheimer SM, Martin WM, Kedem G. Left insular cortex lesions perturb cardiac autonomic tone. *Clin Auton Res* 1996;6:131–40.
- [9] Amanullah AM, Kiat H, Friedman JD, Berman DS. Adenosine technetium-99m sestamibi myocardial perfusion SPECT in women: diagnostic efficacy in detection of coronary artery disease. *J Am Coll Cardiol* 1996;27:803–9.
- [10] Miyagawa M, Kumano S, Sekiya M, Watanabe K, Akutzu H, Imachi T, et al. Thallium-201 myocardial tomography with intravenous infusion of adenosine triphosphate in diagnosis of coronary artery disease. *J Am Coll Cardiol* 1995;26:1196–201.
- [11] Wackers FJ. Adenosine thallium imaging: faster and better. *J Am Coll Cardiol* 1990;16:1384–6.

- [12] Verani MS. Adenosine thallium 201 myocardial perfusion scintigraphy. *Am Heart J* 1991;122:269–78.
- [13] Gottlieb SO, Weisfeldt ML, Ouyang P, Mellits ED, Gerstenblith G. Silent ischemia as a marker for unfavorable outcomes in patients with unstable angina. *New Engl J Med* 1986;314:1214–9.
- [14] Lepeschkin E, Marchet H, Schroeder G, Wagner R, de Paula P, Silva E, Raab W. Effect of epinephrine and norepinephrine on the electrocardiogram of 100 normal subjects. *Am J Cardiol* 1960;5:594–603.
- [15] Oppenheimer SM. Cardiovascular effects of human insular cortex stimulation. *Neurology* 1992;42:1727–32.
- [16] Oppenheimer SM, Saleh TM, Wilson JX, Cechetto DF. Plasma and organ catecholamine levels following stimulation of the rat insular cortex. *Brain Res* 1992;569:221–8.
- [17] Quyyumi AA, Wright C, Fox K. Ambulatory electrocardiographic ST segment changes in healthy volunteers. *Br Heart J* 1983;50:460–4.
- [18] Armstrong WF, Jordan JW, Morris SN, McHenry PL. Prevalence and magnitude of ST segment and T wave abnormalities in normal men during ambulatory continuous electrocardiography. *Am J Cardiol* 1982;49:1638–42.
- [19] Deanfield JE, Ribiero P, Oakley K, Krikler S, Selwyn AP. Analysis of ST segment changes in normal subjects: implications for ambulatory monitoring in angina pectoris. *Am J Cardiol* 1984;54:1321–5.
- [20] Kohli RS, Cashman PMM, Lahiri A, Raftery EB. The ST segment of the ambulatory electrocardiogram in a normal population. *Br Heart J* 1988;60:4–16.
- [21] Stern S, Tzivoni D. Dynamic changes in the ST-T segment during sleep in ischemic heart disease. *Am J Cardiol* 1973;32:17–20.
- [22] Gianrossi R, Detrano R, Mulvihill D, Lehmann K, Dubach P, Colombo A, et al. Exercise-induced ST depression in diagnosis of coronary artery disease. A meta-analysis. *Circulation* 1989;80:87–98.
- [23] Detrano R, Gianrossi R, Mulvihill D, Lehmann K, Dubach P, Colombo A, et al. Exercise-induced ST depression in diagnosis of multi-vessel coronary disease. A meta-analysis. *J Am Coll Cardiol* 1989;14:1501–8.
- [24] Lavy S, Yaar I, Melamed E, Stern S. The effect of acute stroke on cardiac function as observed in an intensive stroke care unit. *Stroke* 1974;5:775–80.