



Case report

Prothrombin gene variant (G20210A) in a patient with cerebral venous sinus thrombosis

J. van Krimpen^a, F.W.G. Leebeek^b, D.W.J. Dippel^{a,*}, E. Gomez Garcia^b^a Department of Neurology, University Hospital Rotterdam, 3000 CA Rotterdam, The Netherlands^b Department of Haematology, University Hospital Rotterdam, 3000 CA Rotterdam, The Netherlands

Received 18 November 1998; received in revised form 28 December 1998; accepted 28 December 1998

Abstract

We describe a 33-year-old woman, who presented with lowered consciousness level and seizures, due to cerebral venous sinus thrombosis with venous haemorrhagic infarcts. The patient, who was taking oral contraceptives, appeared to be heterozygous for a prothrombin gene variant, which is due to a G→A transition at position 20210. This 20210A prothrombin has recently been established as an important risk factor for cerebral venous sinus thrombosis, which interacts with oral contraceptive use. © 1999 Elsevier Science B.V. All rights reserved.

Keywords: Prothrombin; Sinus thrombosis

1. Introduction

We describe a patient with cerebral venous sinus thrombosis, who appeared to be heterozygous for a recently discovered prothrombin gene variant, which is due to a G→A transition at position 20210 of the prothrombin gene. This transition results in an elevated prothrombin activity and is associated with a moderate increased risk of venous thrombosis [1].

2. Case report

A 33-year-old woman was admitted to our hospital in October 1997. She had developed a severe headache with nausea and vomiting, 6 days earlier. Just prior to admittance she had suddenly lost consciousness, with clonic shaking of the legs and incontinence. The patient

had been taking oral contraceptives, she did not smoke and there was neither a personal history of venous thrombosis nor a familial predisposition.

Upon admittance, the patient was unconscious. The body temperature was 38.1°C, blood pressure was 120/80 mm Hg. Further examination of lungs, heart and abdomen was unremarkable. She responded symmetrically to pain stimuli by flexion of the arms and there was spontaneous extension of the legs. The tendon reflexes were brisk and the plantar responses were both extensor. Computed tomography of the brain showed multiple haemorrhagic infarctions of both hemispheres and of the cerebellum (Fig. 1A). The basal cisterns were partially obliterated. Subsequent magnetic resonance imaging visualised the haemorrhagic infarcts and showed a hyperintense lesion in the superior sagittal sinus and in the transverse sinus (Fig. 1B). A diagnosis of cerebral venous sinus thrombosis was made. The patient was deteriorating rapidly and in a desperate attempt to lower intracranial pressure, a lumbar puncture and subsequent cerebrospinal fluid (CSF) drainage

* Corresponding author. Tel.: +31-10-4639222; fax: +31-10-4367293.

E-mail address: dippel@neuro.fgg.eur.nl (D.W.J. Dippel)

was carried out. Lumbar puncture revealed haemorrhagic cerebrospinal fluid, with an opening pressure of 50 cm H₂O. After 12 h, the patient was treated with intravenous heparin, but nevertheless deteriorated and died 2 days later.

Coagulation studies, including lupus anticoagulant, anticardiolipin antibodies, protein C and antithrombin were normal. Protein S activity was decreased (0.28 U/ml; normal range 0.70–1.40), but protein S antigen was in the normal range (0.81 U/ml; normal range 0.70–1.40). Factor V Leiden mutation was excluded by showing a normal activated protein C resistance ratio, which was confirmed by DNA analysis using PCR [2]. PCR analysis of the prothrombin gene revealed that the patient was heterozygous for the GA transition at position 20210 [2]. The prothrombin level in plasma was elevated (1.94 U/ml; normal range 0.86–1.22 U/ml).

3. Discussion

Several studies have identified hereditary coagulation disorders as predisposing risk factor for venous sinus thrombosis. Antithrombin, protein C and protein S deficiency, have all been described in association with cerebral venous thrombosis [3,4]. In a more recent study, factor V Leiden mutation was also found to be a risk factor for cerebral venous sinus thrombosis [5]. The prothrombin gene variant that was present in our patient has recently been identified. It is characterised by a G→A transition at position 20210 in the 3'-untranslated region of the prothrombin gene and it is associ-

ated with increased prothrombin levels in plasma [1]. Prothrombin is a plasma glycoprotein that, after its conversion to thrombin, promotes polymerisation of fibrinogen molecules into fibrin threads. The prothrombin gene variant acts as a moderate risk factor for venous thrombosis, as it is associated with a 3-fold increased risk of developing venous thrombosis in case control studies. In unselected patients with a first period of deep vein thrombosis, the frequency of the mutation was 6.3%, whereas it was 2.3% in the general Dutch population [1].

In our patient, the protein S activity levels were reduced, which may have contributed to the prothrombotic state. This may have been due to the use of oral contraceptives or to the ongoing thrombotic event at the time of blood sampling, both known to be associated with low protein S activity. An alternative explanation may be the existence of a heterozygous type II protein S deficiency, although the occurrence of protein S deficiency in association with the prothrombin gene variant is very rare [6].

The first patient with cerebral venous thrombosis and prothrombin gene G20210A variant was described by Bloem et al. [7]. This patient and ours were both young women using oral contraceptives. Two case control studies have now shown that the prothrombin gene variant is a risk factor for the development of cerebral venous sinus thrombosis [8,9]. Both studies confirmed that the prothrombin gene variant and oral contraceptives act in a multiplicative way on the risk of developing cerebral venous thrombosis. A similar effect has been demonstrated by De Bruijn in patients with protein S or protein C deficiency [10]. Clearly, the

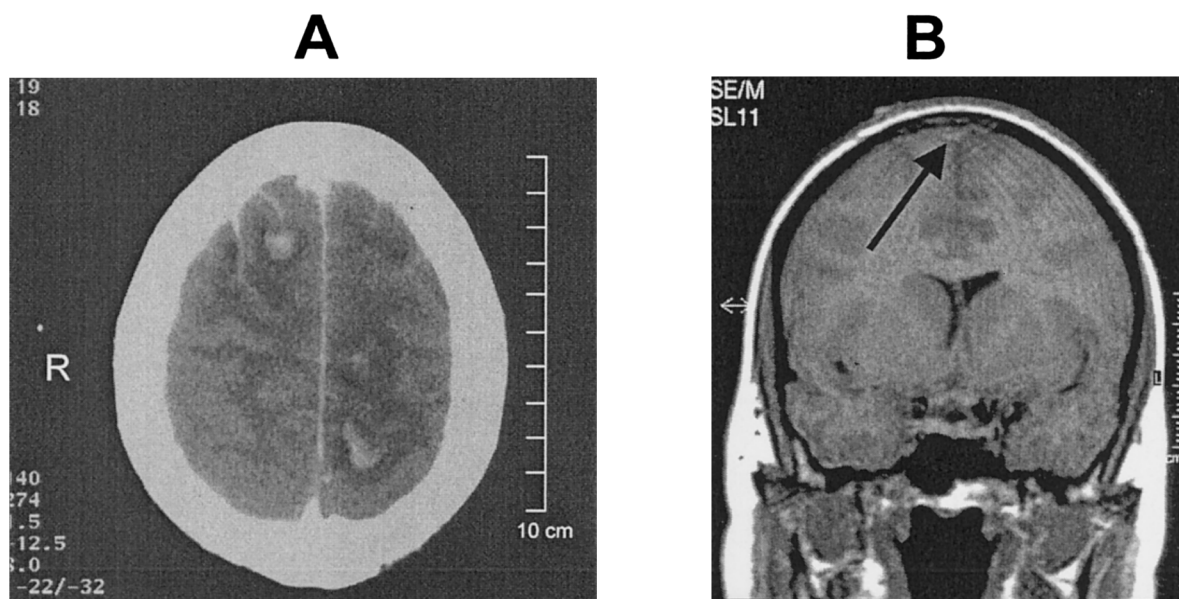


Fig. 1. (A) CT scan of the brain with multiple haemorrhagic infarcts. (B) T1 weighted coronal section of a MRI scan of the head with a hyperintense lesion in the superior sagittal sinus (arrow).

prothrombin gene variant plays a role, alone or in combination with oral contraceptives, in the development of cerebral venous sinus thrombosis. Whether hormonal therapy further increases the prothrombin levels, or acts through an independent mechanism has not been investigated.

We have presented a patient with a fatal central venous sinus thrombosis, who used oral contraceptives and carried the recently discovered prothrombin variant allele. The prothrombin G20210A variant can be rapidly determined. This is a useful diagnostic procedure in the context of cerebral venous sinus thrombosis, because of the strong interaction between this condition and the use of oral contraceptives, a modifiable risk factor for cerebral venous sinus thrombosis.

Acknowledgements

We thank Dr H.H.D.M. van Vliet for the determination of the protein assays and S. van der Poel for the genotypic analysis.

References

- [1] Poort SR, Rosendaal FR, Reitsma PR, Bertina RM. A common genetic variant in the 3'-untranslated region of the prothrombin gene is associated with elevated plasma prothrombin levels and an increase in venous thrombosis. *Blood* 1996;88:3698–703.
- [2] Gomez E, van der Poel SCPAM, Jansen JH, van der Reijden BA, Lowenberg B. Rapid simultaneous screening of factor V Leiden and G20210A prothrombin variant by multiplex polymerase chain reaction on whole blood. *Blood* 1998;91:2208–9.
- [3] Deschiens MA, Conard J, Horellou MH, Ameri A, Preter M, Chedru F, Samama MM, Bousser MG. Coagulation studies, factor V Leiden and anticardiolipin antibodies in 40 cases of cerebral venous thrombosis. *Stroke* 1996;27:1724–30.
- [4] Heisteringer M, Rimpl E, Illiasch H, Turck H, Kyrle PA, Lechner K, Pabinger I. Cerebral sinus thrombosis in a patient with hereditary protein S deficiency: case report and review of the literature. *Ann Hematol* 1992;64:105–9.
- [5] Martinelli I, Landi G, Merati G, Cella R, Tostetto A, Mannucci PM. Factor V gene mutation is a risk factor for cerebral venous thrombosis. *Thromb Haemost* 1996;75:393–4.
- [6] Zoller B, Svensson PJ, Dahlback B, Hillarp A. The A20210 allele of the prothrombin gene is frequently associated with factor V Arg 506 to Gln mutation but not with protein S deficiency in thrombophilic families. *Blood* 1998;91:2210–1.
- [7] Bloem BR, Van Putten MJAM, Van der Meer FJM, Van Hilten JJ, Bertina RM. Superior sagittal sinus thrombosis in a patient heterozygous for the novel 20210 A allele of the prothrombin gene. *Thromb Haemost* 1998;79:235–5.
- [8] Martinelli I, Sacchi E, Landi G, Taioli E, Duca F, Mannucci PM. High risk of cerebral-vein thrombosis in carriers of a prothrombin-gene mutation and in users of oral contraceptives. *New Engl J Med* 1998;338:1793–7.
- [9] Reuner KH, Ruf A, Grau A, Rickmann H, Stolz E, Jüttler E, Druschky K-F, Patscheke H. Prothrombin gene G20210A transition is a risk factor for cerebral venous thrombosis. *Stroke* 1998;29:1765–9.
- [10] De Bruijn SF, Stam J, Koopman MM, Vandenbroucke JP. Case-control study of risk of cerebral sinus thrombosis in oral contraceptive users who are carriers of hereditary prothrombotic conditions. The Cerebral Venous Sinus Thrombosis Study Group. *Br Med J* 1998;316:589–92.