



Case report

Vertebrobasilar artery territory infarction as an initial manifestation of systemic lupus erythematosus

Sun Uck Kwon, Jae Young Koh, Jong Sung Kim *

Department of Neurology, University of Ulsan, Asan Medical Center, Song-pa, P.O. Box 145, Seoul 138-600, South Korea

Received 28 October 1998; received in revised form 11 January 1999; accepted 11 January 1999

Abstract

Cerebral infarction is a well-documented complication of systemic lupus erythematosus (SLE), that usually occurs several years after the diagnosis of SLE. To our knowledge, however, strokes associated with vertebrobasilar artery involvement were not reported to present as an initial manifestation of SLE. We report two patients, who presented with vertebrobasilar territory infarction as an initial manifestation of SLE. Patient 1 was a 16-year-old girl, who developed dysarthria and ataxia. MRI showed multiple infarcts in the pons, cerebellum and thalamus. Four-vessel cerebral angiography showed multifocal stenoses in the vertebral and basilar arteries with beaded appearance. Patient 2 was a 26-year-old woman, who developed headache associated with dysarthria, dizziness and ataxia. MRI showed multiple infarcts in the cerebellum, medulla, pons, midbrain and thalamus. Cerebral angiography revealed occlusion of both vertebral arteries at the first cervical vertebral level with non-visualization of the basilar artery. Both patients were diagnosed as having SLE supported by laboratory results. Although rare, posterior circulation stroke can present as an initial manifestation of SLE, which may be attributed to vasculitis or dissection in the vertebral/basilar artery. © 1999 Elsevier Science B.V. All rights reserved.

Keywords: Systemic lupus erythematosus; Cerebrovascular disease; Vertebral artery; Basilar artery; Vasculitis; Dissection

1. Introduction

Stroke is a well known complication of systemic lupus erythematosus (SLE) occurring in 3–20% of the patients, usually several years after the initial diagnosis of SLE [1–6]. It most often develops secondary to cardiogenic embolism or antibody-associated hypercoagulable state [1]. Large cerebral vessel disease is uncommon in SLE and rarely presents as an initial manifestation [7]. To the best of our knowledge, vertebrobasilar artery stenosis/occlusion has not been reported to present as an initial manifestation of SLE, which prompted us to report the following two patients.

2. Case reports**2.1. Patient 1**

A 16-year-old previously healthy girl, experienced several episodes of dizziness and dull headache. Three months later, she suddenly developed dysarthria and ataxia and became drowsy in a few days. She was a high-school student and had no history of alcohol or tobacco use. Recent history of immunization, infection and exposure to toxins, heavy metals, illicit drugs or oral contraceptives was denied. Family history of stroke, thrombosis and miscarriages was also denied. She had not experienced arthralgia, but her family stated that the patient's skin often turned reddish after sunlight exposure during the past several years.

* Corresponding author. Tel.: +82-2-224-3442; fax: +82-2-474-4691.

On admission, her temperature was 36.5°C, pulse 100, rate of respiration 20 and blood pressure was 170/110 mmHg. An examination, the heart, lungs, abdomen and the extremities were normal, but malar rashes were noted on both cheeks. On neurological examination, the patient was drowsy and severely dysarthric. On forward gaze, horizontal right-beating nystagmus was observed. She exhibited severe truncal ataxia and action tremor in both arms with ataxia.

Laboratory tests showed leukocytosis (WBC, 11 300/mm³), but the hemoglobin and platelet count were within normal limits. Serum protein, albumin, crea-

tinine, glucose, cholesterol and triglyceride levels were within normal limits. Total amount of protein in 24-h urine was 0.56 g. Fluorescent antinuclear antibody (FANA) test was positive at 1:40 dilution with homogeneous pattern. Anti-ds-DNA antibody was 21.7 Iu/ml (normal range: <7.0 Iu/ml) and direct Coombs' test was positive. Lupus anticoagulant was also positive. The cerebrospinal fluid examination showed normal findings. Chest X-ray, EKG and echocardiography revealed no abnormalities. Brain MRI showed multiple small high signal lesions in the left lateral pons, bilateral superior cerebellar peduncles, cerebellar hemi-

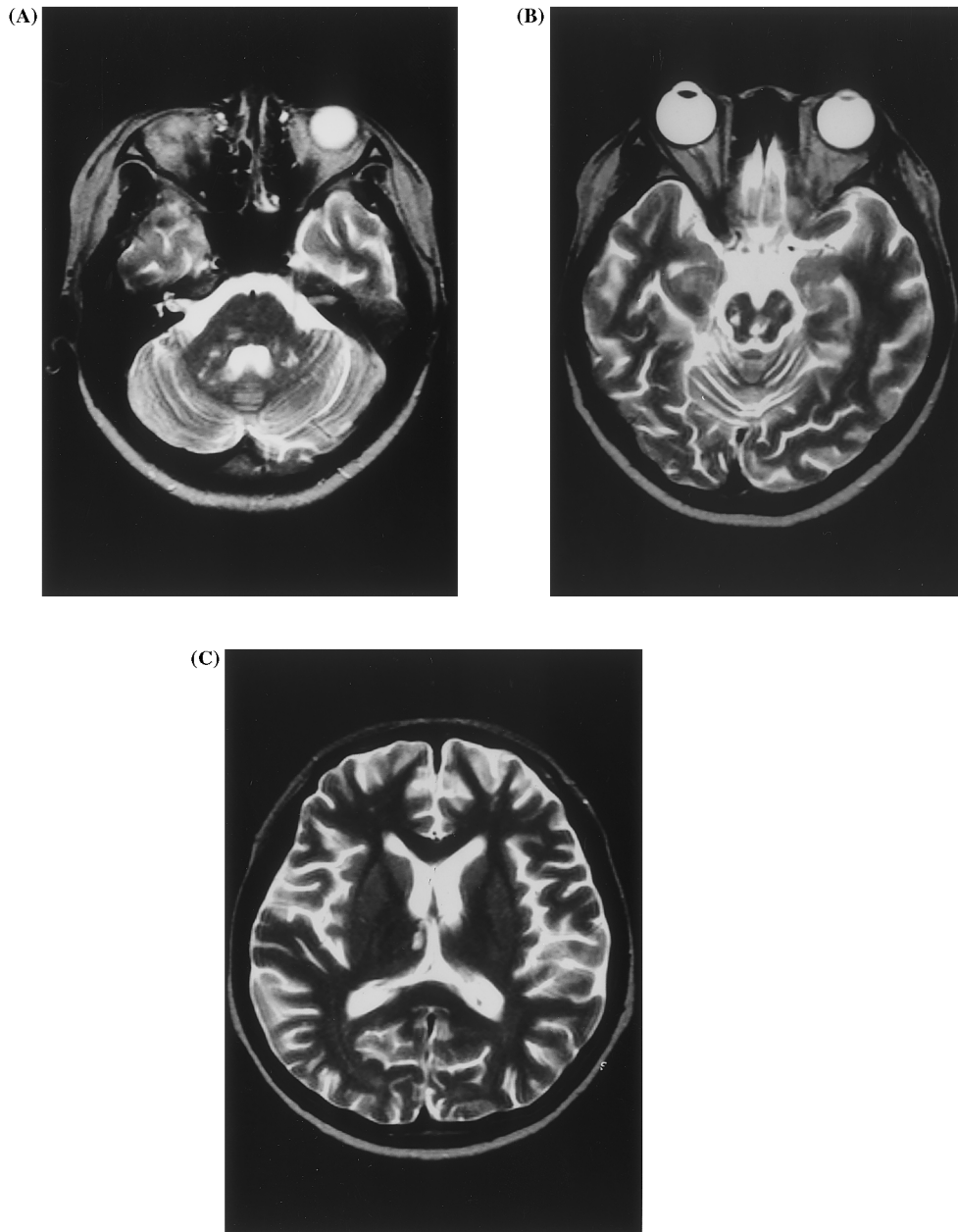


Fig. 1. Brain MRI of patient 1. There are multiple small high-signal intensity lesions in the pons, bilateral cerebellar peduncles, cerebellar hemisphere (A), midbrain (B) and right medial thalamus (C) on T2-weighted image.

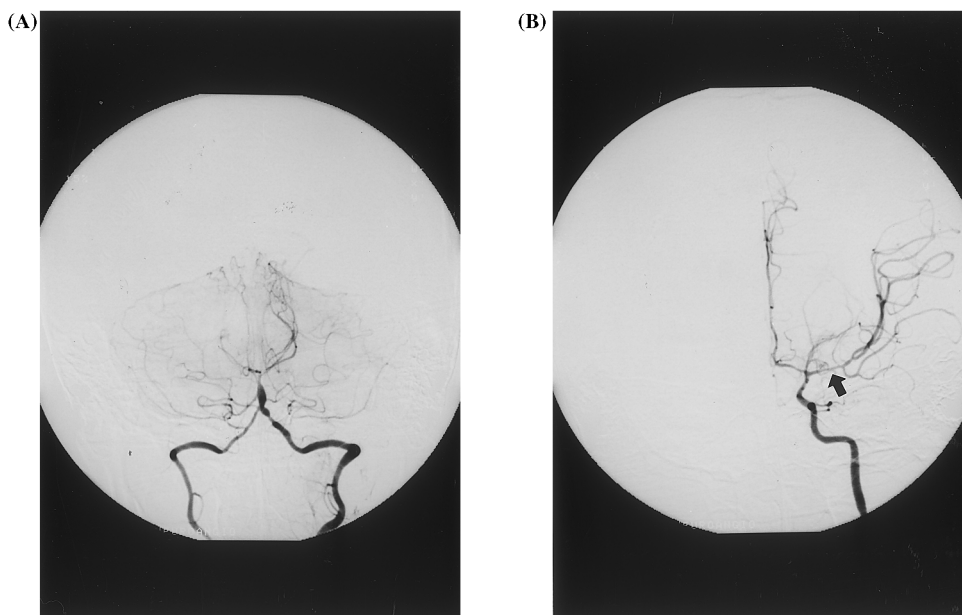


Fig. 2. Cerebral angiogram of patient 1. There was alternating segments of narrowing and ectasia involving the left vertebral, basilar artery and right posterior cerebral artery (A). In addition, the left ICA angiogram shows diffuse narrowing of M1 segment of middle cerebral artery (B, arrow).

sphere, midbrain and the right paramedian thalamus on T2-weighted image (Fig. 1). Four-vessel cerebral angiography showed diffuse narrowing of the proximal portion of the left middle cerebral artery (Fig. 2A) and multifocal, irregular stenoses/narrowings of the left distal vertebral, basilar and the proximal portion of the right posterior cerebral artery with occasional beaded appearance (Fig. 2B).

The patient's blood pressure was normalized without any treatment. Oral anticoagulation and monthly administration of intravenous cyclophosphamide were tried and she gradually improved. Six months later she was able to walk by herself, although she remained ataxic and dysarthric. She did not experience a recurrent stroke until 3 years later when a follow-up brain MRI was taken that revealed no additional lesions.

2.2. Patient 2

A 26-year-old previously healthy woman suddenly developed occipital headache followed by dizziness and slurred speech. The symptoms had progressed until several days later, when she was admitted to our hospital. She was married and had one child. She had not experienced arthralgia, skin lesion, or spontaneous abortion, previously. She was not a cigarette smoker and rarely drank alcohol. There was no history of illicit drug use, oral pill ingestion, head trauma or recent immunization. Family history of stroke, thrombosis and miscarriage was denied.

On admission, her temperature was 36.8°C, pulse 104, rate of respiration 18 and blood pressure was

200/120 mmHg. Physical examination of the heart, lungs, abdomen and the extremities was normal. There was no skin rash or lymphadenopathy. On neurological examination, she was drowsy, dysarthric and dysphagic. There was a horizontal, right beating nystagmus, mild left facial weakness and left hemiparesis (IV/V). The sensation was preserved in all limbs. The deep tendon reflexes were normal, but Babinski sign was present on both sides.

Laboratory tests revealed anemia (hemoglobin, 7.8 g/dl) and mild leukocytosis (9000/mm³). The platelet count was 322 000/mm³ and the ESR was 80 mm/h. Serum creatinine, glucose, cholesterol and triglyceride levels were within normal limits. Total amount of protein in 24-h urine was 0.94 g. Anti-ds DNA antibody was 7.6 Iu/ml (normal range: < 7.0 Iu/ml). Fluorescent antinuclear antibody (FANA) test was positive at 1:640 dilution with homogenous pattern and direct Coombs' test was also positive. Lupus anticoagulant, anticardiolipin antibodies and serum protein C and S levels were all within normal limits. Cerebrospinal fluid examination was normal. Chest X-ray, EKG and echocardiography revealed no abnormalities. Brain MRI showed multiple high signal lesions in the left lateral medulla, bilateral cerebellum, pons, midbrain and the right thalamus on T2 weighted image (Fig. 3). Four-vessel cerebral angiography revealed occlusion of both vertebral arteries at the first cervical vertebral level with nonvisualization of the basilar artery (Fig. 4). The remaining extra- and intracranial vessels were normal. She gradually improved on treatment with antihypertensives, warfarin and prednisolone. At 9 months of

follow-up, she was able to stand and walk with assistance.

3. Discussion

Our two patients initially presented with acute infarction in the cerebellum and the brain stem due to vertebral/basilar artery disease. The possible causes of arterial steno-occlusion in young adults include embolism, dissection, premature atherosclerosis, coagulopathy and other angiopathies. We think the possibility of atherosclerosis and cardiogenic embolism was rea-

sonably excluded in our cases by the patients' age and echocardiographic findings. The angiographic findings were not compatible with moya-moya disease, Takayasu's arteritis, fibromuscular dysplasia, mitochondrial diseases and strokes associated with hypercoagulable state. Sneddon syndrome and isolated angiitis of the central nervous system (CNS) were excluded, respectively, by the absence of livedo reticulitis and the following pieces of evidence supporting the diagnosis of SLE: malar rash, photosensitivity, proteinuria and positive results for anti-ds-DNA antibody and lupus anticoagulant in patient 1 and the presence of anemia with positive direct Coomb's test, proteinuria, positive anti-

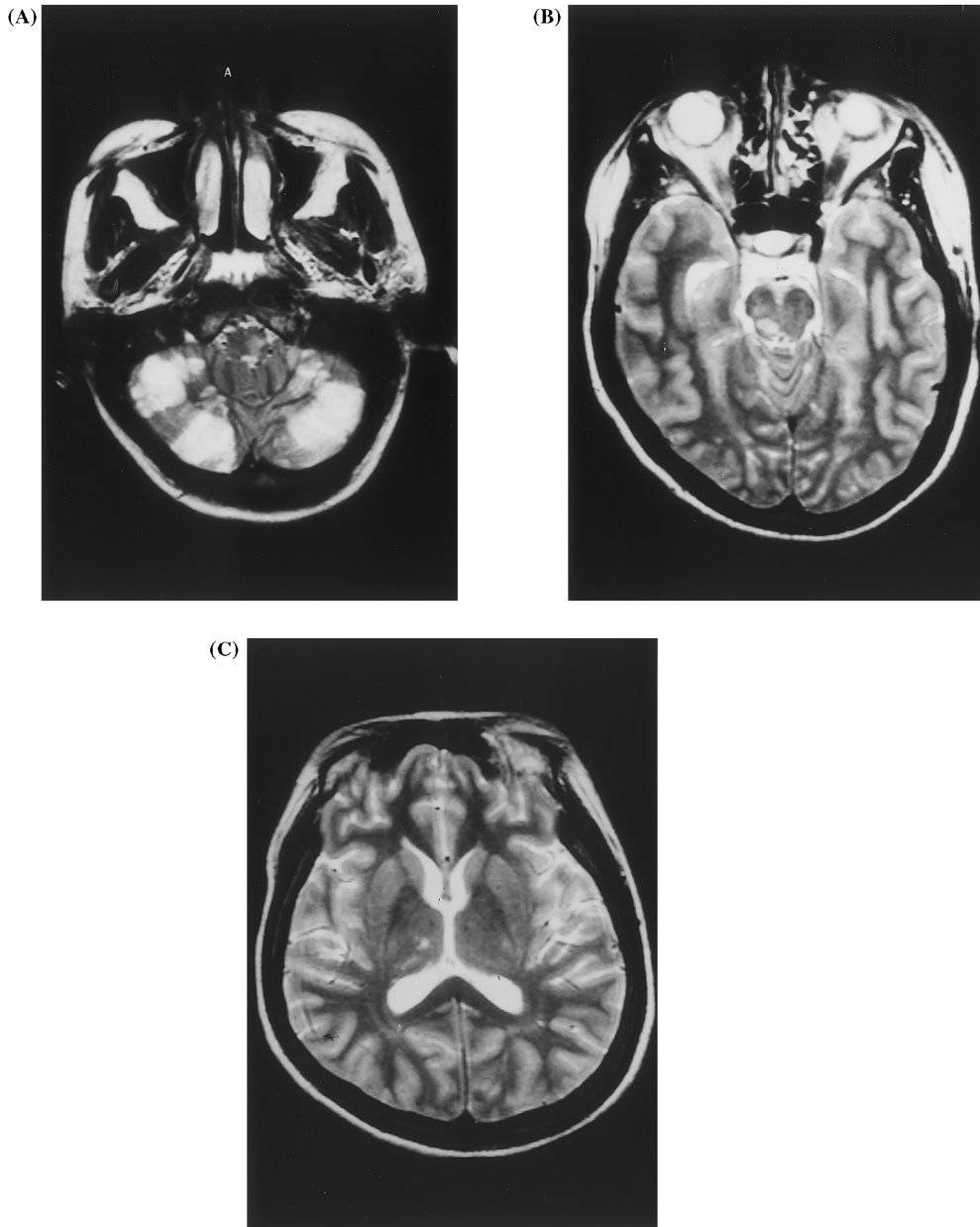


Fig. 3. Brain MRI of patient 2. There are multiple high-signal intensity lesions in the left medulla, bilateral cerebellar hemisphere (A), right midbrain (B) and right thalamus (C) on T2-weighted image.

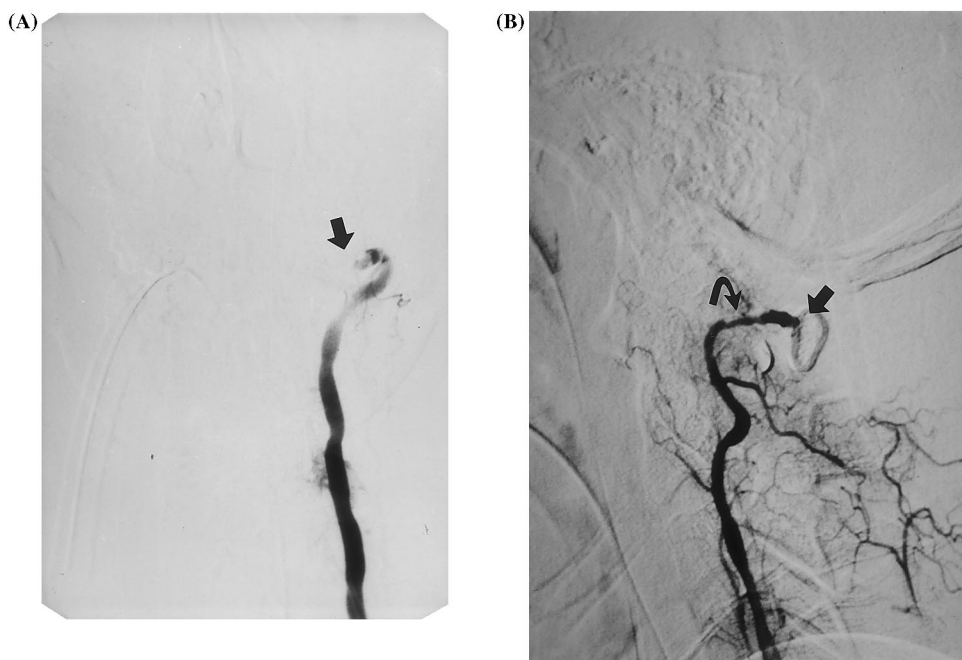


Fig. 4. Cerebral angiogram of patient 2. The left (A) and right (B) vertebral arteries were occluded (arrow) at the first cervical vertebra level. There was luminal irregularity (curved arrow) just proximal to the occluded right vertebral artery (B).

ds-DNA antibody and FANA in patient 2. Thus, both our patients satisfied the criteria for SLE by Tan et al. [8] and developed stroke in the active state of SLE. Although cerebral infarction often complicates SLE, posterior circulation stroke associated with vertebral/basilar artery stenosis/occlusion has not been described as an initial manifestation of SLE.

Large cerebral vessel disease is an uncommon manifestation of SLE. Mitsias and Levine [7] previously reviewed 30 patients (including 24 cases from literature) with SLE associated with symptomatic large cerebral arterial occlusive disease and stated that the pathogenic mechanisms may include coagulopathy, cardiogenic embolism, large cerebral vessel vasculitis/occlusive vasculopathy, cervical arterial dissection and premature atherosclerosis. In our patients, histopathological information was not available and actual vascular pathology remains unknown. However, the angiographic findings of patient 1—multifocal stenoses with beaded appearance—were most consistent with vasculitis. In spite of a few reports about vasculitis of large cerebral artery in SLE [9–11], vasculitis in a strict sense was considered a rare cause of stroke [1,2]. This rarity may be explained by the fact that inflammatory vasculopathy in this condition predominantly affects the small vessels of the kidney, skin, heart, lungs, gastrointestinal tract and the central nervous system [12].

In patient 2, there was an occlusion of both vertebral arteries. There was no atherosclerotic changes or

evidence of vasculitis in other vessels. Bilateral occlusion of the vertebral arteries could be caused by simultaneous embolic migration from unknown source. However, the luminal irregularity and stenosis just proximal to the occluded right vertebral artery appear to be more consistent with arterial dissection than embolic occlusion. Furthermore, the initial clinical presentation of this patient was a progressive one—an unlikely feature for the embolic events. These features, along with the presence of preceding occipital headache, suggest that arterial dissection may have produced the vertebral artery occlusion in this patient. Unfortunately, we failed to find features suggestive of dissection on axial MRI images. Vertebral arterial dissection in patients with SLE have been reported [7,13], but the mechanism for the dissection remains unclear. Considering the pathological findings of the previously reported dissecting aortic aneurysm in SLE patients—active arteritis or obliterative endarteritis of vasa vasorum resulting in multiple infarcts and disruption of the vessel wall [14,15]—an underlying arteritis or arteriopathy may predispose the vessels to be easily dissected.

In summary, our patients demonstrated that posterior circulation stroke can occur as an initial manifestation of SLE, which may be attributed to vasculitis or dissection of the vertebral artery and/or basilar artery. The possibility of SLE should therefore be raised and appropriate laboratory tests be performed when young women presenting with posterior circulation stroke are encountered.

References

- [1] Futrell N, Millikan C. Frequency, etiology and prevention of stroke in patients with systemic lupus erythematosus. *Stroke* 1989;20:583–91.
- [2] Devinsky O, Petito CK, Alonso DR. Clinical and neuropathological findings in systemic lupus erythematosus: The role of vasculitis, heart emboli and thrombotic thrombocytopenic purpura. *Ann Neurol* 1988;23:380–4.
- [3] Kaell AT, Shetty M, Lee BCP, Lockshin MD. The diversity of neurologic events in systemic lupus erythematosus: Prospective clinical and computed tomographic classification of 82 events in 71 patients. *Arch Neurol* 1986;43:273–6.
- [4] Sibley JT, Olszynski WP, Decoteau WE, Sundaram MB. The incidence and prognosis of central nervous system diseases in systemic lupus erythematosus. *J Rheumatol* 1992;19:47–52.
- [5] Futrell N, Schultz LR, Millikan C. Central nervous system disease in patients with systemic lupus erythematosus. *Neurology* 1992;42:1649–57.
- [6] Gonzalez-Grespo MR, Blanco FJ, Ramos A, Ciruelo E, Mateo I, Lopez Pino MA, Gomez-Reino JJ. Magnetic resonance imaging of the brain in systemic lupus erythematosus. *Br J Rheumatol* 1995;34:1055–60.
- [7] Mitsias P, Levine SR. Large cerebral vessel occlusive disease in systemic lupus erythematosus. *Neurology* 1994;44:385–93.
- [8] Tan EM, Cohen AS, Fries JF, Masi AT, McShane DJ, Rothfield NF, Schaller JG, Talal N, Winchester RJ. The 1982 revised criteria for the classification of systemic lupus erythematosus. *Arthritis Rheum* 1982;25:1271–7.
- [9] Suzuki Y, Kitagawa Y, Matusoka Y, Fukuda J, Mizushima Y. Severe cerebral and systemic necrotizing vasculitis developing during pregnancy in a case of systemic lupus erythematosus. *J Rheumatol* 1990;17:1408–11.
- [10] Weiner DK, Allen NB. Large vessel vasculitis of the central nervous system in systemic lupus erythematosus: Report and review of literature. *J Rheumatol* 1991;18:748–51.
- [11] Liem MD, Gzehs DJ, Flanders AE. MRI and angiographic diagnosis of lupus cerebral vasculitis. *Neuroradiology* 1996;38:134–6.
- [12] Belmont HM, Abramson SB, Lie JT. Pathology and pathogenesis of vascular injury in systemic lupus erythematosus. *Arthritis Rheum* 1996;39:9–22.
- [13] Yool BD, Coutellier A, Dubois B, Leger JM, Bousser MG. Three cases of spontaneous extracranial vertebral artery dissection. *Stroke* 1990;21:618–25.
- [14] Guard RW, Gotis-Graham I, Edmonds JP, Thomas AC. Aortitis with dissection complicating systemic lupus erythematosus. *Pathology* 1995;27:224–8.
- [15] Sclair M, Nassar H, Bar-Ziv Y, Putterman C. Dissecting aortic aneurysm in systemic lupus erythematosus. *Lupus* 1995;4:71–4.