

Maria Caterina Silveri  
Sandro Misciagna  
Maria Giuseppa Leggio  
Marco Molinari

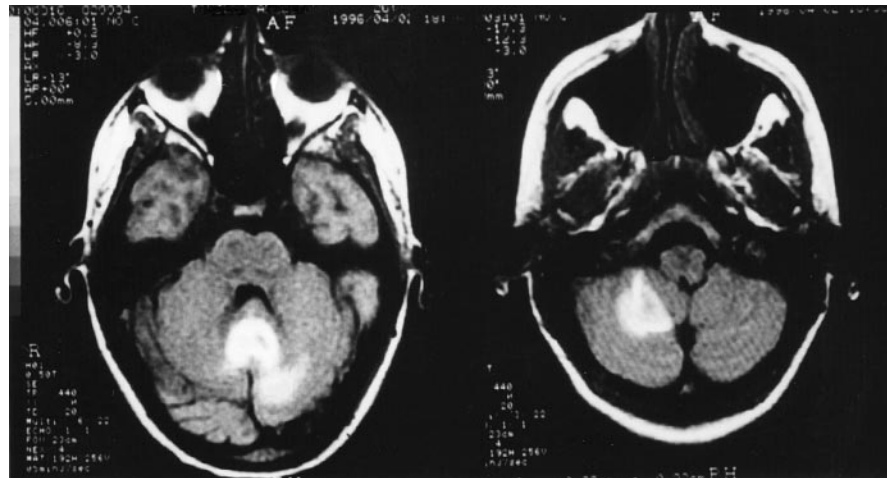
### Cerebellar spatial dysgraphia: further evidence

Received: 30 March 1998  
Received in revised form: 2 July 1998  
Accepted: 18 August 1998

Sirs: In a recent report Silveri et al. [10] described a patient with cerebellar atrophy who had the typical features of peripheral dysgraphia [3], confirming that the cerebellum is involved in cognition [4, 5, 7, 9, 10]. This writing deficit, previously described only in subjects with right supratentorial lesions, is characterized by omission and repetition of strokes and letters and has been related to a deficit in visual and proprioceptive feedback, or in attention to feedback, which allows the updating of graphic motor patterns during sequential hand movement [2, 8]. The authors explained the patient's deficit by hypothesizing deficient coordination between hand movement planning and performance due to a lack of the cerebellar integration between supratentorial areas and proprioceptive afferent from the skeleton and muscles.

We describe a 26-year-old right-handed woman who suffered from the sudden onset of cerebellar symptoms. Magnetic resonance imaging revealed hemorrhage involving the vermis and extending into the right cerebellar hemisphere, the IV ventricle, and to a lesser extent the left cerebellar hemisphere (Fig. 1).

Her score on the Mini-Mental State Examination was 24/30. Overall IQ was 77 (verbal 82, nonverbal 73). Neuropsychological examination revealed mild memory impairment associated with slight constructional apraxia and reduced word flu-



**Fig. 1** Brain magnetic resonance imaging

ency. Signs of peripheral dysgraphia were detected, such as a moderate tendency toward downward sloping lines and strokes, letter omissions, and repetitions (Fig. 2). The patient was requested to write 189 words both in cursive and in print script (Table 1) with her right hand. Writing was only slightly dysmetric, and writing speed was normal (0.37 s per cursive letter, 0.47 s per print letter; three normal subjects with matched age and education: 0.39 s per cursive letter, 0.44 s per print letter). As in other typical cases of peripheral dysgraphia, oral spelling was correct; in other words, the patient was perfectly able to spell the letters forming single words aloud. No significant increase in errors was detected when the patient was requested to write with her eyes closed. Upper-case print writing elicited more errors than lower-case print writing. A few months later no cerebellar sign was detected, and results of the neuropsychological examination was fully normal. Overall IQ was 103 (verbal 107, nonverbal 98).

The patient's deficit was similar to that described previously [10] in a patient who had cerebellar atrophy. Despite different cerebellar pathology (atrophic and diffuse versus vas-



**Fig. 2** Samples of patient's writing errors (arrows)

cular and focal) the two cases presented very similar writing deficits, confirming the role of the cerebellum in "high-order" writing control.

Bower [1] hypothesized that within motor function the cerebellum does not interact with the motor system primarily to produce accurate movements but as a means of controlling the acquisition of sensory data. In this patient errors such as omission and repetition of strokes and letters during the handwriting

**Table 1** Quantitative analysis of patient's writing errors

Kind of error	Print writing		Cursive writing	
	Eyes-open, 189 words	Eyes-closed, 11 words	Eyes-open, 189 words	Eyes-closed, 11 words
Stroke omission	3	2	3	0
Stroke repetition	25	5	16	1
Letter omission	6	0	3	0
Letter repetition	8	0	6	1
Total errors	42	7	28	2

process might be interpreted as “dynamic state estimator” errors [6] (for discussion see [7]) due to the lack of coordination between motor planning and sensory (proprioceptive) afferents from the muscles and skeleton of the hand that follows the disconnection between the motor and premotor cortices (through the corticoponto-cerebellar pathway) and the peripheral afferents (through the spinocerebellar pathway).

In peripheral dysgraphia the eyes-closed condition typically produces a significant worsening of the writing deficit, suggesting that vision compensates for the proprioceptive deficit. In our patient the eyes-closed condition did not produce any worsening of the writing performance, suggesting that she had already lost visual control of writing. This suggests that at least in some cases a cerebellar lesion impairs not only the proprioceptive but also visual control probably by a limitation of the eye movements.

## References

1. Bower JM (1995) The cerebellum as sensory acquisition controller. *Hum Brain Mapping* 2: 12–13
2. Ellis AW (1987) Normal writing processes and peripheral dysgraphias. *Lang Cogn Proc* 3: 99–127
3. Lebrun Y (1976) Neurolinguistic models of language and speech. In: Whitaker H, Whitaker HA (ed) *Studies in neurolinguistics*. Academic, New York, pp 1–30
4. Molinari M, Leggio MG, Silveri MC (1997) Verbal fluency and agrammatism. In: Jeremy D. Schmahmann JD (ed) *The cerebellum and cognition*. Academic, New York, pp 325–339
5. Molinari M, Leggio MG, Solida A, Ciorra R, Misciagna S, Silveri MC, Petrosini L (1997) Cerebellum and procedural learning: evidence from focal cerebellar lesions. *Brain* 120: 1753–1762
6. Paulin MG (1993) The role of the cerebellum in motor control and perception. *Brain Behav Evol* 41: 39–50
7. Schmahmann JD (1996) From movement to thought. The cerebellar contribution to cognitive processes. *Hum Brain Mapping* 4: 174–198
8. Silveri MC (1996) Peripheral aspects of writing can be differentially affected by sensorial and attentional defect: evidence from a patient with afferent dysgraphia and case dissociation. *Cortex* 32: 155–172
9. Silveri MC, Leggio MG, Molinari M (1994) The cerebellum contributes to linguistic production: a case of agrammatic speech following a right hemispheric cerebellar lesion. *Neurology* 44: 2047–2050
10. Silveri MC, Misciagna S, Leggio MG, Molinari M (1997) Spatial dysgraphia and cerebellar lesion: a case report. *Neurology* 48: 1529–1532

M. C. Silveri (✉) · S. Misciagna  
Institute of Neurology,  
Catholic University, Largo A. Gemelli 8,  
I-00168 Rome, Italy  
e-mail: iclnp@unicatt.rm.it;  
Tel.: +39-6-30154333;  
Fax: +39-6-30501909

M. G. Leggio  
Institute of Psychology,  
University of Rome La Sapienza,  
Via dei Marsi, 78, I-00185 Rome,  
and Istituto di Ricovero e Cura  
a Carattere Scientifico,  
S. Lucia, Via Ardeatina, 306,  
I-00179 Rome, Italy

M. Molinari  
Istituto di Ricovero e Cura  
a Carattere Scientifico,  
S. Lucia, Via Ardeatina, 306,  
I-00179 Rome, Italy