

Early rebleeding from intracranial dural arteriovenous fistulas: report of 20 cases and review of the literature

HUGUES DUFFAU, M.D., MANUEL LOPES, M.D., VESNA JANOSEVIC, M.D.,
JEAN-PIERRE SICHEZ, M.D., THIERRY FAILLOT, M.D., LAURENT CAPELLE, M.D.,
MOUNIR ISMAÏL, M.D., AHMAD BITAR, M.D., FRANÇOIS ARTHUIS, M.D.,
AND DENIS FOHANNO, M.D.

Department of Neurosurgery, Hôpital de la Salpêtrière, Paris, France

Object. In this study the authors sought to estimate the frequency, seriousness, and delay of rebleeding in a homogeneous series of 20 patients whom they treated between May 1987 and May 1997 for arteriovenous fistulas (AVFs) that were revealed by intracranial hemorrhage (ICH). The natural history of intracranial dural AVFs remains obscure. In many studies attempts have been made to evaluate the risk of spontaneous hemorrhage, especially as a function of the pattern of venous drainage: a higher occurrence of bleeding was reported in AVFs with retrograde cortical venous drainage, with an overall estimated rate of 1.8% per year in the largest series in the literature. However, very few studies have been designed to establish the risk of rebleeding, an omission that the authors seek to remedy.

Methods. Presenting symptoms in the 20 patients (17 men and three women, mean age 54 years) were acute headache in 12 patients (60%), acute neurological deficit in eight (40%), loss of consciousness in five (25%), and generalized seizures in one (5%). Results of the clinical examination were normal in five patients and demonstrated a neurological deficit in 12 and coma in three. Computerized tomography scanning revealed intracranial bleeding in all cases (15 intraparenchymal hematomas, three subarachnoid hemorrhages, and two subdural hematomas). A diagnosis of AVF was made with the aid of angiographic studies in 19 patients, whereas it was a perioperative discovery in the remaining patient. There were 12 Type III and eight Type IV AVFs according to the revised classification of Djindjian and Merland, which meant that all AVFs in this study had retrograde cortical venous drainage. The mean duration between the first hemorrhage and treatment was 20 days. Seven patients (35%) presented with acute worsening during this delay due to radiologically proven early rebleeding. Treatment consisted of surgery alone in 10 patients, combined embolization and surgery in eight, embolization only in one, and stereotactic radiosurgery in one. Three patients died, one worsened, and in 16 (80%) neurological status improved, with 15 of 16 AVFs totally occluded on repeated angiographic studies (median follow up 10 months).

Conclusions. The authors found that AVFs with retrograde cortical venous drainage present a high risk of early rebleeding (35% within 2 weeks after the first hemorrhage), with graver consequences than the first hemorrhage. They therefore advocate complete and early treatment in all cases of AVF with cortical venous drainage revealed by an ICH.

KEY WORDS • dural arteriovenous fistula • hemorrhage • rebleeding

INTRACRANIAL dural arteriovenous fistulas (AVFs) constitute approximately 10 to 15% of all intracranial vascular malformations,^{2,22,31,40,53} including approximately 6% of all supratentorial and 35% of infratentorial arteriovenous malformations (AVMs).^{1,51}

Although the natural history of these predominantly acquired lesions remains obscure,^{32,37,56} two distinct modes of presentation related to the pattern of drainage may be distinguished:^{7,14} 1) AVF without retrograde cortical venous drainage, with a traditionally benign clinical course;^{1,6,16,19,28,35,46} and 2) AVF with retrograde cortical venous drainage, which presents a high risk of aggressive clinical course with intracranial hemorrhage (ICH).^{2,13,17,18,29,34,47} Many investigators have tried to estimate the risk of bleeding of AVFs,^{2,7-9,14,38,42,47} but to our knowledge there is no series in

which they have tried to evaluate the rate of rebleeding of these AVMs. We report a homogeneous series of 20 patients with AVF revealed by an ICH, with the goal of estimating the frequency, severity, and delay of rebleeding.

Clinical Material and Methods

We retrospectively reviewed the cases of 24 patients with intracranial dural AVFs who were treated at the Pitié-Salpêtrière Hospital between May 1987 and May 1997. Our aim was to study the risk of rebleeding, so only patients with initial hemorrhagic presentation were selected: four patients were therefore excluded.

All dural AVFs had been documented using cerebral angiography, except in one patient, who was nevertheless

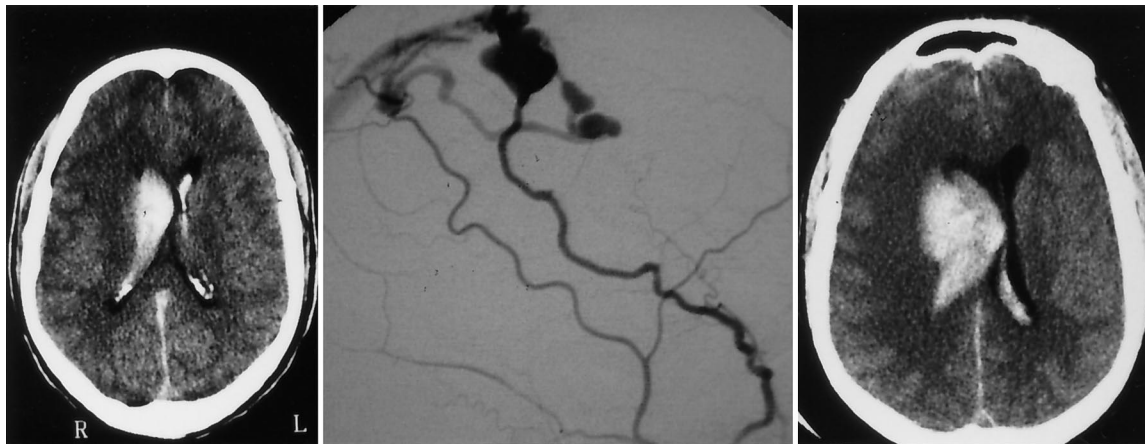


FIG. 1. Case 2. *Left:* Admission CT scan obtained after the patient presented with acute headache, transitory loss of consciousness, and left-sided hemiplegia, showing a right frontal hematoma with intraventricular rupture. *Center:* Angiographic study revealing a frontal AVF fed by both middle meningeal arteries, with ectatic cortical venous drainage toward the SSS (Type IV). *Right:* Repeated CT scan obtained 48 hours later, after neurological deterioration and acute coma, demonstrating rebleeding.

included because of discovery of the AVF during surgery by two senior neurosurgeons. In all cases angiographic studies demonstrated the AVF location, arterial supply, and venous drainage. In addition, these AVFs were graded in five types according to the classification of Djindjian and Merland¹⁵ as modified by Cognard, et al.¹² Type I: free-flow drainage into a sinus; Type II: drainage into a sinus, with retrograde flow into sinus (IIa) or cortical vein (IIb); Type III: cortical venous drainage; Type IV: cortical venous drainage with giant venous ectasia; and Type V: perimedullary venous drainage. The patient's age, gender, presenting symptoms, initial clinical examination, computerized tomography (CT) findings, and clinical and/or CT course before treatment, methods and timing of treatment, and clinical and angiographic follow up were noted in all cases.

Illustrative Case

This 60-year-old man (Case 2) was admitted because of acute headache, transitory loss of consciousness, and left-sided hemiplegia. The patient had presented with an episode of dysphasia 3 weeks previously. His admission CT scan revealed a right frontal hematoma with intraventricular rupture. Angiographic studies demonstrated a right frontal dural AVF with feeding vessels that originated from both middle meningeal arteries. Venous drainage was routed through a cortical venous ectasia toward the superior sagittal sinus ([SSS] Type IV). No emergency treatment was administered because the hematoma was well tolerated. However, the patient's neurological status worsened dramatically 48 hours later, deteriorating into acute coma. A repeated CT scan revealed rebleeding (Fig. 1) with an increase in the size of the hematoma. Emergency surgery was performed, with evacuation of the hematoma and coagulation of the draining vein as close as possible to the malformation. The postoperative course was uneventful, with recovery of consciousness and partial improvement of the left-sided hemiparesis. Complete

occlusion of the AVF was confirmed on postoperative angiographic studies.

Results

Clinical, radiological and treatment characteristics of the 20 patients are summarized in Table 1.

Presenting Symptoms at Admission

Presenting symptoms in the 20 patients (17 men and three women, mean age 54 years) were acute headaches in 12 (60%); acute neurological deficit in eight (40%), which included three dysphasias, two motor deficits, two gait ataxias, and one hemianesthesia; loss of consciousness (three transient) in five (25%); and generalized seizures in one (5%). Results of the clinical examination were normal in five patients, demonstrated a neurological deficit in 12 (11 motor deficits, three aphasias, two hemihyesthesias, two cerebellar syndromes, and two hemianopsias), and a coma in three patients.

Computerized tomography scanning demonstrated intracranial bleeding in all cases: 15 intraparenchymal hematomas (13 supratentorial with intraventricular rupture in two cases, two in the vermis) combined in two patients with acute subdural bleeding, three subarachnoid hemorrhages (SAHs), and two subdural hematomas.

Diagnosis of AVF was made angiographically in 19 patients within 24 hours after hospitalization, whereas it was a perioperative discovery in the remaining patient. There were 12 Type III and eight Type IV AVFs according to the classification of Djindjian and Merland,¹⁵ revised by Gobin, et al.,²¹ which meant that all AVFs had retrograde cortical venous drainage.

Concerning location, angiography revealed eight anterior AVFs (five in the prerolandic region and three in the central area), all with venous drainage into the SSS; four AVFs in the middle fossa that drained into the transverse sinus; and eight posterior AVFs (four parietooccipital that

TABLE 1

*Clinical, radiological, and treatment characteristics of 20 patients with intracranial dural AVF revealed by hemorrhage**

Case No.	Age (yrs), Sex	Presenting Symptoms	Findings on Clinical Examination	CT Findings	Type of AVF	Rebleeding (delay)	Treatment	Status at Follow Up		
								Outcome	Period	Angiogram
1	61, M	headaches	normal	hematoma of vermis	IV	yes (Day 4)	E & S	normal	21 mos	normal
2	60, M	loss of consciousness	hemiplegia	frontal hematoma	IV	yes (Day 2)	S	improved	25 mos	normal
3	46, M	headaches & deficit	cerebellar syndrome	hematoma of vermis	III	yes (Day 13)	S & E	normal	10 mos	normal
4	67, M	headaches & deficit	cerebellar syndrome	thalamic hematoma	IV	yes (Day 13)	S	died (Day 22)	NA	NA
5	55, M	headaches & deficit	monoparesis	subdural hematoma	III	no	E & S	improved	18 mos	normal
6	42, M	loss of consciousness	normal	frontal hematoma	III	no	S	worsened	6 mos	normal
7	68, M	headaches	normal	SAH	III	no	E	normal	2 mos	none
8	42, M	headaches & coma	coma	parietal hematoma	IV	no	S & E	improved	3 mos	normal
9	54, M	headaches & deficit	aphasia	temporal hematoma	III	no	S	improved	12 mos	normal
10	54, M	headaches	hemianopsia, monoparesis	occipital hematoma	IV	no	E & S	normal	9 mos	normal
11	64, M	headaches & deficit	hemiplegia	temporal hematoma & acute sub bleed	III	no	E & S	died (Day 15)	NA	NA
12	44, F	loss of consciousness	aphasia & hemiplegia	frontal hematoma	III	no	S	improved	16 mos	normal
13	52, M	deficit	hemiparesis, hemihyesthesia	rolandic hematoma & SAH	III	no	E & S	normal	6 mos	normal
14	44, M	generalized seizures	coma & hemiparesis	frontal hematoma	III	no	S	improved	7 mos	normal
15	46, M	deficit	monoparesis	parietal hematoma	IV	no	E & S	improved	10 days	normal
16	46, M	deficit	aphasia & hemiparesis	frontal hematoma	III	no	S	improved	2 mos	normal
17	64, M	headaches	coma & hemiparesis	frontal hematoma & acute sub bleed	IV	yes (Hr 8)	S	improved	2 mos	normal
18	74, F	headaches	normal	tentorial SAH	III	no	radiosurgery	normal	12 mos	AVF not occl
19	56, F	headaches	normal	subdural hematoma	III	yes (Days 7 & 8)	S	died (Day 10)	NA	NA
20	52, M	loss of consciousness	hemianopsia, hemiplegia, hemihyesthesia	parietal hematoma	IV	yes (Day 1)	S	improved	24 mos	normal

* E = embolization; NA = not applicable; occl = occluded; S = surgery; sub bleed = subdural bleeding.

drained into the transverse sinus, and four tentorial with drainage joining the torcular in two cases, the vein of Galen in one, and the basilar vein in one).

Evolution of the Lesion

Immediate Treatment. The three comatose patients (Cases 8, 14, and 17) underwent emergency surgery after the first hemorrhage. One of them (Case 17) had presented before the operation with two consecutive episodes of headache; his CT scan revealed two possible ruptures, which were confirmed at surgery. All three of these patients improved postoperatively, with recovery of normal neurological status in two cases.

Delayed Treatment. For the other 17 patients, the mean duration between the first hemorrhage and treatment was 20 days (range 8 hours–5 months). During this delay one patient spontaneously improved (Case 6) and nine remained stable (Cases 5, 7, 9–11, 13, 15, 16, and 18). Treatment consisted of surgery alone in two patients, combined embolization and surgery in five, embolization alone in one, and radiosurgery in one. One patient died of pulmonary embolism, one worsened with residual frontal syndrome, whereas the other eight had a favorable course (three with mild residual neurological deficits and five with complete recovery).

Episodes of Rebleeding. Seven patients (35%) experienced a dramatic worsening of their neurological status.

Among these seven, four deteriorated into acute coma (Cases 1–4) at Days 4, 2, 13, and 13, respectively. Repeated CT scans obtained in all four cases revealed the occurrence of rebleeding with an increase in the size of the hematoma, combined in two cases with hydrocephalus that necessitated implantation of an external ventricular drain. All patients underwent surgical resection of the AVF, with concurrent embolization in two cases. One patient died and three improved (two had complete recovery).

One patient (Case 19) had two consecutive radiologically and surgically proven episodes of subdural rebleeding (Days 7 and 8) but because no angiogram had been obtained, the AVF was discovered only during the third operation. The patient died 10 days later.

One patient (Case 20) presented in an acute coma 24 hours after the first hemorrhage, and two consecutive angiograms revealed an increase in the mass effect on the pericallosal arteries, but no repeated CT scans were obtained. Emergency surgery was performed, with postoperative results including regressive aphasia and hemiparesis.

One patient (Case 12) worsened progressively because of edema but did not experience rebleeding: she underwent surgery and improved, with persistent mild hemiparesis.

In total, we consider that the objective rate of radiologically proven recurrent hemorrhage is four (20%) of 20, with a high probability of early rebleeding in three other

Early rebleeding from intracranial dural AVFs

TABLE 2
Clinical, radiological, and treatment characteristics of seven patients with early rebleeding*

Case No.	Age (yrs), Sex	Presenting Symptoms	Findings on Clinical Examination	CT Findings	Arteriographic Findings (location/type/feeding artery/draining vein)	Outcome Pretreatment	Treatment	Follow Up
1	61, M	acute headaches	meningeal syndrome	hematoma of vermis	tentorial/IV/rt APA, bilat MMA, & Oca/torcular	worsened Day 4: acute headaches & coma; CT scan: rebleeding	3 partial embolizations (Days 8, 21, & 30); Day 64: surgery (Coag V)	normal neuro exam, normal angio (21 mos)
2	60, M	transient dysphasia, headaches & coma 3 wks later	stuporous, lt hemiplegia	rt frontal hematoma w/ intraventricular rupture	rt frontal/IV/bilat MMA/SSS	worsened Day 2: coma CT scan: rebleeding	Day 2: emergency surgery (Coag A & V)	regressive lt hemiparesis, normal angio (25 mos)
3	46, M	acute headaches, vomiting, dysarthria, dysgraphia	cerebellar syndrome	hematoma of vermis	tentorial/III/rt ECA, rt MHA (& rt carotidophthalmic aneurysm)/vein of Galen & SS	worsened Day 13: coma CT scan: rebleeding w/ hydrocephalus led to implantation of EVD	Day 17: surgical evacuation of hematoma & 3 embolizations (Day 25, 3rd & 8th mos)	normal neuro exam, normal angio (10 mos)
4	67, M	repeated acute headaches, gait ataxia	cerebellar syndrome, confusion	lt thalamic hematoma, tentorial SAH	tentorial/IV/lt ECA & ICA/basilar vein	worsened Day 13: coma & rt hemiplegia; CT scan: rebleeding w/ hydrocephalus led to implantation of EVD	Day 20: surgery (Coag V)	Day 22: death by lt temporal hemorrhagic venous infarction
17	64, M	acute headaches, 2nd episode of acute headaches 8 hrs later	coma (GCS 7), lt hemiparesis	rt frontal hematoma w/ 2 ruptures on CT, acute rt SDH	rt frontal/IV/bilat MMA/SSS	immediate treatment	old & new blood in hematoma at emergency surgery: rebleeding (Coag A & V)	persistent lt hemiparesis (2 mos), no aphasia, normal angio
19	56, F	acute headaches & vomiting 4 hrs after head injury w/o coma	meningeal syndrome	lt acute SDH on CT scan obtained 5 days later	no angio	Day 5: evacuation of SDH; Day 7: worsened CT scan: new acute SDH, 1st rebleeding	Day 7: 2nd surgery for SDH; Day 8: 2nd worsening: CT scan: new SDH, 2nd rebleeding	Day 8: 3rd emergency surgery for SDH w/ discovery of middle fossa Type III AVF; Day 10: death
20	52, M	transient coma followed by aphasia	rt hemianopsia, hemiplegia, hemihypesthesia	lt parietooccipital hematoma	lt occipital/IV/lt ECA, ICA, & VA/lt occipital vein & TS	worsened Day 1: coma & rt hemiplegia, no CT scan 2nd angio: increase of mass effect, rebleeding	emergency surgery (Coag A & V)	regressive hemiparesis & aphasia (24 mos); angio: persistence of AVF postop; normalization at 2 yrs by thrombolysis

* Angio = angiogram; APA = ascending pharyngeal artery; Coag A = coagulation of the vein; ECA = external carotid artery; EVD = external ventricular drain; GCS = Glasgow Coma Scale; ICA = internal carotid artery; MHA = meningohypophyseal artery; MMA = meningohypophyseal artery; neuro = neurological; Oca = occipital artery; SDH = subdural hematoma; SS = straight sinus; TS = transverse sinus; VA = vertebral artery.

cases; therefore the overall rate of recurrent hemorrhage was seven (35%) of 20 in our series. The clinical, radiological, and treatment characteristics of these seven patients with early rebleeding are summarized in Table 2.

Overall Outcomes. The overall results showed three deaths, one impairment, and 16 patients with a favorable course (80%); seven of these had mild neurological deficits and nine recovered normal neurological status at a mean follow-up time of 10 months. Sixteen follow-up angiograms were obtained in the patients still alive, and 15 (94%) of 16 of the AVFs were found to be totally occluded.

Discussion

The rate of bleeding of dural AVFs has been studied by many authors^{2,7,8,12,14,17,18,26,27,29,34,38,42,47} and is estimated at approximately 1.8% per year, with a higher risk associated with AVMs with cortical venous drainage^{2,7,9,12,14,31,38,47,54} and tentorial location.^{2,12,14,38,47}

However, publications in which investigators have tried to estimate the rate of rebleeding of dural AVFs revealed by an ICH are very rare. Grisoli, et al.,²³ reported one case of recurrent bleeding observed 12 days after the first hemorrhage from an AVF. Halbach, et al.,²⁴ described eight patients (29%) in a series of 28 with AVF presenting with hemorrhage, and the occurrence of repeated hemorrhages (three of repeated SAH, one of repeated intraventricular rupture) over the course of several weeks in four (50%) of eight patients. King and Martin³⁸ speculated that the risk of early rebleeding is presumably the same as that of pial AVMs, that is, 1 to 2% within 1 month after initial hemorrhage. They concluded that because this risk is low, conservative medical management should be initiated if the patient does not have a large hematoma. On the other hand, Borden, et al.,⁷ reported more recently that three of seven AVFs revealed by an ICH in a series of 14 patients presented with recurrent bleeding after a delay of a few days. These authors were surprised that the literature on the rate of dural AVF rebleeding was so sparse and concluded that AVFs presenting with ICH must be treated quickly.

We describe an original series of 20 patients with dural AVFs with cortical venous drainage, all revealed by ICH, in which seven patients suffered rebleeding within 2 weeks after the first hemorrhage (four cases were radiologically proven and three were highly likely, comprising 20 to 35% of early recurrent hemorrhages).

Interestingly, four of these patients had already presented with one or more episodes of acute headache during the month before the first diagnosed hemorrhage. We postulate that these symptoms were in fact related to previous episodes of bleeding.

In all cases, as has been reported by Borden, et al.,⁷ and Grisoli, et al.,²³ recurrent hemorrhage occurred within a latency period of several hours to several days (Hour 8, Days 1, 2, 2, 4, 13, and 13). Moreover, clinical consequences were always severe; all patients presented with disorders of consciousness at the time of rebleeding.

As for the risk factors of rebleeding, we found them to be similar to the risk factors of a first hemorrhage as previously mentioned: a predominance of Type IV (five

Types IV and two Types III in the seven AVFs that rebled), and a predominance of posterior, notably tentorial, locations (75% of tentorial AVFs in our series rebled).

Considering the high rate of recurrent hemorrhage in AVFs with cortical venous drainage, the short delay, and the grave consequences of the rebleedings, our series provides further support for initiating radical treatment as soon as possible in all cases of dural AVF revealed by a first ICH.

Many treatment strategies for AVF have been described in the literature, including ligation of the feeding arteries,^{5,11,33,49,59,61} coagulation of the nidus and/or venous drainage,^{13,23,38,50,56–58} transarterial^{25,30,36,48,52} or transvenous embolization,^{21,27,55,60} stereotactic radiosurgery,^{10,38,39,43,44} or combinations thereof.^{3,4,20,41,45,54} Although in some cases palliative treatment for control of symptoms seems acceptable (in Type I and even Type II AVFs), the primary goal of treatment remains the complete and early obliteration of AVFs with cortical venous drainage, because of the high risk of bleeding and/or rebleeding. We therefore advocate occlusion of the neck of the draining vein as close as possible to the nidus. We obtained the best results in our series when we opted for surgical treatment.

Conclusions

Intracranial AVFs with leptomeningeal drainage (Types III and IV) represent a subgroup of AVFs with a high rate of hemorrhage, estimated at approximately 1.8% per year in the literature.

Moreover, our series demonstrates the high risk of rebleeding associated with AVFs that have cortical venous drainage (up to 35%) and documents two major points: the possible imminence of rebleeding and the worsening of neurological status at the time of the second hemorrhage.

Consequently, we tend to treat all cases of AVF featuring retrograde leptomeningeal venous drainage as early as possible, particularly when the lesion is revealed by a hemorrhage, even if the first intracranial bleeding is neurologically well tolerated. In these circumstances we advocate surgical treatment with coagulation of the neck of the draining vein as close as possible to the nidus malformation, rather than transvenous embolization or stereotactic radiosurgery.

References

1. Aminoff ML: Vascular anomalies of the intracranial dura mater. *Brain* **96**:601–612, 1973
2. Awad IA, Little JR, Akrawi WP, et al: Intracranial dura arteriovenous malformations: factors predisposing to an aggressive neurological course. *J Neurosurg* **72**:839–850, 1990
3. Barnwell SL, Halbach VV, Dowd CF, et al: A variant of arteriovenous fistulas within the wall of dural sinuses. Results of combined surgical and endovascular therapy. *J Neurosurg* **74**:199–204, 1991
4. Barnwell SL, Halbach VV, Higashida RT, et al: Complex dural arteriovenous fistulas. Results of combined endovascular and neurosurgical treatment in 16 patients. *J Neurosurg* **71**:352–358, 1989
5. Billewicz O, Kamraj-Mazurkiewicz K, Pryczkowski J: Case of congenital arteriovenous fistula fed by the middle meningeal artery. *Neuroradiology* **2**:234–236, 1971

Early rebleeding from intracranial dural AVFs

6. Bitoh S, Sakaki S: Spontaneous cure of dural arteriovenous malformation in the posterior fossa. **Surg Neurol** 12:111–114, 1979
7. Borden JA, Wu JK, Shucart WA: A proposed classification for spinal and cranial dural arteriovenous fistulous malformations and implications for treatment. **J Neurosurg** 82:166–179, 1995
8. Brown RD Jr, Wiebers DO, Nichols DA: Intracranial dural arteriovenous fistulae: angiographic predictors of intracranial hemorrhage and clinical outcome in nonsurgical patients. **J Neurosurg** 81:531–538, 1994
9. Castaigne P, Bories J, Brunet P, et al: Les fistules artérioveineuses méningées pures à drainage veineux cortical. **Rev Neurol** 132:169–181, 1976
10. Chandler HC Jr, Friedman WA: Successful radiosurgical treatment of a dural arteriovenous malformation: case report. **Neurosurgery** 33:139–142, 1993
11. Ciminello VJ, Sachs E Jr: Arteriovenous malformations of the posterior fossa. **J Neurosurg** 19:602–604, 1962
12. Cognard C, Gobin YP, Pierot L, et al: Cerebral dural arteriovenous fistulas: clinical and angiographic correlation with a revised classification of venous drainage. **Radiology** 194:671–680, 1995
13. Collice M, D'Aliberti G, Talamonti G, et al: Surgical interruption of leptomeningeal drainage as treatment for intracranial dural arteriovenous fistulas without dural sinus drainage. **J Neurosurg** 84:810–817, 1996
14. Davies MA, TerBrugge K, Willinsky R, et al: The validity of classification for the clinical presentation of intracranial dural arteriovenous fistulas. **J Neurosurg** 85:830–837, 1996
15. Djindjian R, Merland JJ: **Super-Selective Arteriography of the External Carotid Artery**. Berlin: Springer-Verlag, 1978, pp 405–536
16. Endo S, Kosu K, Suzuki J: Spontaneous regression of posterior fossa dural arteriovenous malformation. **J Neurosurg** 51:715–717, 1979
17. Enker SH: Progression of a dural arteriovenous malformation resulting in an intracerebral hematoma. A case report. **Angiology** 30:198–204, 1979
18. Fardoun R, Adam Y, Mercier P, et al: Tentorial arteriovenous malformation presenting as an intracerebral hematoma. Case report. **J Neurosurg** 55:976–978, 1981
19. Fermand M, Reizine D, Melki JP, et al: Long term follow-up of 43 pure dural arteriovenous fistulae (AVF) of the lateral sinus. **Neuroradiology** 29:348–353, 1987
20. Fransen P, Mathurin P, Pierre P, et al: Interest and necessity of combined neuroradiological and neurosurgical treatment in some cases of dural arterio-venous fistulae. **Acta Neurochir** 121:26–33, 1993
21. Gobin YP, Rogopoulos A, Aymard A, et al: Endovascular treatment of intracranial dural arteriovenous fistulas with spinal perimedullary venous drainage. **J Neurosurg** 77:718–723, 1992
22. Grady MS, Pobereskin L: Arteriovenous malformations of the dura mater. **Surg Neurol** 28:135–140, 1987
23. Grisoli F, Vincentelli F, Fuchs S, et al: Surgical treatment of tentorial arteriovenous malformations draining into the subarachnoid space. Report of four cases. **J Neurosurg** 60:1059–1066, 1984
24. Halbach VV, Higashida RT, Hieshima GB, et al: Transvenous embolization of dural fistulas involving the transverse and sigmoid sinuses. **AJNR** 10:385–392, 1989
25. Halbach VV, Higashida RT, Hieshima GB, et al: Treatment of dural arteriovenous malformations involving the superior sagittal sinus. **AJNR** 9:337–343, 1988
26. Halbach VV, Higashida RT, Hieshima GB, et al: Treatment of dural fistulas involving the deep cerebral venous system. **AJNR** 10:393–399, 1989
27. Halbach VV, Randall TH, Hieshima GB, et al: Dural fistulas involving the transverse and sigmoid sinuses: result of treatment in 28 patients. **Radiology** 163:443–447, 1987
28. Hansen JH, Søgaaard IB: Spontaneous regression of an extra- and intracranial arteriovenous malformation. Case report. **J Neurosurg** 45:338–341, 1976
29. Harding AE, Kendall B, Leonard TJK, et al: Intracerebral haemorrhage complicating dural arteriovenous fistula: a report of two cases. **J Neurol Neurosurg Psychiatry** 47:905–911, 1984
30. Hardy RW Jr, Costin JA, Weinstein M, et al: External carotid cavernous fistula treated by transfemoral embolization. **Surg Neurol** 9:255–256, 1978
31. Houser OW, Baker HL Jr, Rhoton AL Jr, et al: Intracranial dural arteriovenous malformations. **Radiology** 105:55–64, 1972
32. Houser OW, Campbell JK, Campbell RJ, et al: Arteriovenous malformations affecting the transverse dural venous sinus—an acquired lesion. **Mayo Clin Proc** 54:651–661, 1979
33. Hugosson R, Bergström K: Surgical treatment of dural arteriovenous malformation in the region of the sigmoid sinus. **J Neurol Neurosurg Psychiatry** 37:97–101, 1974
34. Ishii K, Goto K, Ihara K, et al: High-risk dural arteriovenous fistulae of the transverse and sigmoid sinuses. **AJNR** 8:1113–1120, 1987
35. Kataoka K, Taneda M: Angiographic disappearance of multiple dural arteriovenous malformations. Case report. **J Neurosurg** 60:1275–1278, 1984
36. Kendall B: Percutaneous embolic occlusion of dural arteriovenous malformation. **Br J Radiol** 46:520–523, 1973
37. Kerber CW, Newton TH: The macro and microvasculature of the dura mater. **Neuroradiology** 6:175–179, 1973
38. King WA, Martin NA: Intracerebral hemorrhage due to dural arteriovenous malformations and fistulae. **Neurosurg Clin North Am** 3:577–590, 1992
39. Kobayashi H, Hayashi M, Noguchi Y, et al: Dural arteriovenous malformations in the anterior cranial fossa. **Surg Neurol** 30:396–401, 1988
40. Kosnik EJ, Hunt WE, Miller CA: Dural arteriovenous malformations. **J Neurosurg** 40:322–329, 1974
41. Lalwani AK, Dowd CF, Halbach VV: Grading venous restrictive disease in patients with dural arteriovenous fistulas of the transverse/sigmoid sinus. **J Neurosurg** 79:11–15, 1993
42. Lasjaunias P, Chiu M, Ter Brugge K, et al: Neurological manifestations of intracranial dural arteriovenous malformations. **J Neurosurg** 64:724–730, 1986
43. Lewis AI, Tomsick TA, Tew JM Jr: Management of tentorial dural arteriovenous malformations: transarterial embolization combined with stereotactic radiation or surgery. **J Neurosurg** 81:851–859, 1994
44. Link MJ, Coffey RJ, Nichols DA, et al: The role of radiosurgery and particulate embolization in the treatment of dural arteriovenous fistulas. **J Neurosurg** 84:804–809, 1996
45. Lucas CP, Zabramski JM, Spetzler RF, et al: Treatment for intracranial dural arteriovenous malformations: a meta-analysis from the English language literature. **Neurosurgery** 40:1119–1132, 1997
46. Magidson MA, Weinberg PE: Spontaneous closure of a dural arteriovenous malformation. **Surg Neurol** 6:107–110, 1976
47. Malik GM, Pearce JE, Ausman JI, et al: Dural arteriovenous malformations and intracranial hemorrhage. **Neurosurgery** 15:332–339, 1984
48. Manaka S, Izawa M, Nawata H: Dural arteriovenous malformation treated by artificial embolization with liquid silicone. **Surg Neurol** 7:63–65, 1977
49. Markham JW: Arteriovenous fistula of the middle meningeal artery and the greater petrosal sinus. **J Neurosurg** 18:847–848, 1961
50. Martin NA, King WA, Wilson CB, et al: Management of dural arteriovenous malformations of the anterior cranial fossa. **J Neurosurg** 72:692–697, 1990
51. Nabors MW, Azzam CJ, Albanna FJ, et al: Delayed postopera-

- tive dural arteriovenous malformations: report of two cases. **J Neurosurg** **66**:768–772, 1987
52. Nakstad PH, Bakke SJ, Hald JK: Embolization of intracranial arteriovenous malformations and fistulas with polyvinyl alcohol particles and platinum fiber coils. **Neuroradiology** **34**: 348–351, 1992
 53. Newton TH, Cronqvist S: Involvement of the dural arteries in intracranial arteriovenous malformations. **Radiology** **93**: 1071–1078, 1969
 54. Pierot L, Chiras J, Meder JF, et al: Dural arteriovenous fistulas of the posterior fossa draining into subarachnoid veins. **AJNR** **13**:315–323, 1992
 55. Roy D, Raymond J: The role of transvenous embolization in the treatment of intracranial dural arteriovenous fistulas. **Neurosurgery** **40**:1133–1144, 1997
 56. Sundt TM Jr, Piepgras DG: The surgical approach to arteriovenous malformations of the lateral and sigmoid dural sinuses. **J Neurosurg** **59**:32–39, 1983
 57. Thompson BG, Doppman JL, Oldfield EH: Treatment of cranial dural arteriovenous fistulae by interruption of leptomeningeal venous drainage. **J Neurosurg** **80**:617–623, 1994
 58. Tomlinson FH, Rüfenacht DA, Sundt TM Jr, et al: Arteriovenous fistulas of the brain and the spinal cord. **J Neurosurg** **79**:16–27, 1993
 59. Urdanibia JF, Silvela J, Soto M: Occipital dural arteriovenous malformations. **Neuroradiology** **7**:57–64, 1974
 60. Urtasun F, Biondi A, Casaco A, et al: Cerebral dural arteriovenous fistulas: percutaneous transvenous embolization. **Radiology** **199**:209–217, 1996
 61. Wallner RJ, Fischer M: Scintiangiographic demonstration of a dural arteriovenous malformation. **J Nucl Med** **23**:793–794, 1982

Manuscript received December 2, 1997.

Accepted in final form August 18, 1998.

Address reprint requests to: Hugues Duffau, M.D., Service de Neurochirurgie 1, Hôpital de la Salpêtrière, 47 Boulevard de l'Hôpital, 75651 Paris, Cedex 13, France.