

# Cerebellar Hemorrhage after Supratentorial Surgery for Treatment of Epilepsy: Report of Three Cases

Elza Márcia Yacubian, M.D., Marli M. de Andrade, M.D.,  
Carmen Lisa Jorge, M.D., Rosa Maria Valério, M.D.

Epilepsy Program of the Hospital das Clínicas da Faculdade de Medicina da Universidade de São Paulo, São Paulo, Brazil

**OBJECTIVE AND IMPORTANCE:** We report three cases of cerebellar hemorrhage complicating supratentorial craniotomies for the treatment of epilepsy. In a literature review, we identified only four similar cases of cerebellar hemorrhage after temporal lobectomy for the treatment of epilepsy.

**CLINICAL PRESENTATION AND RESULTS:** Three young and otherwise healthy patients underwent frontal, occipital, and temporal resections for the treatment of refractory epilepsy. The hemorrhage manifested as peduncular tremor, ataxia, and decerebrate posturing presenting early in the postoperative period. The diagnosis was established by computed tomography and/or magnetic resonance imaging. Benign outcomes were observed for all patients.

**CONCLUSION:** Based on the available data, it is our opinion that brain dislocation resulting from excessive intraoperative cerebrospinal fluid drainage is a possible mechanism for this rare complication of supratentorial craniotomy. The overdrainage seems to be less hazardous when the procedure is performed for the removal of space-occupying mass lesions. In contrast, the resection of nonexpanding tissues, such as in lobectomies for the treatment of epilepsy, may be an additional risk factor, because the incidence of this complication seems to be higher in these situations. (Neurosurgery 45:159-162, 1999)

**Key words:** Cerebellar hemorrhage, Epilepsy surgery, Supratentorial craniotomies

Postoperative parenchymal hemorrhage at a remote site in the brain is a well-recognized, albeit rare, complication of craniotomies. In 1987, König et al. (6) reported four cases of postoperative cerebellar hemorrhage in a series of 1350 supratentorial craniotomies. In 1988, Kalfas and Little (5), in a survey of 4992 intracranial procedures performed during a 11-year period, found only four cases of postoperative parenchymal hemorrhage remote from the surgical site. None of these cases involved cerebellar hemorrhage after a supratentorial craniotomy. In 1996, Toczek et al. (9) reported four cases of cerebellar hemor-

rhage complicating supratentorial surgery for the treatment of epilepsy. All cases followed temporal lobectomies, occurring in 4.9% of their series of temporal lobectomies performed in a 5-year period. We report three cases of similar complications, occurring after frontal, temporal, and occipital resections for the treatment of refractory epilepsy.

## CASE REPORTS

### Patient 1

A 29-year-old man presented with a history of complex partial seizures since he was 10 years of age.

### Examination

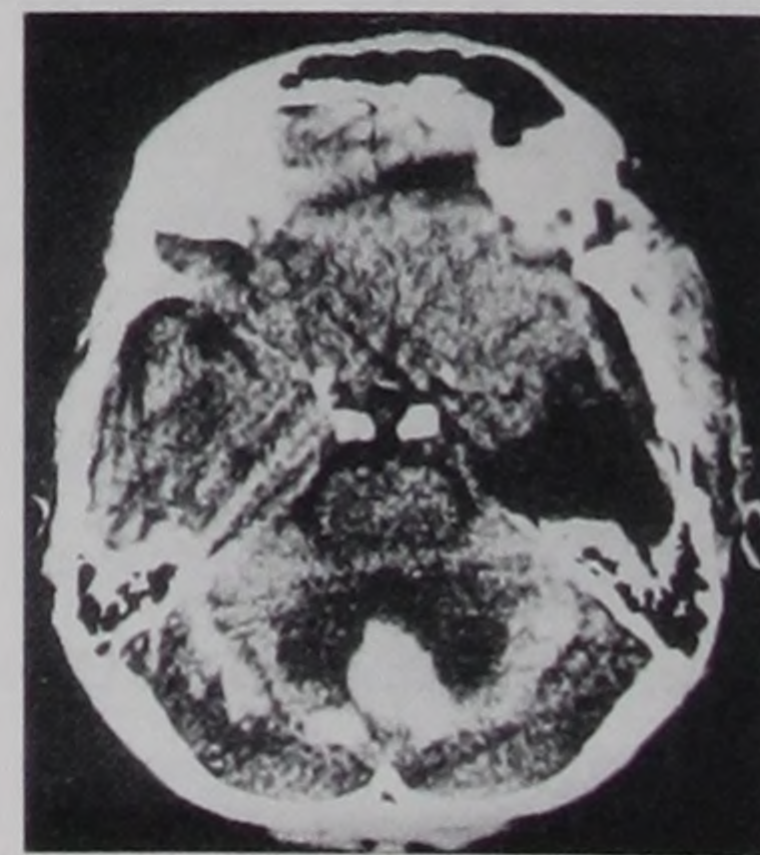The neurological examination was unremarkable. Neuropsychological testing revealed a verbal intelligence quotient of 65 and a performance intelligence quotient of 71. The electroencephalograms showed basal left temporal epileptiform discharges, and mesial temporal seizure onset was documented by video-electroencephalography. Magnetic resonance imaging (MRI) showed left mesial temporal sclerosis. Interictal single photon emission computed tomography revealed left temporal hypoperfusion. The patient was normotensive, and there was no laboratory evidence of coagulopathy. The patient was receiving phenytoin (PHT).

### Operation

On March 3, 1993, with the patient supine and his head turned to the right, a standard temporal craniotomy for a left 4.5-cm anterior temporal lobectomy with amygdalohippocampectomy was performed without complications. The temporal horn was opened. The patient underwent drainage via subgaleal suction for 2 days after surgery. Histopathological analysis confirmed mesial temporal sclerosis.

### Postoperative course

The patient did not awaken from anesthesia in the immediate postoperative period and exhibited decerebrate posturing. Postoperative blood pressure and coagulation test results were normal. Computed tomographic scans obtained 6 hours after surgery showed hemorrhage involving the vermis and both cerebellar hemispheres (Fig. 1). The



**FIGURE 1.** Patient 1. Extensive hemorrhage involving the vermis and both cerebellar hemispheres was demonstrated

by postoperative computed tomography.

patient was treated conservatively and exhibited gradual improvement during a 4-day period. Cerebellar ataxia persisted for approximately 10 days. The patient has been seizure-free since the operation.

### Patient 2

A 10-year-old boy presented with medically refractory epilepsy characterized by up to 20 hypermotor seizures per day since he was 19 months of age.

#### Examination

The neurological examination results were unremarkable, and the intelligence quotient was in the borderline range. Video-electroencephalographic monitoring showed epileptiform discharges and seizure onset in the frontal lobes. MRI suggested mesial right frontal focal cortical dysplasia in the mesial frontal lobe on the right. Ictal single photon emission computed tomographic scans showed hyperperfusion in the same region. The patient received sodium valproate (VPA), carbamazepine (CBZ), and clonazepam before surgery. The plasma level of VPA was 42  $\mu\text{g}/\text{ml}$ , and the CBZ level was 7.8  $\mu\text{g}/\text{ml}$ . The prothrombin time, activated partial thromboplastin time, thrombin time, and platelet count at the time of the preoperative laboratory assays were normal.

#### Operation

The mesial frontal lesion was resected via a right frontal craniotomy performed on March 23, 1993, with the patient in the supine position and his head slightly extended. Surgery was completed without complications. The ventricle was not opened, and no drain was placed. The patient received PHT during the procedure. Histological examination of the surgical specimen ( $5 \times 4 \times 1$  cm) revealed Taylor's type cortical dysplasia.

#### Postoperative course

Shortly after the patient recovered from anesthesia, bilateral peduncular tremor was observed; the tremor persisted for 3 days. The patient remained fully alert, without other neurological signs. His blood pressure remained within the normal range, and there was

no laboratory evidence of coagulopathy. The serum PHT level was within the therapeutic range. Computed tomographic scans obtained 12 hours after surgery showed bilateral vermian hemorrhage. MRI scans confirmed two symmetrical nodular hemorrhage areas in the superior cerebellar peduncles (Fig. 2). One week later, the neurological examination results were normal. The patient has been seizure-free since the operation.

### Patient 3

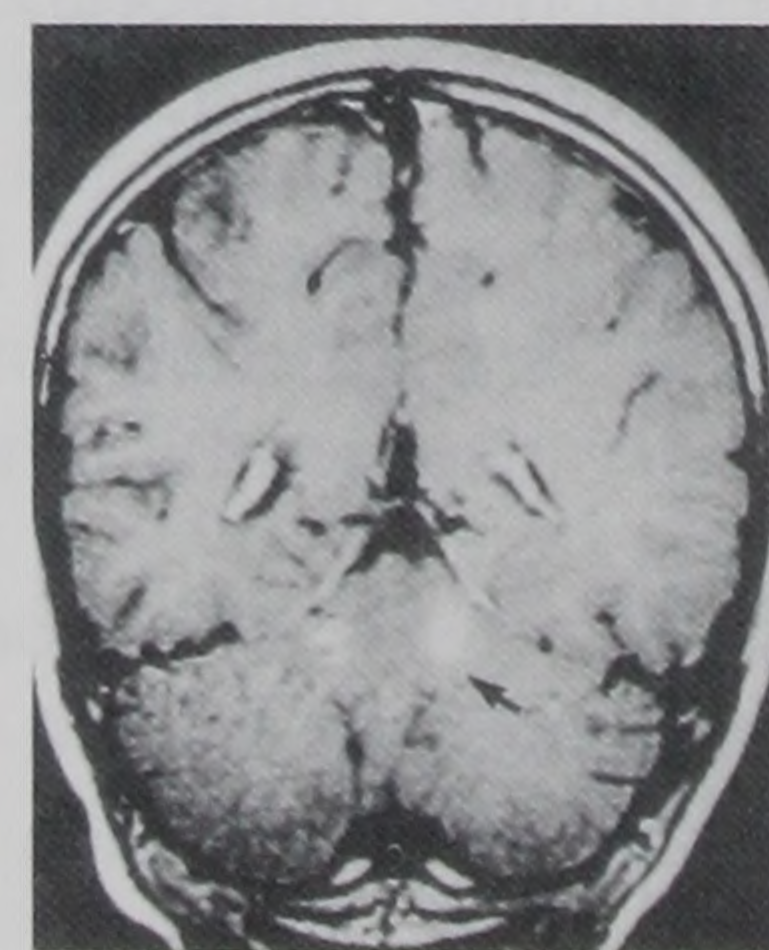
A 20-year-old man experienced frequent left hemifield visual paroxysms followed by complex partial seizures since the age of 8 years. At admission, the patient was receiving CBZ, VPA, vigabatrin, and clobazam. The CBZ plasma level was 12  $\mu\text{g}/\text{ml}$ , and the VPA level was 56  $\mu\text{g}/\text{ml}$ .

#### Examination

The neurological examination results were normal. Electroencephalograms showed continuous epileptiform discharges, which were partially abolished by eye-opening, occurring over the temporoparieto-occipital areas and being more prominent on the right, where fast activity was seen during the seizures. The MRI results were normal, and interictal and ictal single photon emission computed tomographic scans showed hyperperfusion of the posterior areas of the right hemisphere. Preoperative laboratory values, including prothrombin time, activated partial thromboplastin time, thrombin time, and platelet count, were normal.

#### Operation

On April 19, 1994, the patient underwent extensive electrocorticography-guided resection in the right temporoparieto-



**FIGURE 2.** Patient 2. This coronal T1-weighted MRI scan shows hemorrhage as a bilateral nodular hypersignal lesion in both superior cerebellar peduncles.

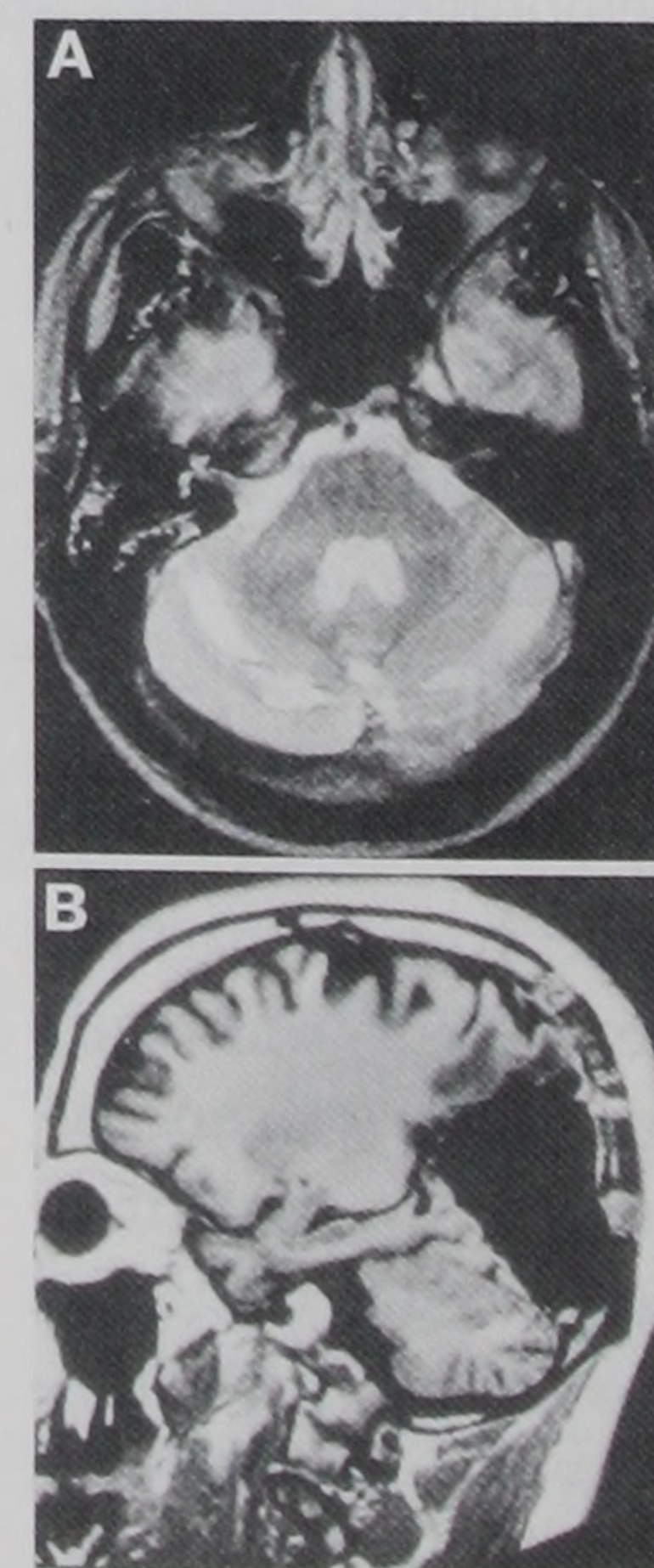
occipital region. The patient was placed in a left lateral decubitus position with his head slightly turned to the left. The procedure was uneventful, and the patient received PHT intraoperatively. The right occipital horn of the lateral ventricle was opened. A subgaleal suction drain was left in place for 4 days. Histopathological analysis showed mild gliosis.

#### Postoperative course

Postoperatively, the patient was fully conscious and experienced mild headache, dizziness, and one episode of vomiting. The examination showed left homonymous hemianopsia, mild gait ataxia, and nystagmus. The PHT levels were within the therapeutic range. In the postoperative period, the patient's systolic blood pressure ranged between 130 and 150 mm Hg, with one pressure peak of 180/80 mm Hg. Laboratory tests did not indicate coagulopathy. Computed tomographic scans obtained 12 hours after surgery revealed extensive hemorrhage in both cerebellar hemispheres, which was confirmed by MRI (Fig. 3). The evolution was benign. One week later, a neurological examination revealed the expected left homonymous hemianopsia and no cerebellar signs. The patient adapted to the visual-field deficit within a few months and has been seizure-free since the operation.

### DISCUSSION

Postoperative brain hemorrhage at sites distant from the craniotomy is a



**FIGURE 3.** Patient 3. *A*, postoperative MRI scan showing extensive hemorrhage involving both cerebellar hemispheres. *B*, T1-weighted MRI scan (sagittal view) showing the extent of the parieto-occipital resection and the area of hemorrhage in the cerebellum.

rare occurrence (1, 6, 8–11, 13). The precise mechanisms underlying these bleeding episodes are not known. Common predisposing factors for cerebral hemorrhage, such as arterial hypertension, underlying occult brain lesions, or coagulopathy, were lacking in most of the reported cases. The mechanisms for infratentorial hemorrhage after infratentorial craniotomies, infratentorial hemorrhage after supratentorial craniotomies, and supratentorial hemorrhage after infratentorial craniotomies may not be the same. Some authors suggest that multiple mechanisms may play a role in these complications (6, 9, 13). The single most common finding in the literature is the fact that the bleeding presents early in the postoperative course, suggesting that it develops during or soon after surgery (1, 5, 8, 9).

Patients subjected to posterior fossa procedures in the sitting position may develop supratentorial hemorrhage because of downward displacement of the brain and disruption of subcortical vessels or cortical bridging veins. When the patient lies supine, hyperperfusion may cause intracerebral hemorrhage. The majority of the supratentorial hemorrhagic episodes after infratentorial craniotomies that were reviewed by Brisman et al. (1) were observed in patients who were surgically treated in the sitting position, although Kalfas and Little (5), who analyzed the incidence of postoperative hemorrhage in the largest published series, concluded that the position of the patient is of little importance.

The mechanisms underlying posterior fossa/cerebellar hemorrhage after supratentorial craniotomies are more difficult to understand. In 1996, Brisman et al. (1) found 13 cases in a thorough review of the data published between 1978 and 1993, and they added 3 other cases of their own. In the same year, Papanastassiou et al. (8) reported 5 additional cases. These data (1, 8) showed that the hemorrhage occurred after frontotemporal craniotomy for aneurysm clipping in 11 of 21 cases and after surgical treatment of parasellar tumors in 5 cases.

In 1996, Toczek et al. (9) reported four cases of cerebellar hemorrhage complicating temporal lobectomies for treatment of epilepsy, which represented 4.9% of their

5-year series of temporal lobectomies. Our three cases included temporal, frontal, and occipital lobectomies for treatment of epilepsy and represented 3.5% of the lobectomies or corticectomies performed during the previous 5 years. These rates are higher than the 0.3 to 0.5% incidence of cerebellar hemorrhage after supratentorial craniotomy reported by König et al. (6) and by Papanastassiou et al. (8). The overall incidence of remote hemorrhage in a survey of 4992 intracranial procedures published by Kalfas and Little (5) was 0.15%. That series included subdural and extradural hematomas.

The currently available data suggest that there is a greater likelihood of postoperative hemorrhage in the cerebellum after a supratentorial craniotomy when cerebrospinal fluid has been extensively drained during surgery. This condition occurs, for example, when the ventricles, basal cisterns, or sylvian fissure is widely opened (1, 6, 8, 9). Postoperative drainage may provide an additional risk. Dacey (2), commenting on the series reported by Brisman et al. (1), suggested that medial sylvian/tentorial approaches to the basal cisterns might disturb the venous drainage of the cerebellar vermis.

We think that mechanical shifting of the cerebellum, resulting from cerebrospinal fluid drainage, is the mechanism most frequently involved in tearing of the superior vermian veins or their tributaries or increases in their transmural pressure (6, 13), leading to hemorrhage. The overdrainage seems less hazardous when the procedure is performed for the removal of space-occupying lesions (6, 13). We think that in these situations the displacement of the brain back to its normal position rectifies the disturbed venous circulation, rather than worsening it. The resection of nonexpanding lesions, such as in lobectomies for the treatment of epilepsy, causes brain displacement. This could explain the higher incidence of this complication in epilepsy series. Other mechanisms mentioned in the literature seem to be less important in cerebellar hemorrhage after supratentorial craniotomies.

All patients in our series were young and otherwise healthy. The isolated postoperative hypertensive peak recorded for Patient 3 is more likely a consequence

than the cause of the intracranial bleeding. At the time of this recording, the patient already showed signs of intracranial hypertension. Administration of VPA may eventually increase the risk of surgical bleeding (3, 4) but is unlikely to be the cause of the bleeding in our patients. Ward et al. (12) verified that preoperative VPA administration does not increase blood loss during temporal lobectomies.

Postoperative cerebrospinal fluid drainage from epidural/subgaleal suction drains may play an additional role. However, in both our series and other published series, the placement of a drain was not always performed (1). Extreme rotation or flexion of the neck, leading to hemorrhage (1, 8) attributable to venous obstruction, was not seen in our series. Head positioning that might jeopardize jugular blood flow could be promptly detected by the surgeon on the basis of brain swelling and easily corrected by appropriate head repositioning early in the operation. Our patients experienced a benign course and full recovery. No single factor could predict a benign outcome (7).

## ACKNOWLEDGMENT

We thank Dr. Milton K. Shibata for suggestions and review of the manuscript.

Received, August 11, 1998.

Accepted, February 26, 1999.

Reprint requests: Elza Márcia Targas Yacubian, M.D., Department of Neurology, Hospital das Clínicas da Faculdade de Medicina da Universidade de São Paulo, Av. Dr. Eneas de Carvalho Aguiar 255, Room 5011, 05403.000 São Paulo, São Paulo, Brazil.

## REFERENCES

1. Brisman MH, Bederson JB, Sen CN, Germano IM, Moore F, Post KD: Intracerebral hemorrhage occurring remote from the craniotomy site. *Neurosurgery* 39:1114–1122, 1996.
2. Dacey RG Jr: Intracerebral hemorrhage occurring remote from the craniotomy site. *Neurosurgery* 39:1121, 1996 (comment).
3. Delgado MR, Riela AR, Mills J, Browne R, Roach ES: Thrombocytopenia secondary to high valproate levels in children with epilepsy. *J Child Neurol* 9:311–314, 1994.

4. Gidal B, Spencer N, Maly M, Pitterle M, Williams E, Collins M, Jones J: Valproate-mediated disturbances of hemostasis: Relationship to dose and plasma concentration. *Neurology* 44:1418-1422, 1994.
5. Kalfas IH, Little JR: Postoperative hemorrhage: A survey of 4992 intracranial procedures. *Neurosurgery* 23:343-347, 1988.
6. König A, Laas R, Herrmann H-D: Cerebellar haemorrhage as a complication after supratentorial craniotomy. *Acta Neurochir (Wien)* 88:104-108, 1987.
7. Melamed N, Satya-Murti S: Cerebellar hemorrhage: A review and reappraisal of benign cases. *Arch Neurol* 41:425-428, 1984.
8. Papanastassiou V, Kerr R, Adams C: Contralateral cerebellar hemorrhagic infarction after pterional craniotomy: Report of five cases and review of the literature. *Neurosurgery* 39:841-852, 1996.
9. Toczek MT, Morrell MJ, Silverberg GA, Lowe GM: Cerebellar hemorrhage complicating temporal lobectomy. *J Neurosurg* 85:718-722, 1996.
10. van Calenbergh F, Goffin J, Plets C: Cerebellar hemorrhage complicating supratentorial craniotomy: Report of two cases. *Surg Neurol* 40:336-338, 1993.
11. Waga S, Shimosaka S, Sakakura M: Intracerebral hemorrhage remote from the site of initial neurosurgical procedure. *Neurosurgery* 13:662-665, 1983.
12. Ward MM, Barbaro NM, Laxer KD, Rampil IJ: Preoperative valproate administration does not increase blood loss during temporal lobectomy. *Epilepsia* 37:98-101, 1996.
13. Yoshida S, Yonekawa Y, Yamashita K, Ihara I, Morooka Y: Cerebellar hemorrhage after supratentorial craniotomy: Report of three cases. *Neurol Med Chir (Tokyo)* 30:738-743, 1990.

### COMMENTS

This reports adds more cases to the growing number of hemorrhagic episodes distant from the site of surgery. We are convinced that this apparently rare complication is more frequent but has not been adequately reported. In our own series of more than 850 resections for epilepsy treatment, there were two cases of cerebellar hemorrhage after temporal lobe surgery, with excellent postoperative recovery. Interestingly, the computed tomographic scans for our patients were very similar to the results pre-

sented in *Figures 1* and *3A* of this article. We think that this may be primary hemorrhaging into one of the fissures that only later extends into the parenchyma of the cerebellum. Valproate-induced coagulation disorders are routinely treated in our service with preoperative administration of desmopressin, so clotting problems are unlikely. Clotting disorders seem unlikely to provide an explanation for hemorrhage distant from the surgical site in any event, because hemorrhage primarily requires a leak in the vessel. Unfortunately, the authors were unable to identify clear reasons why these hemorrhagic episodes occurred; therefore, this case report makes no further contribution to our understanding of the pathogenesis of this complication.

Dirk Van Roost  
Johannes Schramm  
Bonn, Germany

## Symptomatic Spinal Epidural Lipomatosis after Local Epidural Corticosteroid Injections: Case Report

David I. Sandberg, M.D., Michael H. Lavyne, M.D.

Division of Neurosurgery, Weill Medical College of Cornell University, New York Presbyterian Hospital-Cornell Campus, New York, New York

**OBJECTIVE AND IMPORTANCE:** Spinal epidural lipomatosis, which causes symptomatic compression of neural elements, is a well known but uncommon complication of Cushing's syndrome. Spinal epidural lipomatosis has been reported frequently in association with chronic systemic corticosteroid therapy, but thus far only one case has been attributed to local epidural corticosteroid injections.

**CLINICAL PRESENTATION:** We report another case of symptomatic spinal epidural lipomatosis after epidural corticosteroid injections. This is the first such case documented by magnetic resonance imaging and confirmed with surgical exploration.

**INTERVENTION:** The patient's symptoms of neurogenic claudication resolved after lumbar laminectomy in the region of previous corticosteroid injections and the removal of epidural fat, which was compressing the thecal sac.

**CONCLUSION:** This case should alert clinicians that epidural lipomatosis, which causes symptomatic thecal sac compression, is a possible complication, not only of systemic glucocorticoid therapy, but also of local epidural corticosteroid injections. (*Neurosurgery* 45:162-165, 1999)

**Key words:** Corticosteroid injections, Epidural lipomatosis, Lumbar neurogenic claudication

Spinal epidural lipomatosis causing neurological deficits has been most frequently reported in the setting of Cushing's syndrome. The majority of cases have been reported in association with exogenous systemic corticosteroid treatments for a variety of medical conditions (4), including rheumatoid arthritis (juvenile and adult) (2, 13, 31), radiation pneumonitis (28), Graves's ophthalmopathy (19), dermatomyositis (5), asthma (8, 14, 22, 24, 25), sarcoidosis (22), Crohn's colitis (22), periarteritis nodosa (10), systemic lupus erythematosus (12, 15), and organ transplantation (8, 10, 11, 16, 18, 30). Symptomatic spinal epidural lipomatosis also has been attributed to increased systemic glucocorticoid levels caused by Cushing's disease (6, 19, 27), adrenal tumors (20), and anabolic steroid use by bodybuilders (9). Idiopathic cases of spinal epidural lipomatosis in the absence of Cushing's syndrome also have been reported rarely, primarily in obese individuals (3, 17, 21, 23, 26, 29).

Spinal epidural lipomatosis secondary to exogenous administration of glucocorticoids has been reported almost exclusively in association with systemic treatments. Only one case has previously been attributed to epidural corti-