

Shinichiro Maeshima
Mari Nakagawa
Tomoaki Terada
Kunio Nakai
Toru Itakura
Norihiko Komai
Peter Roger

Transcortical mixed aphasia from ischaemic infarcts in a non-right handed patient

Received: 24 November 1997
Received in revised form: 26 October 1998
Accepted: 8 November 1998

Sirs: Transcortical mixed aphasia (TMA), which is characterized by a severely reduced verbal output and impaired language comprehension in the presence of echolalic repetition and automatic completion of open-end sentences [9, 10], has only rarely been reported. The localization of lesions producing TMA is variable [16, 20]. Albert et al. [1] reported that the syndrome is seen most often with diffuse or multifocal pathological changes that involve both anterior and posterior left hemisphere cortical association areas but spare the perisylvian language core. Similarly, Geschwind et al. [9] maintain that this condition is caused by anterior and posterior lesions of the left hemisphere when the perisylvian speech area is intact, and refer to it as 'the syndrome of isolation of speech areas'. Recently some investigators [3, 5] have suggested that the mechanism which preserves repetition in transcortical aphasia is linked to an exceptional ability for repetition of the right hemisphere. We describe a patient with TMA who underwent an amyntal test to determine hemispheric language dominance.

The patient was a 53-year-old Japanese man with 9 years of school education and employed as an office worker. His hand dominance can

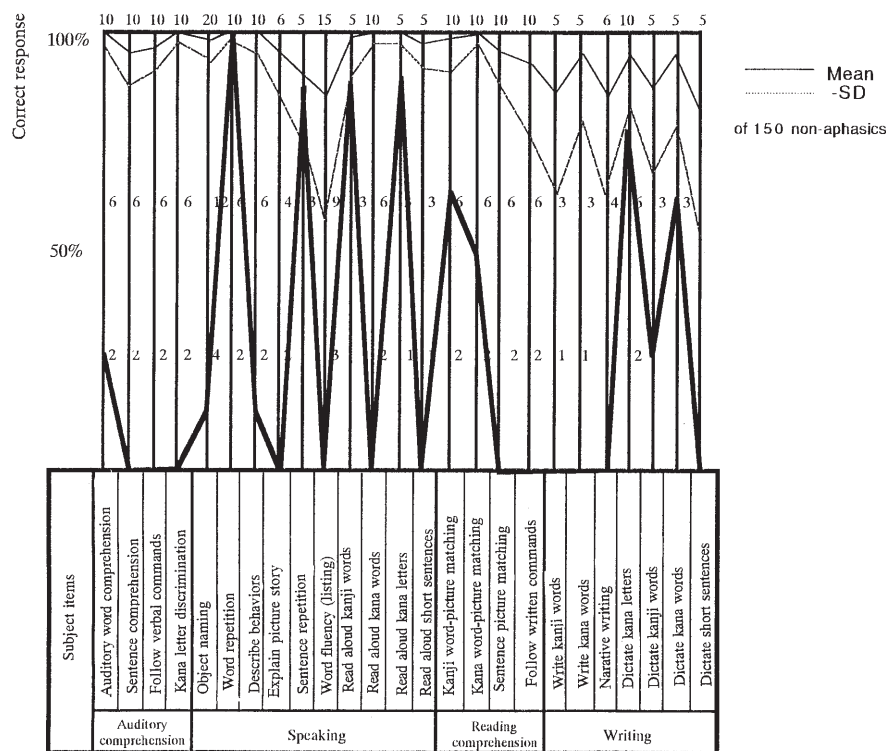


Fig. 1 Profile of Standard Language Test of Aphasia

best be described as "mixed"; as a child he was taught to write, draw and use chopsticks with his right hand, and as an adult these activities are thus performed with the right hand, while throwing, brushing and cutting are performed with the left hand. His daughter is left-handed. He had a 10-year history of diabetes mellitus and hypertension, but no prior history of neurological problems. He suddenly began to exhibit speech disturbance and was referred for diagnosis to our Neurological Surgery Unit. Initially he was completely conscious and fully oriented but manifested a right homonymous hemianopsia. There was no apparent motor paralysis or sensory disturbance.

The patient spoke little of his own volition, and often demonstrated echolalia when he was questioned. His phonological structure was clear. Formal language assessment was undertaken 2 weeks after the onset of

symptoms, using the Standard Language Test of aphasia [18]. The results are presented in Fig. 1. When presented with picture-description tasks, the patient exhibited perseveration and literal paraphasic errors. This was in contrast to the full ability to repeat phonemes and short sentences (some five or six words). Reading aloud of *kanji* (Chinese character-based) words was preserved and reading aloud of *kana* (syllable-based) letters was partially spared; however, the patient was unable to read aloud *kana* words or short sentences. Agraphia was almost total for both *kanji* and *kana*; however, writing to dictation of *kana* letters and single words (*kanji* and *kana*) was partially preserved. Testing also revealed some constructional apraxia but no evidence of oral, ideomotor or ideational apraxia. On the Wechsler Adult Intelligence Scale-Revised his performance intelligence quotient (IQ) was 55. Verbal IQ was unmeasurable in the presence of aphasia.

Magnetic resonance imaging revealed cerebral infarcts in the left

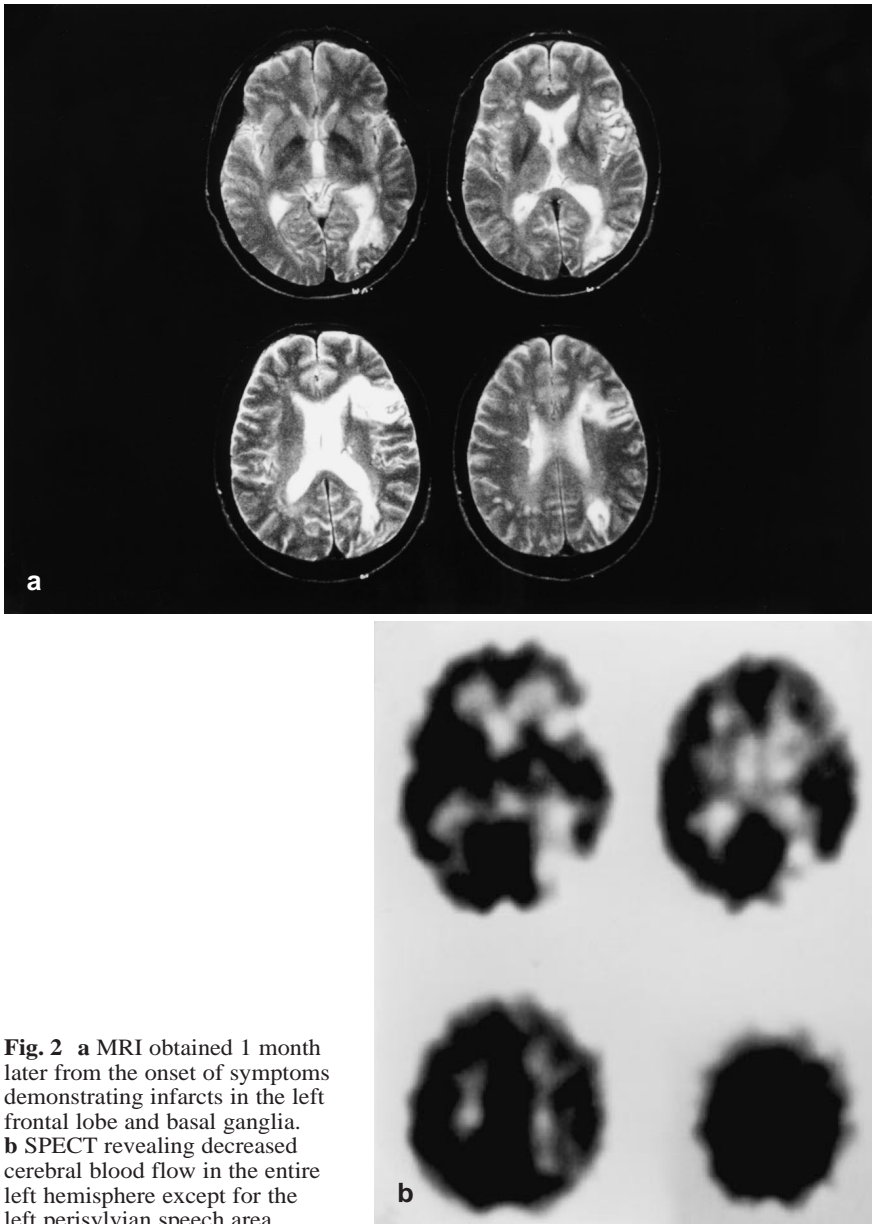


Fig. 2 **a** MRI obtained 1 month later from the onset of symptoms demonstrating infarcts in the left frontal lobe and basal ganglia. **b** SPECT revealing decreased cerebral blood flow in the entire left hemisphere except for the left perisylvian speech area

frontal and parieto-occipital lobes involving the inferior frontal gyrus and angular gyrus (Fig. 2a). Single-photon emission computed tomography (SPECT) revealed a wider area of low perfusion over the entire left hemisphere except for part of the left perisylvian speech areas (Fig. 2b). Cerebral angiography was performed via transfemoral catheterization of the internal carotid artery 3 weeks after admission, and revealed a stenosis of the left internal carotid artery. Informed consent was obtained to perform the amyntal test

(Wada test) via the left internal carotid artery to determine hemispheric language dominance. The patient was instructed to raise both arms, and a dose of 100 mg sodium amobarbital in a 10% saline solution was band-injected. The drug effect was confirmed by the presence of hemiplegia. Before the injection the patient was able to repeat a short sentence of five or six words and read a few words aloud. For 6 min following the injection he could not repeat or read any words. After a certain interval his repetition ability

recovered. These findings suggest that the left hemisphere was dominant for language functions, including repetition.

Spontaneous speech was markedly reduced in this patient, and he often demonstrated echolalia. His object naming, verbal comprehension, reading and writing were also severely disturbed. However, as discussed above his ability to repeat phonemes and short sentences was fully preserved. His language disorder was thus classified as TMA. Although Bogouslavsky et al. [6] reported four cases of TMA among 1200 patients with acute cerebrovascular disorders, the symptoms disappeared over a period of several weeks in all of these cases.

It has classically been considered that in transcortical aphasia, repetition is carried out by the spared left perisylvian area, i.e., Heschl's gyrus – Wernicke's area, Broca's area, the inferior left precentral gyrus, and their interconnections [9]. In support of this, several neuropathological and radiological studies have shown that transcortical aphasia can result from acute brain lesions surrounding the speech area, thus potentially disconnecting the intact perisylvian language zone from the peripheral brain areas that may be essential for meaning and intention [19].

We have previously reported a case with TMA due to subcortical haemorrhage in the left parietal lobe [12] and a case following a left frontoparietal infarct caused by vasospasm after subarachnoid haemorrhage [15], and have also speculated that TMA is caused by functional isolation of the perisylvian speech area due to disconnection from surrounding areas. We have therefore stressed the importance of SPECT in the detection of lesions responsible for aphasia [13]. In the case presented here the lesion was situated in the left frontal lobe including the inferior frontal lobe (Broca's area). For this reason we initially believed that the function of repetition in this patient may have been lateralized to the other hemisphere; however, the re-

sults of the Wada test indicated that this was not the case.

Some authors [17] have suggested that repetition in transcortical aphasia is carried out by either the non-dominant (usually the right) hemisphere, or by joint activity of non-involved left hemisphere structures and the intact right hemisphere [7]. Kezuka et al. [11] have pointed out that the literature contains case reports [2, 4, 7] which provide indirect support for the importance of the contralateral (spared) hemisphere in language repetition, and that despite significant damage to the central language zone the patients described in these papers exhibited a relative preservation of repetition. In fact, some cases of TMA have been noted to be associated with extensive reductions in blood flow and metabolism in the cerebral hemisphere including the perisylvian speech area. We have also reported a case of TMA following a brain tumour in the left thalamus [14]. In these cases reduced linguistic ability might have reflected compensation by the contralateral hemisphere. Bando et al. [3] performed the Wada test in a patient with transcortical sensory aphasia and suggested a fundamental role of the non-dominant (right) hemisphere in language repetition using this data. Berthier et al. [5] suggested that the spared contralateral hemisphere subserves residual repetition in some transcortical aphasia patients with a lesion within or outside the speech-dominant perisylvian area.

Because the subject described in this paper is not a straightforward right-hander, the question of language dominance arises. Studies by Alexander et al. [2] and Cappa et al. [8], which look at the phenomenon of crossed aphasia (aphasia occurring following a right hemisphere lesion in a right-hand person), and studies of aphasia in non-right handers provide insights into different patterns of cerebral lateralization. It is well-known that non-right handers are more likely to have a more bilateral

representation of language functions. In the case described here, however, the fact that the patient exhibited a severe aphasia in the presence of a left hemisphere lesion, and the fact that his residual reading abilities were transiently abolished during the Wada test suggest that his language functions were predominantly lateralized to the left hemisphere.

This case highlights the importance of investigating such lesions with the amyntal test. The result of the test in our patient supports the hypothesis that the left hemisphere is related to repetition rather than the right hemisphere. We cannot explain the preservation of repetition in this case, as this patient had not only isolation of perisylvian speech areas but also a lesion in the left inferior frontal gyrus.

References

1. Albert ML, Goodglass H, Helms NA, Rubens AB, Alexander MP (1981) Dysphasia without repetition disturbance: transcortical dysphasias. In: Arnold GE, Winckel F, Wyke BD (eds) *Clinical aspects of dysphasia. Disorders of human communication 2*. Springer, Berlin Heidelberg New York, pp 99–100
2. Alexander MP, Fischette MR, Fischer RS (1989) Crossed aphasias can be mirror image or anomalous. *Brain* 112: 953–973
3. Bando M, Ugawa Y, Sugishita M (1986) Mechanism of repetition in transcortical sensory aphasia. *J Neurol Neurosurg Psychiatry* 49:200–202
4. Basso A, Lecours AR, Moraschini S, Vanier M (1985) Anatomoclinical correlations of the aphasias as defined through computerized tomography: exceptions. *Brain Lang* 26:201–229
5. Berthier ML, Starkstein SE, Leiguarda R, Ruiz A, Mayberg HS, Wagner H, Price TR, Robinson RG (1991) Transcortical aphasia. *Brain* 114:1409–1427
6. Bougousslavsky J, Regli F, Assal G (1988) Acute transcortical mixed aphasia; a carotid occlusion syndrome with pial and watershed infarcts. *Brain* 111: 631–641
7. Brown JW (1975) The problem of repetition: a study of 'conduction' aphasia and the 'isolation' syndrome. *Cortex* 11:37–52
8. Cappa SF, Perani D, Bressi S, Paulesu E, Franceschi M, Fazio F (1993) Crossed aphasia: a PET follow up study of two cases. *J Neurol Neurosurg Psychiatry* 56:665–671
9. Geschwind N, Quadfasel FA, Segarra JM (1968) Isolation of the speech area. *Neuropsychologia* 6:327–340
10. Goldstein K (1948) *Language and language disturbances*. Grune & Stratton, New York
11. Kezuka M, Kawamura M, Yano Y (1993) Crossed aphasia with mixed transcortical aphasia. *Jpn J Neuropsychol* 9:216–220
12. Maeshima S, Komai N, Nakai M, Hyoutani G, Itakura T (1990) Transcortical mixed aphasia due to the subcortical hemorrhage in the left parietal lobe. *Higher Brain Function Research (Tokyo)* 10:205–209
13. Maeshima S, Dohi N, Kajiwaru T, Sano K, Kanno T (1990) A case of transcortical mixed aphasia after a neck clipping operation of aneurysm at bifurcation of the left internal carotid and anterior choroidal arteries. *Jpn J Stroke* 12:480–483
14. Maeshima S, Kuwata T, Uematsu Y, Itakura T, Komai N (1994) Transcortical mixed aphasia in a case of thalamic glioblastoma. *Aphasiology* 8:197–204
15. Maeshima S, Uematsu Y, Terada T, Nakai K, Itakura T, Komai N (1996) Transcortical mixed aphasia with left frontoparietal lesions. *Neuroradiology* 38:S78–S79
16. McFarling D, Rothi LJ, Heilman KM (1982) Transcortical aphasia from ischaemic infarcts of the thalamus: a report of two cases. *J Neurol Neurosurg Psychiatry* 45:107–112
17. Niessl von Mayendorf E (1911) *Die aphasischen Störungen und ihre Kortikale Lokalisation*. Barth, Leipzig
18. Nirayama conference (1975) *Standard language test of aphasia. Manual of directions*. Homeido, Tokyo
19. Rapcsak SZ, Kruupp LB, Rubens AB, Reim J (1990) Mixed transcortical aphasia without anatomic isolation of speech area. *Stroke* 21:953–956
20. Ross ED (1980) Left medial parietal lobe and receptive language functions: Mixed transcortical aphasia after left anterior cerebral artery infarction. *Neurology* 30:144–151

S. Maeshima (✉) · M. Nakagawa
T. Terada · K. Nakai · T. Itakura
N. Komai
Department of Neurological Surgery
Wakayama Medical College
7-27, Wakayama 640, Japan
Tel.: +81-734-268277
Fax: +81-734-335998

P. Roger
School of Communication
Sciences and Disorders
University of Sydney
Sydney, Australia