

'Fou rire prodromique' as the heralding symptom of lenticular infarction, caused by dissection of the internal carotid artery in a 12-year-old boy

GUY OSSEBY,¹ ERIC MANCEAU,¹ FRÉDÉRIC HUET,² FRANÇOIS BECKER,³
WONDER CHOUCANE,¹ CHRISTINE DURAND,⁴ MAURICE GIROUD¹

¹Clinic of Pediatric Neurology, ²Department of Pediatrics, ³Laboratory of Angiology, ⁴Department of Radiology, University Hospital, Dijon, France

A 12-year-old, right-handed boy experienced a pathological fit of laughter before a sudden right hemiplegia. Magnetic resonance imaging showed a left basal ganglia infarction, induced by a left internal carotid dissection. Arteriography revealed an underlying fibromuscular dysplasia. This case study demonstrates that cerebral artery dissection can occur in children and that a basal ganglia infarction may be preceded by pathological laughter called 'fou rire prodromique'. The clinical and anatomical relationship of this paroxysmal event are discussed.

Keywords: Laughter. Cerebral infarction. Carotid artery. Carotid dissection. Brain. MRI.

Introduction

The term 'fou rire prodromique' refers to pathological laughter preceding the onset of a stroke, and was first reported by Féré¹ in 1903.

We report the case of a boy who presented with a fit of laughter heralding a right hemiplegia induced by an ischaemic stroke. The underlying cause proved to be a dissection of the intracranial internal carotid artery.

Case report

A 12-year-old right-handed boy was admitted to the Department of Pediatrics 4 hours after the acute onset of a right hemiplegia with aphasia.

On admission we observed a conscious but drowsy boy, with a total right-sided hemiplegia involving the right side of the face, arm and leg

with a right extensor plantar reflex. A severe mixed aphasia was present. There was no left deviation of the head and eyes, nor right homonymous hemianopia or hemianaesthesia. The first computed tomography scan without contrast injection performed 1 hour after stroke onset in the emergency room showed a spontaneously hyperdense left middle cerebral artery and a slight hypodensity of the left lenticular nucleus. The cortical layer of the left insula was obscured. These findings were consistent with acute left sylvian ischaemia related to a left middle cerebral artery occlusion. Treatment with heparin was initiated.

Outcome was good with a decrease of the right hemiplegia 5 days later, but increase of a non-fluent aphasia 10 days later. One month later, speech was normal and only paresis of the right arm persisted.

From an aetiological point of view, we observed no cutaneous abnormalities resembling neurofibromatosis. Cervical Doppler ultrasound and arteriography of the two carotid and the two

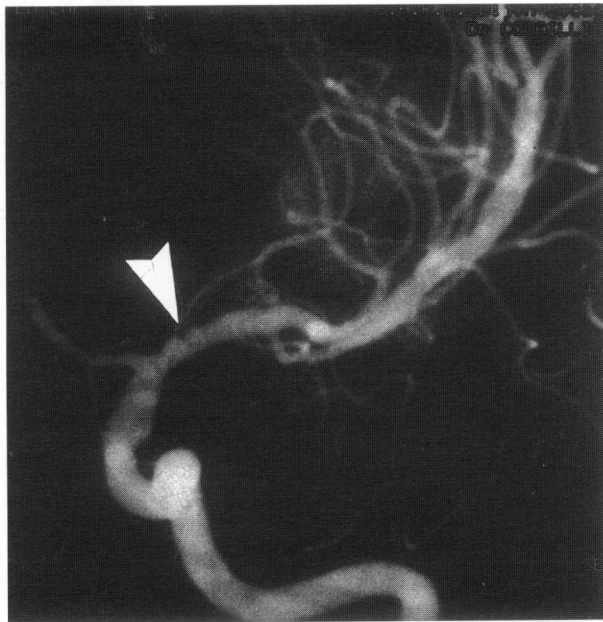

Fig. 1. Selective left internal carotid artery injection with digital subtraction, antero-posterior view: fibromuscular dysplasia and irregular narrowing (arrow).

vertebral arteries performed 48 hours later revealed an elongated irregular narrowed segment of the left sylvian artery with signs of fibromuscular dysplasia of both the left and right intracranial internal carotid arteries (Fig. 1). There were no sites of fibromuscular dysplasia in the renal or cervical arteries. Doppler ultrasound did not reveal any thick media, eliminating Takayasu disease, and an arteriogram did not reveal any cerebral collaterals of Moya-Moya type. Inflammatory tests were normal and anti-nuclear antibodies were negative.

Magnetic resonance imaging (MRI) performed 48 hours after the onset of stroke confirmed the infarction of the left lenticular nucleus and the left insula and some involvement of the left internal capsule without any lesion of the thalamus (Fig. 2). This was linked to a decrease of the N-acetyl-aspartate/choline ratio and a rise of the lactate/choline ratio inside the infarct on proton MR spectroscopy (Fig. 3). We did not perform any slices of the cervical internal carotid artery on MRI. Electrocardiogram, transoesophageal echocardiography, measure of glycaemia, lipid status, haemostasis, and homocystinaemia were normal.

When the boy was able to speak again, it was possible to confirm the features of the onset of stroke reported by his friends and the sports teacher. The boy was playing football at school when he was called to kick a penalty. While preparing his shot, he experienced a fit of pathological mixed laughter and crying. He did not

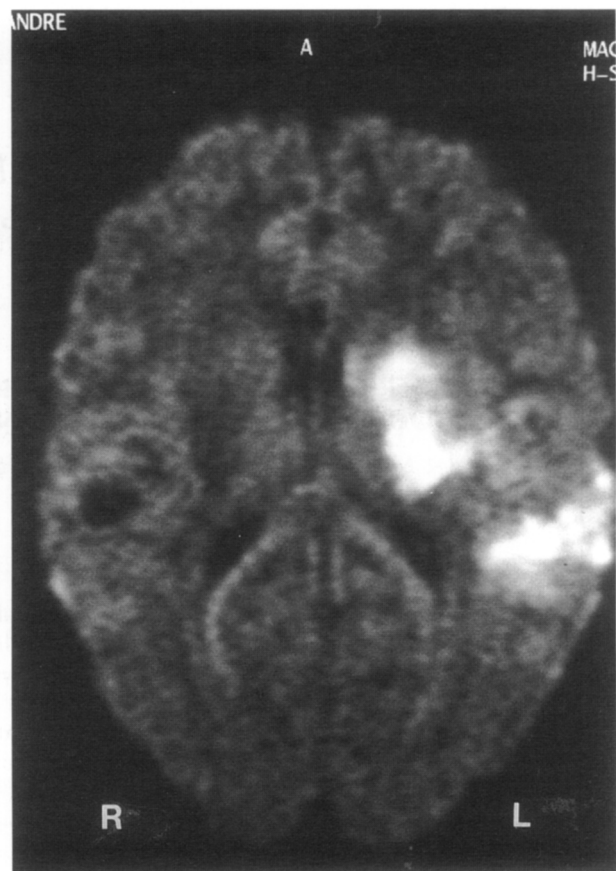


Fig. 2. Infarction of the left lenticular nucleus and the left insula on T₂-weighted MRI.

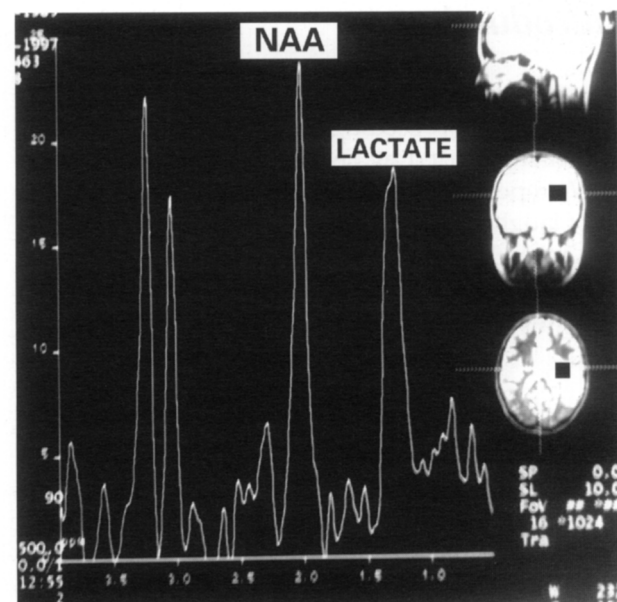


Fig. 3. Decrease of the ratio N-acetyl-aspartate/choline and rise of the ratio lactate/choline inside the infarction.

understand what was happening: it was an automatic and uncontrollable episode. He did not feel happy or sad; he felt very anxious and was unable to speak. This episode lasted nearly 1 minute. The

teacher asked him to go out and to sit on a chair. His friends accompanied him outside to the chair. He stopped abruptly and fell down from the chair to his right, became mute and developed a right hemiplegia. He did not lose consciousness and there was no abnormal movement.

Everybody confirmed that the emotional activity arose without any reason and the right-sided hemiplegia occurred when the laughter and the crying had stopped. An electroencephalogram performed 12 hours after onset of the stroke showed delta waves in the left temporal area, without any epileptic activity. Following the episode there was good recovery of speech. A right-sided monoplegia involving the arm, and occasional spasmodic laughter persisted.

Discussion

This report is important for two reasons. First, our patient is one of the youngest patients observed in our population-based Stroke Registry of Dijon² with a carotid dissection related to a fibromuscular dysplasia, although this is one of the most common causes of dissection of the cerebral arteries in an adult.³ The renal arteries were not affected. The main complication is the recurrence of the dissection.⁴ In childhood, carotid dissection with fibromuscular dysplasia is less common than Marfan disease, alpha-1-anti-trypsin deficiency and Moya-Moya disease.⁵ We eliminated Moya-Moya disease, a connective tissue disorder, a Takayasu disease and a clinical diagnosis of neurofibromatosis type I.

Second, the 'spasmodic laughter' is a rare pre-stroke symptom described in the stroke literature. The fit of spasmodic laughter was pathologic because it was automatic, inappropriate, continuous, not connected to mood or emotion⁶ and outside any humorous context. Recent advances in the localization and neural mechanisms of laughter suggest a lesion either in the frontal area, limbic system or supra-bulbar area.⁷

We found the first description of prodromal laughing in the article by Féré.¹ We do not think our patient had a paradoxical embolus during a period of increased pressure such as during a Valsalva manoeuvre because electrocardiogram and echocardiogram were normal.

We think this is the first case of 'fou rire prodromique' heralding an ischaemic stroke in childhood. Only three cases have been reported in the literature.⁸⁻¹⁰ Some other cases have been reported with bleeding⁶ and tumour.¹¹ Three

locations have been identified: the brain stem,⁸ the capsular-thalamic^{9,12} and the lenticular nuclei.¹²

The anatomy and the pathways of normal laughter remain unclear. Wilson,¹³ in 1924, assumed the existence of a 'faciorespiratory centre' localized in the brain stem under the control of the corticonuclear pathways and the basal ganglia pathways. According to this hypothesis a pathological laughter requires lesions to be bilateral. Nevertheless it has been reported^{6,12,13} that a unilateral lesion of the corticospinal motor trace can disturb this system and can induce the loss of the tonic control of laughter⁶ without mood involvement. In our patient the corticonuclear pathways were affected unilaterally. Of 30 cases verified at autopsy, Poeck⁶ drew three main conclusions:

1. single cortical lesion cannot induce pathological laughter;
2. the anterior arm and the genu of the internal capsule are always damaged;
3. a unilateral lesion of the corticonuclear fibres can produce a pathological laughter.

In the work of Kim,¹⁴ the lesion was located in the lenticulocapsular area in eight of 13 cases.

The 'fou rire prodromique' has always been described as a transient symptom which lasts anything from a few seconds, as was the case in our patient, to as long as 30 minutes.⁸ It can also be repeated several times before the onset of the hemiplegia, as in the third case of Féré.¹ There may be an interval of a few minutes between the laughter and the hemiplegia.⁹ In contrast, the 'fou rire prodromique' may be followed immediately by the hemiplegia, as in our case and the case reported by Carel *et al.*¹²

This 'fou rire prodromique' is quite different from the laughing seizure in which consciousness is affected and there may be some automatic movements of the lips and pharyngeal muscles, with spikes on electroencephalogram and a lesion within the hypothalamic area on MRI.

We conclude that 'fou rire prodromique' is a form of transient ischaemic attack that may be induced by a unilateral lesion within the internal capsule or lentiform nucleus.

References

- 1 Féré MC. Le fou rire prodromique. *Rev Neurol (Paris)* 1903; **11**: 353-358.
- 2 Giroud M, Lemesle M, Madinier G, Manceau E, Osseby G, Dumas R. Stroke in children under 16

- years of age. Clinical and etiological difference with adults. *Acta Neurol Scand* 1997; **96**: 401–406.
- 3 Mokri B, Sundt T M Jr, Houser O W, Piepgras D G. Spontaneous dissection of the cervical internal carotid artery. *Ann Neurol* 1986; **19**: 126–138.
 - 4 Schnievink N I, Mokri B, Whisnaut J P. Internal carotid artery dissection in a community. Rochester, Minnesota, 1987–1992. *Stroke* 1993; **24**: 1678–1680.
 - 5 Manceau E, Giroud M, Dumas R. Moya–Moya disease in children. A review of the clinical and radiological features and current treatment. *Child's Nerv Syst* 1997; **13**: 595–600.
 - 6 Poeck K. Pathological laughter and crying. In: Vinken P J, Bruyn G W, Klawans H V eds. *Handbook of Clinical Neurology* Vol 1 (45). Amsterdam, Netherlands: Elsevier, 1985: 219–225.
 - 7 Fried I, Wilson C L, MacDonald K A, Behnke E J. Electric current stimulates laughter. *Nature* 1998; **391**: 650–658.
 - 8 Wali G M. 'Fou rire prodromique' heralding a brainstem stroke. *J Neurol Neurosurg Psychiatr* 1993; **56**: 209–210.
 - 9 Ceccaldi M, Milandre L. A transient fit of laughter as the inaugural symptom of capsular-thalamic infarction. *Neurology* 1994; **44**: 1762–1765.
 - 10 Martin J P. Fits of laughter (sham mirth) in organic cerebral disease. *Brain* 1950; **70**: 453–464.
 - 11 Ceccaldi M, Donnet A, Grisoli F, Poncet M. Fou rire prodromique et tumeur prérolandique. *Rev Neurol (Paris)* 1995; **151**: 206–208.
 - 12 Carel C, Albucher J F, Manelfe C, Guiraud-Chaumeil B, Chollet F. Fou rire prodromique heralding a left internal carotid artery occlusion. *Stroke* 1997; **28**: 2081–2083.
 - 13 Wilson S A K. Some problems in neurology, II: pathologic laughing and crying. *J Neurol Neurosurg Psychiatr* 1994; **16**: 299–333.
 - 14 Kim J S. Pathologic laughter after unilateral stroke. *J Neurol Sci* 1997; **148**: 121–125.