

Multiple Cerebral Infarctions From Nonbacterial Thrombotic Endocarditis Mimicking Cerebral Vasculitis

ROBERT VASSALLO, MD; ELLEN D. REMSTEIN, MD; JOSEPH E. PARISI, MD; JOHN HUSTON III, MD; AND ROBERT D. BROWN, JR, MD

Primary vasculitis of the central nervous system (PVCNS) is an uncommon disorder that can present with a variety of symptoms, making diagnosis and management difficult. We describe a case of cerebral infarction that occurred from nonbacterial thrombotic endocarditis (NBTE) and presented with clinical and radiologic imaging features that suggested PVCNS. The patient was a 58-year-old woman with left hemiparesis, aphasia, and episodic confusion. Magnetic resonance imaging of the brain demonstrated multifocal lesions consistent with infarction involving both cerebral hemispheres, and cerebral angiography showed changes consistent with vasculitis. Although brain biopsy findings were normal, the patient was treated for presumed vasculitis with cyclophosphamide and prednisone. Four months later respiratory failure secondary to polymicrobial pneumonia and adult respiratory distress syndrome developed, and she died. Autopsy revealed multiple infarcts in the heart, lungs, right kidney, spleen,

and brain. Multiple thrombotic platelet-fibrin vegetations consistent with NBTE were found on all cardiac valves. Examination of the brain revealed no evidence of active or healed vasculitis. Cerebral angiography may show findings that suggest vasculitis, but it is not diagnostic, as several other conditions may cause similar changes. Nonbacterial thrombotic endocarditis may cause multiple cerebral infarctions and can be difficult to distinguish from vasculitis, as specific diagnostic tests for PVCNS are lacking.

Mayo Clin Proc. 1999;74:798-802

CNS = central nervous system; CSF = cerebrospinal fluid; CT = computed tomographic; MRI = magnetic resonance imaging; NBTE = nonbacterial thrombotic endocarditis; PVCNS = primary vasculitis of the central nervous system; TEE = transesophageal echocardiography; TTE = transthoracic echocardiography

Nonbacterial thrombotic endocarditis (NBTE) is an unusual cause of systemic embolization that is most frequently associated with malignancy and hypercoagulable states. Diagnosis is difficult and is most commonly made at postmortem examination.

Described herein is a case of cerebral and systemic embolization that probably resulted from NBTE that was not detected on extensive clinical evaluation but was found at autopsy. There was no associated malignancy, hypercoagulable state, or evidence of disseminated intravascular coagulation.

REPORT OF A CASE

A 58-year-old woman presented in October 1996 with left hemiparesis, aphasia, and episodic confusion. Magnetic

resonance imaging (MRI) of the brain demonstrated multifocal lesions with abnormally increased T₂ signal involving the left basal ganglia as well as the white matter and cortex in both cerebral hemispheres consistent with cerebral infarction (Figure 1). Some of the cortical lesions demonstrated a gyriform pattern. A few of the areas of T₂ signal abnormality were enhanced after administration of gadolinium contrast. Cerebral angiography showed focal areas of narrowing involving both large- and small-caliber vessels, and the findings were believed to be consistent with primary vasculitis of the central nervous system (PVCNS) (Figure 2). Examination of the cerebrospinal fluid (CSF) yielded normal findings except for a slightly elevated protein count (57 mg/dL), and there were no oligoclonal bands. Stereotactic brain biopsy specimen showed 2 subacute infarcts without evidence of vasculitis. An MRI of the head with gadolinium performed for stereotactic guidance during cerebral biopsy (3 days after the first MRI) revealed multiple foci of T₂ signal abnormality, as noted in the previous MRI, and also new lesions involving both cerebral hemispheres and both occipital lobes (Figure 3), indicating progression of the disease process. Transthoracic and transesophageal echocardiography (TTE and TEE) revealed normal valves without evidence of intracardiac thrombi.

From the Thoracic Diseases Research Unit, Division of Pulmonary and Critical Care Medicine and Internal Medicine (R.V.), Division of Anatomic Pathology (E.D.R., J.E.P.), Department of Radiology (J.H.), and Department of Neurology (R.D.B.), Mayo Clinic Rochester, Rochester, Minn.

This study was supported in part by National Institutes of Health grant NS 06663.

Address reprint requests and correspondence to Robert D. Brown, Jr, MD, Department of Neurology, Mayo Clinic Rochester, 200 First St SW, Rochester, MN 55905.

Mayo Clin Proc. 1999;74:798-802

798

© 1999 Mayo Foundation for Medical Education and Research

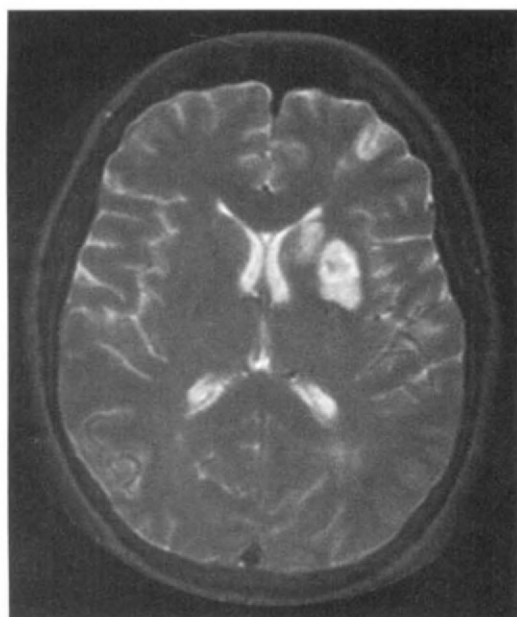


Figure 1. Magnetic resonance image of the brain demonstrates abnormally increased T₂ signal involving the left caudate nucleus and basal ganglia.

Serologic studies, including antinuclear antibodies, lupus anticoagulant, anticardiolipin antibodies, rheumatoid factor, cryoglobulins, hepatitis serologies, and extractable nuclear antigens, were negative. A comprehensive hemostatic survey including procoagulant factor levels, proteins C and S, antithrombin III, and factor V Leiden levels showed results within normal limits.

Based on the clinical picture of multiple neurologic deficits, the MRI findings, and the cerebral angiographic findings, the patient was treated for presumed PVCNS with cyclophosphamide, 2 mg/kg per day, and prednisone, 1 mg/kg per day.

In April 1997, she was admitted to our hospital because of shortness of breath and cough, which progressed in spite of treatment with broad-spectrum antibiotics. She had not been receiving prophylaxis for *Pneumocystis carinii* pneumonia because of an allergy to sulfa drugs. The prednisone dose had been tapered to 10 mg/d.

Her medical history included treated essential hypertension, left carotid endarterectomy in June 1996 for amaurosis fugax, mild hyperlipidemia, steroid-induced diabetes, and fibromyalgia. The medications included cyclophosphamide, prednisone, ceftriaxone, and fluconazole.

Physical examination revealed bilateral coarse crackles in the lower lung fields, a soft systolic murmur at the base, and an unremarkable abdominal examination. Neurologic examination revealed mild left-sided weakness but was otherwise unremarkable.

On the day after admission, bronchoscopy was performed, and *P carinii* organisms were seen on bronchoalveolar lavage. Following bronchoscopy she required intubation and mechanical ventilation because of worsening respiratory failure. Intravenous treatment with pentamidine was started because of her allergy to sulfonamides. In spite of maximal ventilatory support, treatment with pentamidine, and broad-spectrum antibiotic coverage, her condition progressively deteriorated with worsening respiratory failure. A computed tomographic (CT) scan of the head, which was performed because of excessive drowsiness and altered mentation, demonstrated unchanged, multiple, small cortical and subcortical infarcts. Echocardiography was not performed during the hospital stay because the CT scan showed no evidence of recurrent cerebral infarction and also because a cardiac source of emboli was not suspected on clinical grounds.

Two weeks after admission, air was noticed under the diaphragm on chest x-ray examination, and further evaluation showed diverticulitis with diverticular abscess and bowel perforation. At this point the family wished to withdraw support, and the patient died.

AUTOPSY FINDINGS

At autopsy, examination of the heart demonstrated platelet-fibrin vegetations extensively involving the aortic, mitral, pulmonary, and tricuspid valves (Figure 4). The subjacent valvular tissue showed minimal reactive changes only. Special stains (Gram, Grocott methenamine silver) used on sections of the vegetations from all 4 valves were negative

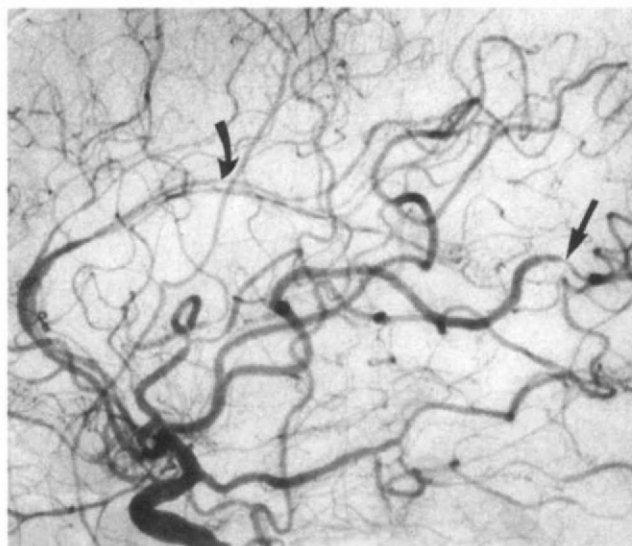


Figure 2. Cerebral angiogram demonstrates diffuse changes involving both large-caliber (arrow) and small-caliber (curved arrow) vessels consistent with vasculitis.

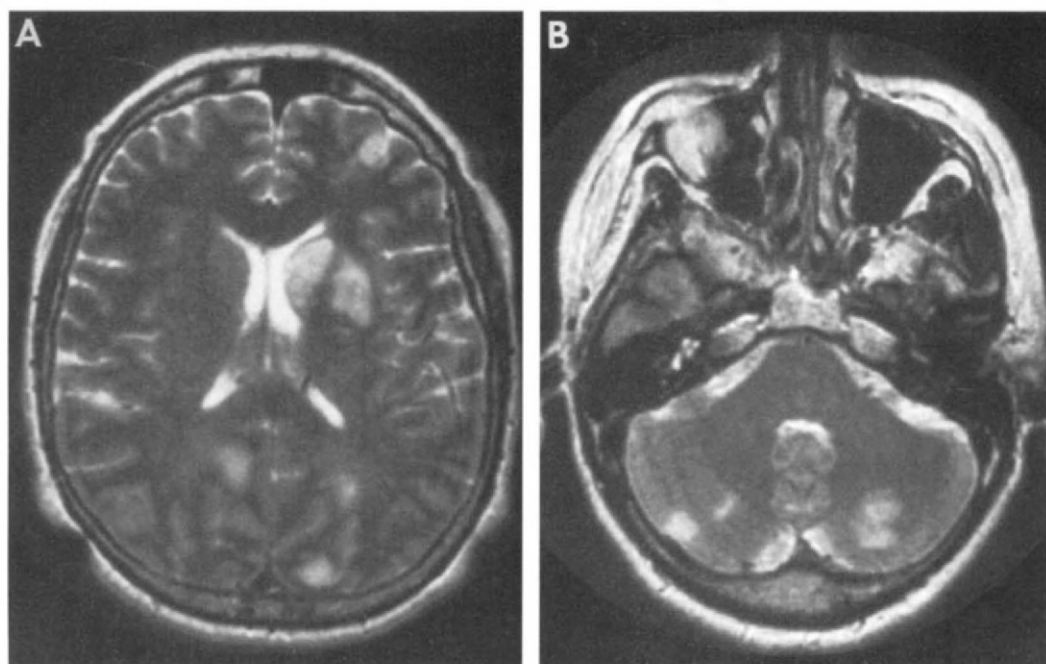


Figure 3. Repeat magnetic resonance image (MRI) of the head performed 3 days after the first MRI showed significant progression with multiple new areas of T₂ signal abnormality in both cerebral hemispheres (A) and both occipital lobes (B).

for bacterial or fungal organisms, supporting the diagnosis of NBTE. Embolic infarcts of variable age with associated platelet-fibrin thrombi, presumably originating from the platelet-fibrin vegetations found on the cardiac valves, were identified involving multiple organs, including heart, lungs, right kidney, spleen, and brain. The heart showed acute infarcts of the posteroseptal left ventricle and posterior papillary muscle, the lungs contained multiple peripheral acute and chronic infarcts involving all lobes except the right middle lobe, the right kidney contained multiple

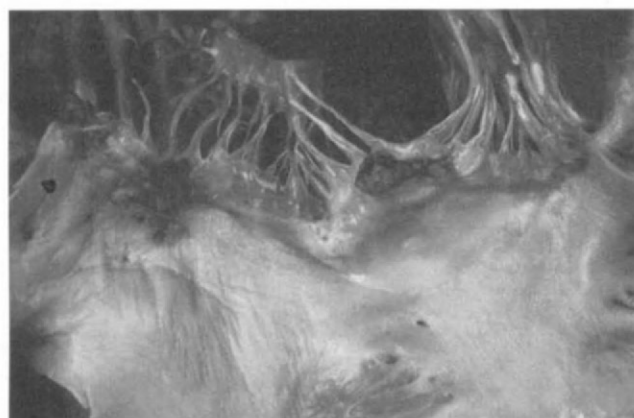

Figure 4. Extensive involvement of the cardiac valves with platelet-fibrin vegetations was seen at autopsy.

acute and chronic infarcts, and multiple chronic infarcts were found in the spleen. Parenchymal vessels showed no evidence of acute or healed vasculitis, and further examination of mesenteric vessels using an elastic (Verhoeff-Van Gieson) stain also showed no acute or healed vasculitis.

Examination of the brain revealed multiple acute, subacute, and chronic ischemic infarcts involving white and gray matter, also associated with platelet-fibrin thrombi. These infarcts involved multiple sites, including bilateral superior and middle frontal, superior temporal, inferior temporal, and superior occipital gyri, the left putamen, the right dentate nucleus and deep cerebellar white matter, and the left peripheral cerebellar hemisphere. The findings of the previous left frontal brain biopsy in October 1996 also included multiple subacute infarcts, but no definite platelet-fibrin thrombi were identified. The bilateral temporal arteries, the left middle cerebral artery, and the parenchymal vessels from the autopsy brain specimen, as well as the parenchymal vessels from the October 1996 brain biopsy, were completely free of acute or healed vasculitis. In addition, transmission electron microscopy performed on the brain tissue from both the autopsy specimen and the prior left frontal biopsy showed that the cerebral vessels contained focal deposits of phagocytosed lipid and cell membrane debris (nonspecific findings), but cerebral autosomal dominant arteriopathy with subcortical infarcts and leukoencephalopathy was not evident. Generalized, mild (grade

1 of 4) atherosclerosis was present in the right and left carotid arteries and cranial vessels from the autopsy brain.

The patient ultimately died of respiratory failure, with evidence of diffuse alveolar damage (clinically adult respiratory distress syndrome) and polymicrobial pneumonia at autopsy. The diffuse alveolar damage was manifest by marked diffuse hyaline membrane formation. Grocott methenamine silver staining of sections from the right lower lobe and the left lung showed rare organisms consistent with *P. carinii*, cytomegalovirus in situ hybridization demonstrated occasional cytomegalovirus inclusions in the left lung, and postmortem lung cultures were positive for cytomegalovirus and coagulase-negative staphylococcus, providing evidence of polymicrobial pneumonia. In addition, sigmoid diverticulitis and focal acute fibrinous peritonitis with rare cytomegalovirus inclusions on in situ hybridization were identified. No occult malignancy was found.

COMMENT

This unusual case illustrates a number of important insights into the diagnosis of PVCNS and NBTE.

An uncommon condition, PVCNS is difficult to diagnose because of protean clinical manifestations and a lack of specific noninvasive markers. Analysis of CSF in PVCNS may show nonspecific abnormalities such as an increase in protein or pleocytosis. In some studies, CSF examination yielded normal findings in approximately 50% of cases of PVCNS diagnosed without a brain biopsy.^{1,2} However, in a larger study involving 70 cases of histopathologically proven vasculitis, the CSF was abnormal in 90% of cases,³ suggesting that normal CSF findings argue against but are not inconsistent with a diagnosis of vasculitis.

The MRI is abnormal in most patients with PVCNS.^{4,5} Common findings include supratentorial infarcts involving both gray and white matter, which are often bilateral in distribution. Harris et al⁵ described 70 patients who underwent MRI examination of the head as part of a work-up to exclude vasculitis. Of 7 patients eventually diagnosed as having vasculitis, Harris et al found abnormalities on all 7 MRI examinations. The diagnosis of PVCNS was established by angiography in 5 of these patients and by cerebral biopsy in the other 2 patients. Nineteen patients had completely normal MRI examinations, and of these, none was diagnosed as having vasculitis after the complete evaluation. They concluded that a normal MRI examination of the head makes the diagnosis of intracranial vasculitis unlikely. However, none of the patients with normal MRI examinations underwent cerebral biopsy, and no data in the literature compare the sensitivity of MRI with brain biopsy. Although the sensitivity of MRI in the diagnosis of PVCNS

appears to be high, it lacks specificity in that there is no characteristic pattern of vasculitis on MRI, and the test is poor in differentiating vasculitis from other conditions.⁶

The most important tests in establishing the diagnosis of PVCNS have traditionally been cerebral angiography and cerebral biopsy (the "gold standard"). However, the sensitivity, specificity, and predictive value of these tests are not known with certainty. In up to 38% of histologically confirmed cases of PVCNS, cerebral angiography is normal,³ and conversely, even the classic picture of alternating stenosis and dilatation ("beading") on cerebral angiography is not specific for CNS vasculitis and may be seen in other conditions,⁷ as this case illustrates. The findings may be seen with a variety of neoplastic, degenerative, infectious, and vasospastic vascular disorders.⁷ In addition, recanalized emboli can also cause similar findings. The cerebral angiogram in our patient was interpreted by 2 expert neuroradiologists in a tertiary care center with considerable experience in vasculitis. Although not pathognomonic of vasculitis, the findings on angiography were believed to be consistent with this diagnosis. One can speculate that the changes on angiography may have been caused by recanalized emboli that originated from the vegetations on the cardiac valves.

Brain biopsy is considered the gold standard for the diagnosis of PVCNS, but because of the patchy nature of the disease, the result may be a false negative. Calabrese et al³ reported that of 43 pre-mortem brain biopsies, 32 were interpreted as positive and 11 were nondiagnostic or negative. The latter 11 cases were later confirmed at autopsy to be vasculitis, giving biopsy a 74.4% sensitivity in the diagnosis of vasculitis. In addition, biopsy is essential to rule out other disorders, such as neoplastic conditions (especially lymphoma), chronic infections, and inflammatory processes that may mimic vasculitis clinically. Although the sensitivity of brain biopsy is only moderate, a suggestive biopsy markedly raises the threshold for treatment with aggressive immunosuppressive therapy. If the biopsy is negative or nondiagnostic, a presumptive diagnosis of cerebral vasculitis may be considered on the basis of an appropriate clinical picture together with consistent MRI and angiographic findings, after other diagnoses have been excluded. Because untreated cerebral vasculitis can lead to devastating and permanent neurologic deficit, the clinician may be compelled to treat in these circumstances.

The optimal treatment for PVCNS has not been established by means of prospective randomized trials but is rather based on anecdotal experience and case reports. Treatment usually includes prednisone at a dose of 1 mg/kg per day, sometimes in conjunction with cyclophosphamide at 2 mg/kg per day.⁸ It is important to remember that the

treatment of the condition itself is associated with considerable morbidity and mortality, as seen in our patient who died of infection caused by opportunistic pathogens.

An unusual cause of systemic embolization, NBTE occurs most frequently in patients with malignancy and sepsis.⁹ It is difficult to diagnose clinically as there are no pathognomonic signs or symptoms, and even cardiac murmurs may be absent.¹⁰ Echocardiography is at present the most useful diagnostic modality available for the diagnosis of NBTE,⁹⁻¹² even though there are no data on the sensitivity of echocardiography in the diagnosis of NBTE before death. Lopez et al¹³ reported 6 cases of NBTE diagnosed at necropsy; all 6 patients had had TTE performed within 45 days of death. Valvular vegetations were demonstrated in 4 of 6 patients with pathologic evidence of NBTE. All left-sided valvular vegetations larger than 4 mm were accurately detected in this study. However, TEE is more effective in the detection of valvular vegetations in infective endocarditis,¹⁴ and it may be more sensitive than TTE in the diagnosis of NBTE. There is only 1 case report in the English-language literature in which the diagnosis of NBTE was established by TEE, which showed vegetations on all 4 cardiac valves, while TTE showed only a questionable mitral valve vegetation.¹² If the clinical suspicion of NBTE is high and TTE is normal, it is reasonable to perform TEE to achieve optimal visualization of the cardiac valves, although TEE may still give a false-negative result.

Multiple brain infarcts have been described in the setting of NBTE.¹⁵ In this case we speculate that NBTE was the original cause of the patient's multiple cerebral infarcts although we cannot implicate a specific cause for the NBTE. The NBTE probably preceded the systemic infections that led to respiratory failure and eventually death in this patient. The TEE and TTE performed at the time of diagnosis of the "cerebral vasculitis" did not show vegetations, but unfortunately these tests were not repeated prior to her death 4 months later because there was no suspicion of recurrent embolic events.

CONCLUSION

Primary vasculitis of the CNS is difficult to diagnose with noninvasive studies, and even aggressive evaluation with brain biopsy may not yield diagnostic findings. Accurate diagnosis requires careful clinical, radiologic, and pathologic correlation. This case represents the first report we are aware of multiple emboli to the brain likely arising from occult nonbacterial vegetations on the cardiac valves

that resulted in angiographic findings suggestive of cerebral vasculitis. Cerebral angiography must be interpreted with caution as a number of conditions can cause changes on angiography that mimic vasculitis. Cerebral biopsy is the preferred technique to establish the diagnosis of PVCNS, but it is not always abnormal in PVCNS. Nonbacterial thrombotic endocarditis should be considered in the evaluation of patients with multiple cerebral infarcts and an abnormal arteriogram, particularly when the cortical/meningeal biopsy findings are normal.

REFERENCES

- Scolding NJ, Jayne DRW, Zajicek JP, Meyer PAR, Wraight EP, Lockwood CM. Cerebral vasculitis—recognition, diagnosis and management. *QJM*. 1997;90:61-73.
- Stone JH, Pomper MG, Roubenoff R, Miller TJ, Hellmann DB. Sensitivities of noninvasive tests for central nervous system vasculitis: a comparison of lumbar puncture, computed tomography, and magnetic resonance imaging. *J Rheumatol*. 1994; 21:1277-1282.
- Calabrese LH, Furlan AJ, Gragg LA, Ropos TJ. Primary angiitis of the central nervous system: diagnostic criteria and clinical approach. *Cleve Clin J Med*. 1992;59:293-306.
- Greenan TJ, Grossman RI, Goldberg HI. Cerebral vasculitis: MR imaging and angiographic correlation. *Radiology*. 1992;182:65-72.
- Harris KG, Tran DD, Sickels WJ, Cornell SH, Yuh WTC. Diagnosing intracranial vasculitis: the roles of MR and angiography. *AJNR Am J Neuroradiol*. 1994;15:317-330.
- Miller DH, Ormerod IEC, Gibson A, du Boulay EPGH, Rudge P, McDonald WI. MR brain scanning in patients with vasculitis: differentiation from multiple sclerosis. *Neuroradiology*. 1987;29: 226-231.
- Ferris EJ, Levine HL. Cerebral arteritis: classification. *Radiology*. 1973;109:327-341.
- Cohen BA, Biller J. Hemorrhagic stroke due to cerebral vasculitis and the role of immunosuppressive therapy. *Neurosurg Clin N Am*. 1992;3:611-624.
- Joffe II, Jacobs LE, Owen AN, Ioli A, Kotler MN. Noninfective valvular masses: review of the literature with emphasis on imaging techniques and management. *Am Heart J*. 1996;131:1175-1183.
- Lopez JA, Ross RS, Fishbein MC, Siegel RJ. Nonbacterial thrombotic endocarditis: a review. *Am Heart J*. 1987;113:773-784.
- Edoute Y, Haim N, Rinkevich D, Brenner B, Reisner SA. Cardiac valvular vegetations in cancer patients: a prospective echocardiographic study of 200 patients. *Am J Med*. 1997;102:252-258.
- Blanchard DG, Ross RS, Dittich HC. Nonbacterial thrombotic endocarditis: assessment by transesophageal echocardiography. *Chest*. 1992;102:954-956.
- Lopez JA, Fishbein MC, Siegel RJ. Echocardiographic features of nonbacterial thrombotic endocarditis. *Am J Cardiol*. 1987;59:478-480.
- Heinle SK, Kisslo J. The clinical utility of transesophageal echocardiography in patients with left-sided infective endocarditis. *Am J Card Imaging*. 1995;9:199-202.
- Fujishima S, Okada Y, Irie K, et al. Multiple brain infarction and hemorrhage by nonbacterial thrombotic endocarditis in occult lung cancer—a case report. *Angiology*. 1994;45:161-166.