

Thromboembolism Originated from the Pulmonary Artery Stump after Fontan Operation

Cerebral thromboembolism is a rare but serious complication after Fontan operation. This is the report of a patient who underwent a successful intracardiac thrombectomy for cerebral thromboembolism after Fontan operation. A 2-year-old girl was referred to us with the diagnosis of tricuspid atresia without pulmonary stenosis, normally related great arteries, and a ventricular septal defect. Although she underwent a successful Fontan operation and division of the main pulmonary artery, she developed a cerebrovascular event at 3 weeks after the operation. Echocardiography demonstrated a large thrombus within the residue of the main pulmonary artery, and suggested that the thrombus had migrated into the systemic circulation by way of the ventricular septal defect. At 2 weeks after the cerebrovascular event, she underwent thrombectomy and excision of the pulmonary valve. Although she has developed slight left-sided hemiparesis, she is leading a normal life at 1 year after the operation. (JJTCVS 1999; 47: 346–349)

Index words: Fontan operation, complication, thromboembolism, cerebral infarction

Masaaki Koide, MD, Masakazu Abe, MD, Koujirou Kodera, MD, Kyoichi Sudo, MD, Masashi Seguchi, MD, and Akira Sakai, MD.

Patients after Fontan operation are at risk for various complications such as arrhythmia, pleural effusion, protein-losing enteropathy, and thromboembolism. Among these, intracardiac thrombus is a serious complication which can be fatal. Although a variety of locations have been reported as nidi of thrombus formation, those within the pulmonary artery stump are rare. Recently, we experienced a case which developed a large thrombus within the pulmonary artery stump and cerebral thromboembolism, after a successful Fontan operation. Transthoracic echocardiography revealed a large thrombus within the remnant main pulmonary

artery, and a computed tomographic (CT) scan of the brain disclosed a fresh cerebral infarction in the area from the right posterior limb of the internal capsule to the corona radiata. At 2 weeks after the cerebrovascular event, the patient underwent a successful intracardiac thrombectomy.

Case

A female infant was referred to us because of cyanosis and failure to thrive. Echocardiography at the time of admission revealed tricuspid atresia, ventricular septal defect, and normally related great arteries with increased pulmonary blood flow. Balloon atrial septostomy and pulmonary artery banding was performed when she was 2 months of age. At the age of 2.2 years, she underwent Fontan operation. With the aid of cardiopulmonary bypass, the pulmonary trunk was divided at the site of the banding, and its proximal end was oversewn leaving the pulmonary valve leaflets intact. Under aortic crossclamping, the right atrium was obliquely di-

From the Department of Cardiovascular Surgery and Department of Pediatrics, Seirei Hamamatsu General Hospital, Hamamatsu, Shizuoka, Japan.

Received for publication April 13, 1998.

Accepted for publication December 11, 1998.

Address for reprint requests: Masaaki Koide, MD, Department of Cardiovascular Surgery and Department of Pediatrics, Seirei Hamamatsu General Hospital, 2-12-12 Sumiyoshi, Hamamatsu, Shizuoka 430-8558, Japan.

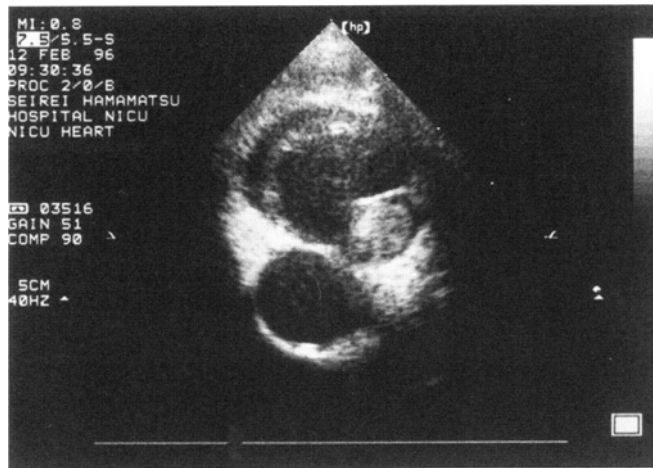

Fig. 1. Two dimensional echocardiography in short axis view showed a large thrombus within the remnant main pulmonary artery. The thrombus appeared to float within the stump.

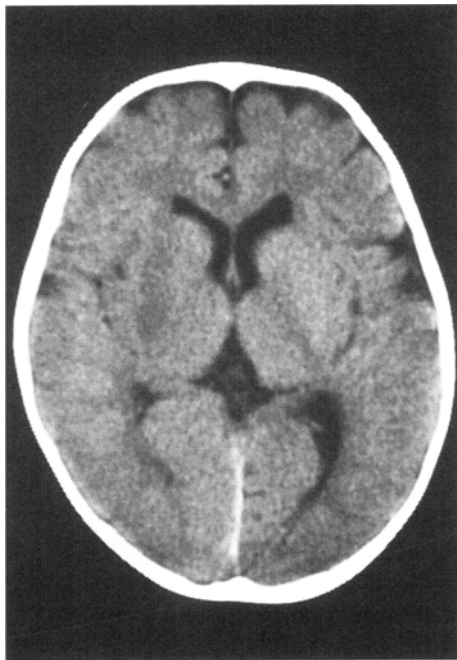


Fig. 2. CT scan of the brain showing a fresh cerebral infarction in the area from the right posterior limb of the internal capsule to the corona radiata.

vided using a bovine pericardial patch reinforced by a Dacron patch. The right atrial appendage was directly anastomosed to the divided end of the pulmonary artery. The patient returned to the recovery room uneventfully and was extubated in the next

morning. Her postoperative course had been smooth and uneventful until she developed a cerebrovascular event and left-sided hemiplegia on the 22nd postoperative day. Transthoracic echocardiography revealed a large thrombus within the remnant divided main pulmonary artery (Fig. 1). Instantaneously performed CT of the brain demonstrated a low density area in the area from the right posterior limb of the internal capsule to the corona radiata which suggested a thromboembolism in the middle cerebral artery (Fig. 2). Accordingly, migration of thrombus was strongly suspected from the pulmonary artery stump into the systemic circulation through the ventricular septal defect. Thrombolytic therapy was not done to avoid fragmentation of the thrombus and ensuing embolic episode. Since anticoagulation therapy with heparin was ineffective and could not arrest growth of the thrombus, she underwent the second surgery at 2 weeks after the cerebrovascular event. With the aid of a cardiopulmonary bypass, the proximal end of the pulmonary artery stump was opened so as to remove the thrombus and also the pulmonary valve leaflets. The arterial stump was then oversewn in a manner so as to reduce the volume of the residual main pulmonary artery. The postoperative course was uneventful, and the patient showed good recovery from hemiplegia. Anticoagulant therapy with Warfarin was commenced on the third postopera-

tive day. She was discharged at 3 weeks after the second surgery and is leading a normal life with slight left hemiparesis.

Discussion

Fontan operation is considered to be definitive palliation for virtually all forms of univentricular congenital heart disease. However, various complications such as pleural effusion, protein-losing enteropathy, dysarrhythmia, and thrombosis are widely recognized sequelae after Fontan operation. Among these, thromboembolism causes serious problems which can result in a life-threatening complication. Although several cases of thrombosis in the right-side of the heart have been reported since 1978, cerebral thromboembolism is a rare complication.¹ In a report from the Boston Children's Hospital, du Plessis and colleagues reported the incidence of stroke was 2.6% (17 of 645 patients) in patients who underwent Fontan operation.² Three of 17 patients were found to have had thrombus located in the pulmonary artery stump. It was of note that Rosenthal et al. reported three cases of thrombosis in the pulmonary artery stump after its distal ligation but without development of a cerebrovascular event.³ Whichever surgical method was selected for the management of the main pulmonary artery, the space sandwiched between the patent pulmonary valve and the divided or ligated proximal end of the pulmonary artery created a cul-de-sac which, as was reported by Rosenthal et al., produced a potential nidus for static blood flow that was predisposed to thrombus formation. Poor hemodynamics such as dysarrhythmia, low cardiac output, or ventricular dysfunction are risk factors for thrombosis after Fontan operation, which was not the case in the present case. Abnormal coagulability after Fontan operation has been pointed out by Cromme-Dijkhuis et al.⁴ Since no such coagulation factor was examined in this case after Fontan operation, it is unclear whether coagulopathy played a role in this particular case. Although the role of prophylactic anticoagulant therapy after Fontan operation has been poorly defined,² routine anticoagulant therapy may have to be considered.⁵ Despite the use of aspirin (5 mg/kg/day) as routine anticoagulant therapy, intracardiac thrombus devel-

oped early and continued to grow even after the commencement of continuous infusion therapy with Heparin. More intensive and earlier anticoagulant therapy perhaps using Warfarin may have been needed in this particular case. In this situation of Fontan circulation, surgical manipulation and the subsequent changes in the cardiac structure may cause another condition prone to develop intracardiac thrombus. Simple division of the pulmonary arterial trunk, as in our case, created a cul-de-sac between the pulmonary valve and the divided end, and the blood flow became stagnant. These conditions are known to be closely related to thrombus formation. Since thrombus formation may progress even in asymptomatic patients,³ postoperative examinations with either transthoracic or esophageal echocardiography should be routinely performed with focus on the pulmonary artery stump for those whose pulmonary valves were left intact. As a surgical prophylaxis for the thrombosis in the pulmonary artery stump as seen in this case, excision or oversewing of the pulmonary valve leaflets may be the best resolution.⁶ Also the volume of the pulmonary artery stump should be made sufficiently small so as to minimize the volume of static flow which gives rise to the thrombus formation. However, such optional management of the pulmonary artery should be carefully avoided in patients with both univentricular physiology and ventriculo-arterial discordance. These patients are known to be at risk to develop various forms of subaortic stenosis after Fontan operation, and thus remain as candidates for a Damus-Kay-Stansel procedure, for which the pulmonary valve should be kept intact.

Conclusion

A 2-year-old girl developed cerebral thromboembolism originated from pulmonary artery stump after Fontan operation, and was successfully treated by intracardiac thrombectomy and postoperative anticoagulant therapy.

REFERENCES

1. Rosenthal DN, Friedman AH, Kleinman CS, Kopf GS, Rosenfeld LE, Hellenbrand WE. Thromboembolic complications after Fontan operations. *Circu-*

- lation 1995; 92 (Suppl II): II-287-93.
2. du Plessis AJ, Chang AC, Wessel DL, Lock JE, Wernovsky G, Newburger JW, Mayer JE. Cerebrovascular accidents following the Fontan operation. *Pediatr Neurol* 1995; 12: 230-6.
 3. Rosenthal DN, Bulbul ZR, Friedman AH, Hellenbrand WE, Kleinman CS. Thrombosis of the pulmonary artery stump after distal ligation. *J Thorac Cardiovasc Surg* 1995; 110: 1563-5.
 4. Cromme-Dijkhuis AH, Henkens CMA, Bijleveld CMA, Hillege HL, Bom VJJ, van der Meer J. Coagulation factor abnormalities as possible thrombotic risk factors after Fontan operations. *Lancet* 1990; 336: 1087-90.
 5. Hedrick M, Elkins RC, Knott-Craig CJ, Razoook JD. Successful thrombectomy for thrombosis of the right side of the heart after the Fontan operation. *J Thorac Cardiovasc Surg* 1993; 105: 297-301.
 6. Jonas RA. Intracardiac thrombus after the Fontan procedure (Editorial). *J Thorac Cardiovasc Surg* 1995; 110: 1502-3.