

## Sneddon's Syndrome and Antithrombin III

Ertugrul Bolayir, Hulusi Keçeci, Melih Akyol\*,  
Ayşenur Taş and Murat Polat\*

### Abstract

Sneddon's syndrome, an uncommon disorder, is characterized by multiple cerebrovascular accidents along with ideopathic livedo reticularis. In this article, two cases who had increased amounts of antithrombin III and were diagnosed with Sneddon's syndrome are presented.

**Key words:** Sneddon's syndrome; livedo reticularis; cerebrovascular accident; antithrombin III

### Case Report

#### Case 1:

A 30-year-old woman who had a history of epileptic seizures was admitted to the Department of Neurology with complaints of dysarthria and hemiparesis. There was no family history. Neurologic examination revealed left hemiparesis, dysarthria, and central facial paresia. Dermatologic examination revealed reticular erythema on the extremities (Fig. 1). Routine hematologic and urine analyses were in their normal ranges. Echocardiography, electrocardiography, cerebral angiography, carotid ultrasonography, and posteroanterior chest X-ray were normal. Computed tomography (CT) demonstrated multiple infarcts (Fig. 2). Anticardiolipin antibodies, protein C, and protein S were in their normal ranges. Antithrombin III (ATIII) was 45 mg/dl (normal range: 22–39 mg/dl).

#### Case 2:

A 31-year-old woman who had epileptic seizures and unconsciousness was admitted to the emergency service. Neurologic examination revealed unconsciousness and right hemiplegia. Dermatologic examination revealed reticular

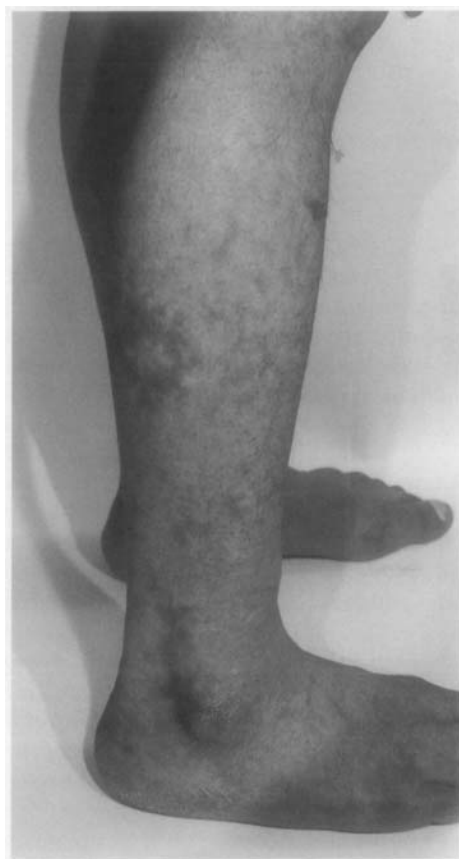

Fig. 1. Reticular erythema on the lower extremities.

Received February 17, 1999; accepted for publication April 21, 1999.

Department of Neurology and \*Dermatology, Medical Faculty, Cumhuriyet University, Sivas, Turkey.

Reprint requests to: Ertugrul Bolayir, Department of Neurology, Medical Faculty, Cumhuriyet University, 58140-Sivas, Turkey.

erythema on the upper extremities (Fig. 3). Routine hematologic and urine analyses were in that normal ranges. Echocardiography, electrocardiography, cerebral angiography, carotid ul-

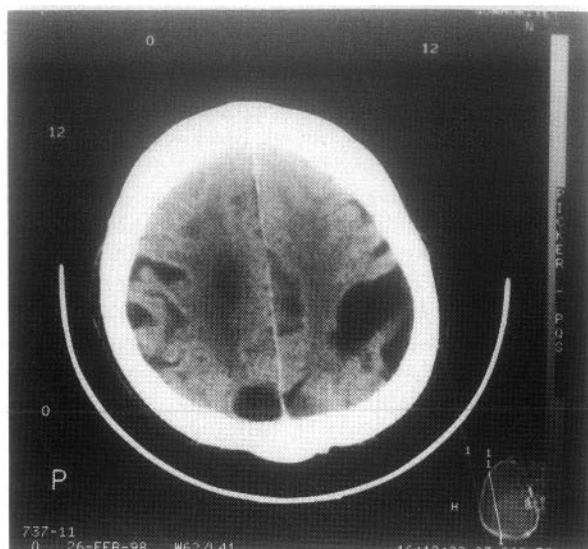


Fig. 2. CT showing multiple infarct areas

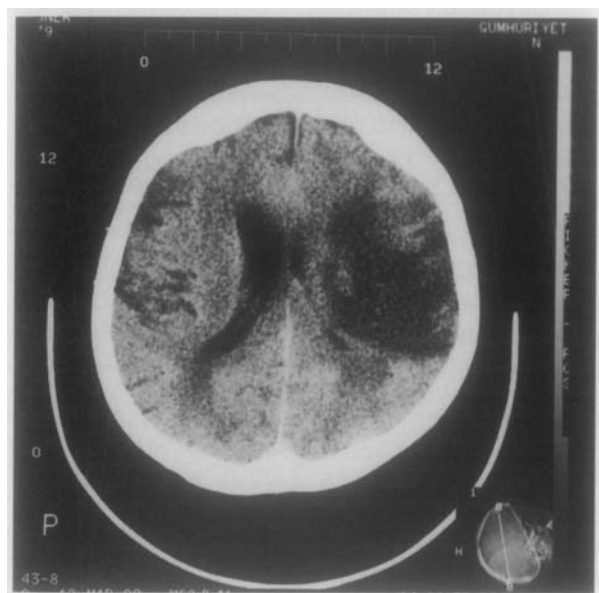


Fig. 4. CT showing infarct in the left hemisphere

trasonography, and posteroanterior chest X-ray graphy were normal. CT demonstrated acute infarcts of the areas supplied by the middle cerebral arteries (Fig. 4). Anticardiolipin antibodies, protein C, and protein S were in their normal ranges. ATIII was 60 mg/dl (normal range: 22–39 mg/dl).

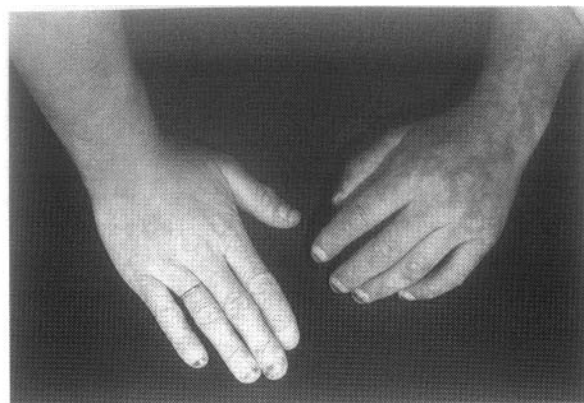

Fig. 3. Reticular erythema on the upper extremities

### Discussion

Sneddon's syndrome, characterized by idiopathic livedo reticularis and cerebrovascular diseases, is a rare disorder. There may be both arterial and venous obliteration and visual disorders, headache, and ischemic encephalopathy associated with this disorder (1, 2). Sneddon's syndrome usually occurs in association with antiphospholipid antibodies (2, 3).

In most cases, early symptoms occur in the second and third decades. The incidence of Sneddon's syndrome is greater in females than males. Before the cerebrovascular problems arise variable forms of epilepsy can be seen (4, 5). In our cases, the early symptoms were epileptic seizures.

The cerebrovascular pathology includes transient ischemic attacks and strokes. Cerebral infarcts usually are found in the areas supplied by the middle diameter arteries. Hypertension and memory impairment can also be associated with Sneddon's syndrome (6–8). CT reveals cortical atrophy in variable degrees and isolated or multiple infarcts (4). In our cases, CT demonstrated multiple infarct areas.

Antiphospholipid antibodies may play a role in the pathogenesis of Sneddon's syndrome (3). However, some cases may not have antiphospholipid antibodies (9). These antibodies are also found in about

1–2% of the normal population, although they are found in about 30% of the patients with Sneddon's syndrome. Aznar et al. detected antiphospholipid antibodies only in one of seven cases. Therefore, in addition to antiphospholipid antibodies, other factors must be involved in the pathogenesis of Sneddon's syndrome (10).

We found that our cases have high levels of ATIII, a plasma protein that inactivates serine proteases by an irreversible time-dependent reaction, which is often designated as a progressive inhibitor. It has been purified extensively and has been separated from other progressive antithrombins. ATIII is a plasma glycoprotein that increases its ability to inhibit thrombin and other activated clotting factors. In several variant forms of the disorder, plasma levels of ATIII antigen are normal, but those of functional ATIII are depressed (11–14). Akiguchi and co-workers (15) reported a family with antiphospholipid antibody syndrome as well as Binswanger's disease with increased coagulation activity. In one patient from this family, abnormally high levels of thrombin-antithrombin complex and fibrinogen were detected. Moreover, Akiguchi and co-workers (16) reported another family in which several members had a history of subcortical vascular dementia and coagulation abnormalities. One of the members of this family had Sneddon's syndrome and abnormally high thrombin-antithrombin complexes. The patient improved both clinically and biologically when treated with antithrombin. A qualitative deficiency of ATIII may explain why ATIII levels are high in our cases.

We think that a qualitative deficiency of ATIII will prove to play a role in the pathogenesis of Sneddon's syndrome.

### References

- 1) Bradley W, Daraffe R, Fenichel G, Marsden D: Neurological complications of systemic diseases, in Aminoff MJ (ed): *Neurology in Clinical Practice*, 2nd ed, Butterworth-Heinemann, New York, 1996, pp 920–921.
- 2) Dowd PM: Reactions to cold, in Champion RH, Burton JL, Burns DA, Breatnach SM (eds): *Textbook of Dermatology*, 6th ed, Blackwell-Science, Oxford, 1998, pp 957–972.
- 3) Moral A, Vidal JM, Moreau I et al: Sneddon's syndrome with antiphospholipid antibodies and arteriopathy, *Stroke*, **22**: 1327–1328, 1991.
- 4) Bland JR: Sneddon's syndrome: CT, arteriography and MRI, *J Comp Ass Tomogr*, **13**: 119–122, 1989.
- 5) Deshamps P, Leroy D, Mandara JC et al: Livedo reticularis and nodules due to cholesterol embolism, *Br J Dermatol*, **93**: 97, 1977.
- 6) Kumral K, Selçuki D, Yayicioğlu S: Sneddon sendromu, *Nörol Bil D*, **7**: 1–2, 1990.
- 7) Marsh WCH, Muehleman R: Generalized racemose livedo with cerebrovascular lesions: An occlusive arteriopathy due to proliferation and migration of medial smooth muscle, *Br J Dermatol*, **112**: 703–708, 1985.
- 8) Weisenborn K, Lubach D, Schwabe C, Becker H: Sneddon's syndrome. Clinical course and outcome, *J Neurol*, **236**: 34–37, 1989.
- 9) Stochhammer G, Folber SR, Aichner FT: Sneddon's syndrome antiphospholipid antibodies: Classification of controversy by skin biopsy, *Stroke*, **23**, 1182, 1992.
- 10) Aznar J, Villa P, Yaya R, et al: Sneddon's syndrome and antiphospholipid antibodies, *Thromb Res*, **69**: 525–530, 1993.
- 11) Hathaway WE: Clinical aspects of antithrombin III deficiency, *Semin Hematol*, **28**: 19–23, 1991.
- 12) Graham JA, Daly HM, Carson PJ: Antithrombin III deficiency and cerebrovascular accident in young adults, *J Clin Pathol*, **45**: 921–922, 1992.
- 13) Bithell TC: Blood coagulation, in Lee GR, Bithell TC, Foerster J, Athens JW, Lukens JN (eds): *Wintrobe's Clinical Hematology*, 9 ed, Lea-Febiger, Philadelphia, 1993, pp 566–615.
- 14) Bithell TC: Thrombosis and antithrombotic therapy, in Lee GR, Bithell TC, Foerster J, Athens JW, Lukens JN (eds): *Wintrobe's Clinical Hematology*, 9th ed, Lea-Febiger, Philadelphia, 1993, pp 1515–1551.
- 15) Akiguchi I, Tomimoto H, Kinoshita M, et al: Effects of antithrombin on Binswanger's disease with antiphospholipid antibody syndrome, *Neurology*, **52**: 921–922, 1999.
- 16) Akiguchi I, Murase N, Sato H, Kaji R, Tomimoto H, Kanda M: Familial Binswanger-type encephalopathy with Sneddon's syndrome (Abstract), *Cerebrovasc Dis*, **6** (suppl 2): 68, 1996.