

# Stereotactic Radiosurgery and Particulate Embolization for Cavernous Sinus Dural Arteriovenous Fistulae

Bruce E. Pollock, M.D., Douglas A. Nichols, M.D.,  
James A. Garrity, M.D., Deborah A. Gorman, R.N.,  
Scott L. Stafford, M.D.

Departments of Neurological Surgery (BEP, DAG), Diagnostic Radiology (DAN), Ophthalmology (JAG), and Radiation Oncology (SLS),  
Mayo Clinic and Foundation, Rochester, Minnesota

**OBJECTIVE:** To evaluate the safety and efficacy of stereotactic radiosurgery, either with or without transarterial embolization, in the treatment of patients with dural arteriovenous fistulae (DAVFs) of the cavernous sinus.

**METHODS:** We reviewed the findings, from a prospectively established database, for 20 patients with cavernous sinus DAVFs who were treated with either radiosurgery alone ( $n = 7$ ) or radiosurgery and transarterial embolization ( $n = 13$ ) in a 7-year period. The median follow-up period after radiosurgery was 36 months (range, 4–59 mo).

**RESULTS:** Nineteen of 20 patients (95%) experienced improvement of their clinical symptoms. Fourteen of 15 patients (93%) experienced either total ( $n = 13$ ) or nearly total ( $n = 1$ ) obliteration of their DAVFs, as documented by angiography performed a median of 12 months after radiosurgery. No patient experienced a recurrence of symptoms after angiography showed DAVF obliteration. Two patients developed new neurological deficits after embolization procedures. One patient exhibited temporary aphasia secondary to a venous infarction; another patient exhibited permanent VIth cranial nerve weakness related to acute cavernous sinus thrombosis. Two patients experienced recurrent symptoms and underwent repeat transarterial embolization at 7 and 12 months; both patients achieved clinical and angiographic cures (5 and 10 mo later, respectively). One patient experienced recurrent visual symptoms and underwent transvenous embolization 4 months after radiosurgery.

**CONCLUSION:** Staged radiosurgery and transarterial embolization provided both rapid symptom relief and long-term cures for patients with cavernous sinus DAVFs. Radiosurgery alone was effective for patients with DAVFs whose arterial supply was not accessible via a transarterial approach, although the time course of symptom improvement was longer, compared with patients who also underwent embolization.

(Neurosurgery 45:459–467, 1999)

**Key words:** Cavernous sinus, Dural arteriovenous fistula, Embolization, Gamma knife, Stereotactic radiosurgery

Cavernous sinus dural arteriovenous fistulae (DAVFs) are abnormal arteriovenous communications between branches of the internal carotid artery (ICA) and external carotid artery (ECA) and the cavernous sinus. Barrow et al. (3) classified carotid artery-cavernous sinus fistulae into four angiographic types, on the basis of their arterial supply. Type A fistulae are direct shunts between the ICA and the cavernous sinus and do not represent true DAVFs. Type A fistulae are high-flow lesions that usually develop after trauma and often require urgent treatment because of progressive visual or neurological deterioration. Types B, C, and D represent shunts between dural branches of the ICA (Type

B), dural branches of the ECA (Type C), or dural branches of both the ICA and ECA (Type D) and the cavernous sinus. These fistulae arise spontaneously and generally affect middle-aged women. Cavernous sinus DAVFs occur less frequently than transverse/sigmoid sinus DAVFs (1, 4, 6) and have a low risk of hemorrhage, unless cortical venous drainage is present (1). Patients with cavernous sinus DAVFs may develop an alarming symptom complex consisting of proptosis, chemosis, extraocular muscle palsies, and, sometimes, threatened visual loss resulting from either increased intraocular pressure or reduced ocular perfusion pressure. For these patients, rapid curative treatment is necessary to prevent vi-



sual deterioration, in addition to cosmetic and other symptomatic considerations.

Management of cavernous sinus DAVFs has included observation (3), intermittent manual compression of the ICA (16), microsurgery (9, 13, 23, 29), transarterial or transvenous embolization (3, 10, 12, 14, 16, 21, 25–27, 30, 31), and stereotactic radiosurgery (2, 6, 11, 19). Endovascular techniques have become the most common treatment for patients with symptomatic cavernous sinus DAVFs that do not spontaneously resolve, because of the high rates of cure after embolization (20). However, embolization of cavernous sinus DAVFs has been reported to cause at least temporary ophthalmoplegia in 8 to 50% of patients (16, 21, 25, 31), and recanalization of embolized DAVFs is well documented (7, 12, 16). Direct surgical resection has been advocated for patients who experience failure of endovascular attempts at obliteration (9, 29), but such surgery is difficult and is associated with high rates of postoperative cranial nerve deficits. Also, major morbidity related to occlusion of the ICA has been reported after direct surgical treatment of cavernous sinus DAVFs (9).

We previously reported our experience with 29 patients, using a staged approach to intracranial DAVF treatment that involved radiosurgery followed by planned transarterial embolization (19). This staging allows complete radiosurgical coverage of the involved dural sinus, for progressive long-term obliteration of all abnormal fistulous connections. Subsequent embolization provides rapid symptom relief and/or elimination of cortical venous drainage. This report outlines the results of this staged approach for 20 patients with symptomatic Type B, C, or D cavernous sinus DAVFs who were treated at our center during a 7-year period.

## PATIENTS AND METHODS

### Patient population

Between March 1992 and October 1997, 20 patients with cavernous sinus DAVFs underwent radiosurgery, using a Leksell Gamma Unit (Elekta Instruments, Atlanta, GA), at the Mayo Clinic (Rochester, MN). All clinical, neuroimaging, and follow-up information for the patients was entered into a prospectively maintained computer database. Our patients included 17 women and 3 men. The clinical and angiographic characteristics of the patients are presented in Table 1. The median patient age was 67 years (range, 34–80 yr). All patients exhibited symptoms resulting from the fistulae and had experienced failure of conservative management. No patient had experienced intracranial hemorrhage before the procedure. For four patients, cortical venous drainage was noted during preoperative angiography.

### Patient evaluation

All patients underwent a thorough ophthalmological examination, by a neuro-ophthalmologist, before radiosurgery. Objective tests of visual acuity and visual fields were performed to provide baseline data for comparison during follow-up monitoring. Because of the complexity of the DAVF cases referred to our institution, the available imaging results were

**TABLE 1. Clinical and Angiographic Characteristics of 20 Patients with Cavernous Sinus Dural Arteriovenous Fistulae before Radiosurgery**

Characteristic	No. of Patients (%)	
	Radiosurgery Alone (n = 7)	Radiosurgery and Embolization (n = 13)
Chemosis/proptosis	6 (86)	12 (92)
Diplopia	4 (57)	9 (69)
Decreased vision	2 (29)	6 (46)
Tinnitus	2 (29)	5 (38)
Headache/eye pain	2 (29)	4 (31)
Prior embolization	0 (0)	2 (15)
Type of DAVF <sup>a</sup> (Barrow) <sup>b</sup>		
B	1 (14)	0 (0)
C	1 (14)	2 (15)
D	5 (71)	11 (85)
Type of DAVF (Cognard) <sup>c</sup>		
I	1 (14)	0 (0)
IIa	6 (86)	9 (69)
IIa + b	0 (0)	3 (23) <sup>d</sup>
III	0 (0)	1 (8)

<sup>a</sup> DAVF, dural arteriovenous fistula.

<sup>b</sup> According to the classification system of Barrow et al. (3).

<sup>c</sup> According to the classification system of Cognard et al. (7).

<sup>d</sup> One patient underwent preradiosurgical embolization, with elimination of cortical venous drainage, before radiosurgery.

reviewed by an interventional neuroradiologist before management decisions were made. Bilateral selective ICA, ECA, and vertebral artery angiographic series were essential for diagnosis and identification of all arterial supplies to the fistulae. Some patients required superselective branch-vessel angiography to precisely establish the exact site of a fistula. In fact, for several patients we thought it was necessary to repeat angiography at our institution before decisions could be made regarding management. The final decision to proceed with radiosurgery and transarterial embolization was made only after thorough analysis of the clinical and imaging findings in each case.

### Radiosurgical dosimetry

Conventional biplanar angiography, using high-resolution magnification and photographic subtraction techniques, was performed in all cases. Selective ICA, ECA, and/or vertebral artery injections were performed as required to demonstrate the target for dose-planning. Superselective angiography of ECA branches was also performed when necessary, in unusual cases. The Leksell Gamma Plan System (used after early 1993) permits scanning of the angiographic films, together with stereotactic magnetic resonance imaging results (via direct network data transfer), into the dose-planning computer. The ability to integrate the stereotactic angiographic and magnetic resonance imaging results allows conformal dose-planning for the fistula and maintains the ability to observe the adjacent temporal lobe, pituitary gland, and optic appa-



ratus. The goal was to include the entire area of the involved cavernous sinus in the radiosurgical dose plan.

A median of three isocenters of radiation (range, 1–10 isocenters) were used to cover the DAVFs of the patients in this series. All patients were treated at the 50% or greater isodose line. Because the locations of the DAVFs were usually in the inferior or posterior part of the cavernous sinus, the radiation dose to the adjacent optic apparatus was less than 10 Gy in all cases (Fig. 1). The median prescription isodose volume was 2.8 cm<sup>3</sup> (range, 0.7–7.5 cm<sup>3</sup>). The median marginal radiation dose was 20 Gy (range, 18–20 Gy). The median maximal radiation dose was 40 Gy (range, 22.2–40 Gy).

### Transarterial embolization technique

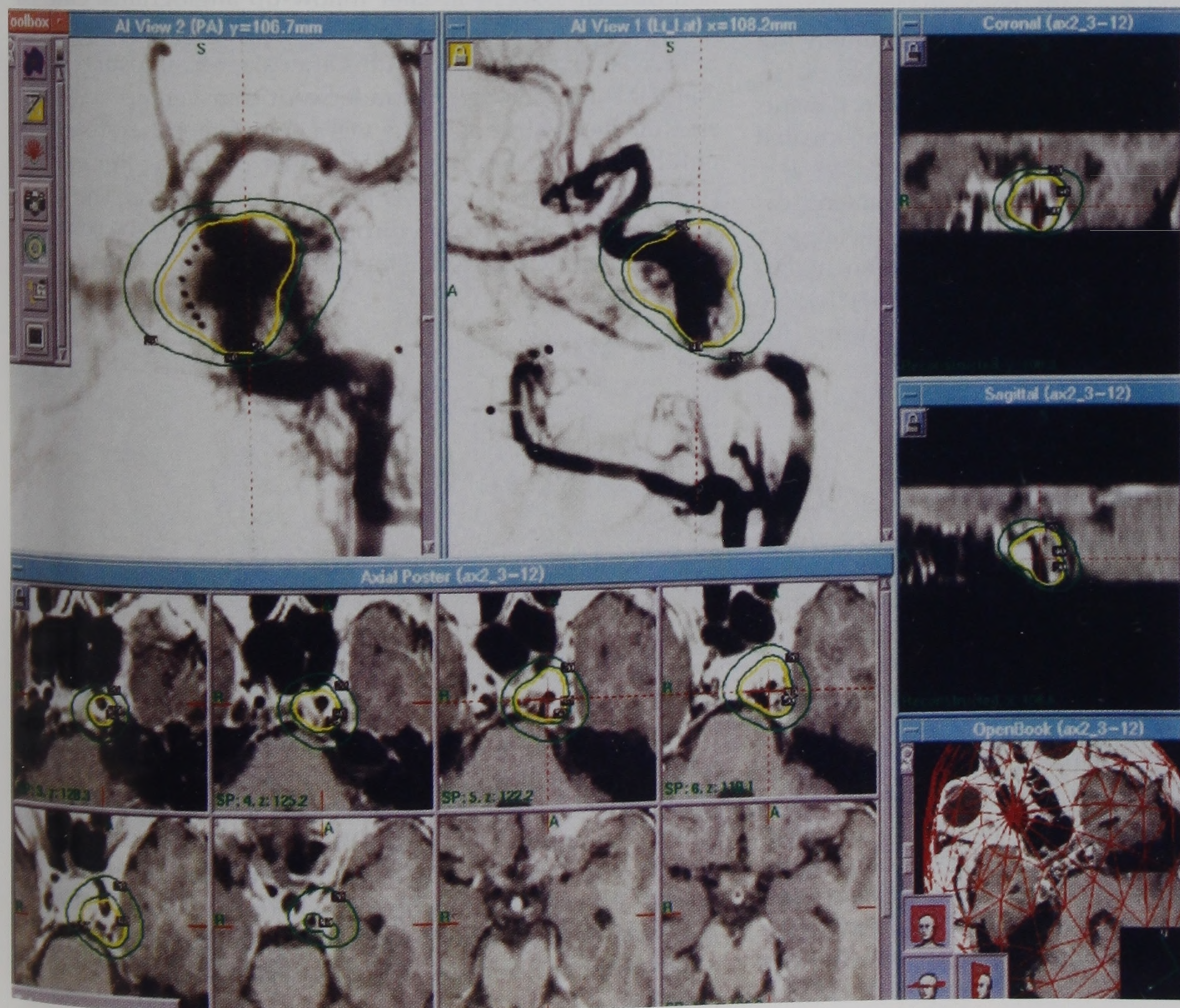
Because radiosurgery involves a latency interval before obliteration of the fistula, the aim of combining radiosurgery with transarterial embolization was to provide rapid symptom relief and to eliminate cortical venous drainage, if present. Two patients underwent embolization procedures before radiosurgery. One patient remained symptomatic despite both transvenous and transarterial embolizations and was referred for further evaluation and care. She was treated with radiosurgery and repeat transarterial embolization at our center. Another patient underwent preradiosurgical embolization. This patient had a bilateral cavernous sinus DAVF

with such extensive cortical venous drainage that adequate angiographic imaging of the fistula itself was impossible without reduction of the blood flow through the fistula.

Particulate embolization was used as a planned adjunct after radiosurgery for 12 patients, in one (n = 10) or two (n = 2) sessions. Seven patients underwent radiosurgery alone because transarterial embolization was thought not to be technically possible with acceptable risk. Polyvinyl alcohol particles were the primary embolization material used in the embolization procedures. In some cases, other materials (silk sutures, Gelfoam, or fibered microcoils) were used in conjunction with the polyvinyl alcohol particles. Cortical venous drainage was eliminated in all four patients with this angiographic finding, using either pre- or postradiosurgical embolization procedures. Most patients were monitored in the hospital overnight after their radiosurgical and embolization procedures.

### Follow-up monitoring

Yearly clinical and angiographic assessments were attempted for all patients. Routine follow-up magnetic resonance imaging evaluations were not performed unless the patients developed symptoms thought to be related to radiation injury of the adjacent brainstem or temporal lobe, because magnetic resonance imaging results are mostly noninformative for this patient group. Additional treatment was consid-



**FIGURE 1.** Radiosurgical dose plan for a 51-year-old woman with progressive eye pain and diplopia related to a left cavernous sinus DAVF. Five 8-mm isocenters of radiation were used to treat the fistula (volume, 2.3 cm<sup>3</sup>) with a marginal dose of 20 Gy (maximal dose, 40 Gy). Note that the optic nerves and chiasm were outside the 20% isodose line and thus received less than 8 Gy of radiation.



ered if the patients remained symptomatic after the initial procedures. Clinical follow-up data were available for all patients for a median of 36 months after radiosurgery (range, 4–59 mo).

### Statistical analyses

Nonparametric variables were analyzed using Fisher's exact test; parametric variables were compared using Student's *t* test.

## RESULTS

### Patient symptoms

Ocular symptoms related to venous congestion (chemosis or proptosis) improved significantly ( $n = 2$ ) or resolved completely ( $n = 15$ ) for 17 of 18 affected patients (94%). Seven of eight patients (88%) with decreased visual fields or acuity regained normal vision. One patient experienced decreased vision 11 months after the procedure but was found to have choroidal detachment with secondary-angle glaucoma. Ten of 13 patients (77%) with preoperative diplopia experienced either normalization ( $n = 8$ ) or significant improvements ( $n = 2$ ). Three patients with preoperative VIth cranial nerve weakness exhibited no change in diplopia during follow-up monitoring. Tinnitus ( $n = 7$ ) and eye pain/headache ( $n = 6$ ) were resolved for all patients. Overall, improvement of some symptoms was experienced by 19 of 20 patients (95%). No difference in symptom improvement was noted between patients treated using radiosurgery alone (100%) and patients treated using radiosurgery and transarterial embolization (92%) ( $P = 1.0$ ). However, the median time to patient improvement was shorter for the patients who underwent both radiosurgery and embolization, compared with the patients who underwent only radiosurgery (2 wk versus 6 mo,  $P < 0.001$ ). No patient experienced intracranial hemorrhage during the follow-up period.

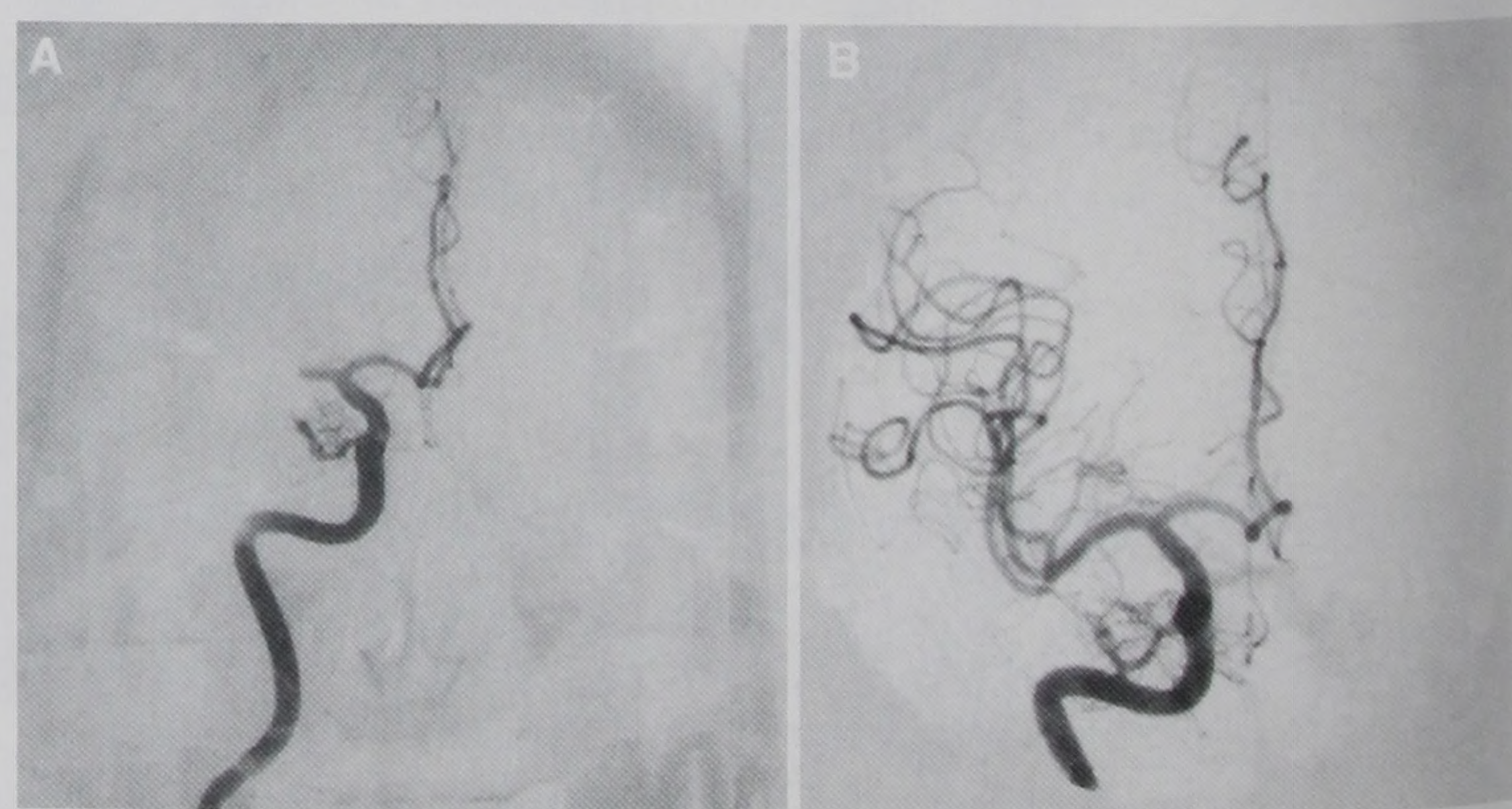
### Neuroimaging outcomes

Thirteen of 15 patients (87%) experienced complete obliteration of their DAVFs, as demonstrated in follow-up angiograms obtained a median of 12 months after radiosurgery (range, 4–33 mo). One patient with a Type D fistula (3) experienced complete resolution of her chemosis/proptosis and exhibited improved vision 13 months after radiosurgery. Angiography performed at that time showed that the ECA supply was gone but a small ICA supply to the fistula persisted (more than 95% obliteration). The patient remains asymptomatic 33 months after radiosurgery and refuses to undergo further angiography. One patient exhibited recurrent visual symptoms 4 months after staged radiosurgery and embolization. Angiography performed at the time of transvenous embolization revealed recanalization of her DAVF. The remaining five patients have refused follow-up angiography but are clinically cured.

### Complications and additional treatments

Complications related to either stereotactic angiography ( $n = 1$ ) or the embolization procedures ( $n = 2$ ) occurred in three patients (15%). One patient became lethargic, with left hemiparesis, during stereotactic angiography; embolic occlusion of the M1 segment of the right middle cerebral artery was discovered (Fig. 2). The patient underwent immediate intra-arterial thrombolytic therapy, and the neurological status of the patient returned to baseline. Radiosurgery and two embolization procedures were completed in the next several days. Fourteen months later, the chemosis and diplopia of the patient have resolved and she remains neurologically intact. One patient developed new VIth cranial nerve paresis during preradiosurgical embolization, as a result of acute cavernous sinus thrombosis. Fifty-four months later, her diplopia has improved but she still requires prism glasses. One patient developed a small venous infarction during postradiosurgical embolization, resulting in transient aphasia, which improved in the months after the procedure.

Three patients who initially showed improvement after radiosurgery and transarterial embolization underwent additional embolization procedures because of recurrent symptoms. Two patients underwent repeat transarterial particulate embolization procedures at our center, 7 and 12 months after the initial procedures. The symptoms of both patients again improved, and the patients demonstrated complete obliteration of their DAVFs in later follow-up angiograms. One patient exhibited increasing intraocular pressure and worsening of her vision, as noted 4 months after staged radiosurgery and embolization. The patient underwent transvenous coil occlusion of the cavernous sinus via a transfemoral and superior ophthalmic vein approach, at another center, with rapid improvement in her chemosis and ocular pressure. The visual acuity of the patient has returned to normal, but she continues to exhibit some diplopia. One patient underwent medial rec-



**FIGURE 2.** Right anteroposterior carotid artery angiograms for a 71-year-old woman with chemosis, tinnitus, and diplopia resulting from bilateral cavernous sinus DAVFs. *A*, ICA injection before radiosurgery, showing embolic occlusion of the M1 segment. The patient underwent immediate intra-arterial thrombolytic therapy, and her neurological status returned to baseline. *B*, ICA injection during embolization 3 days after radiosurgery, showing restoration of vessel patency.



tus muscle resection 34 months after radiosurgery, to improve persistent diplopia.

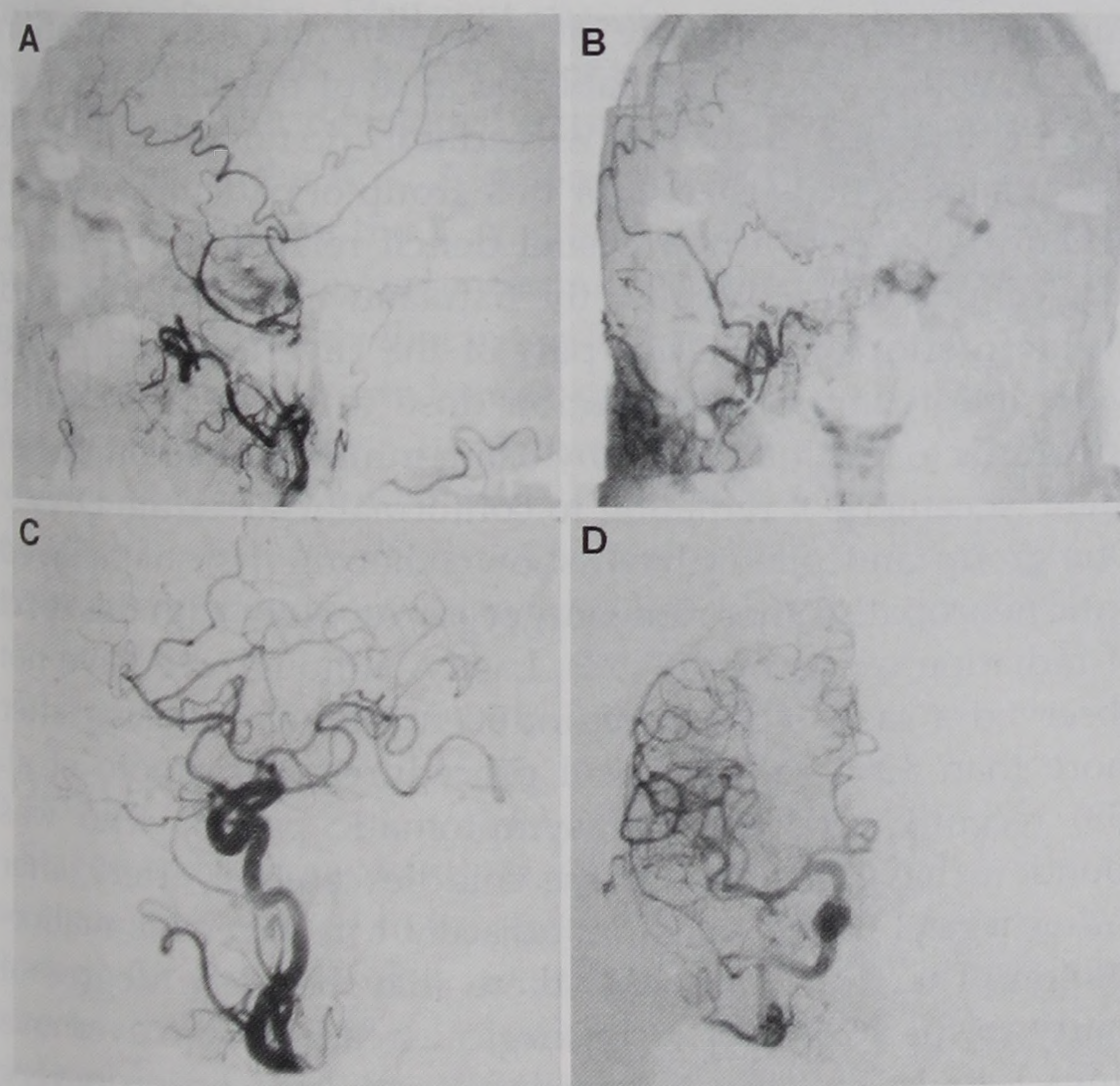
## ILLUSTRATIVE CASES

### Patient 1

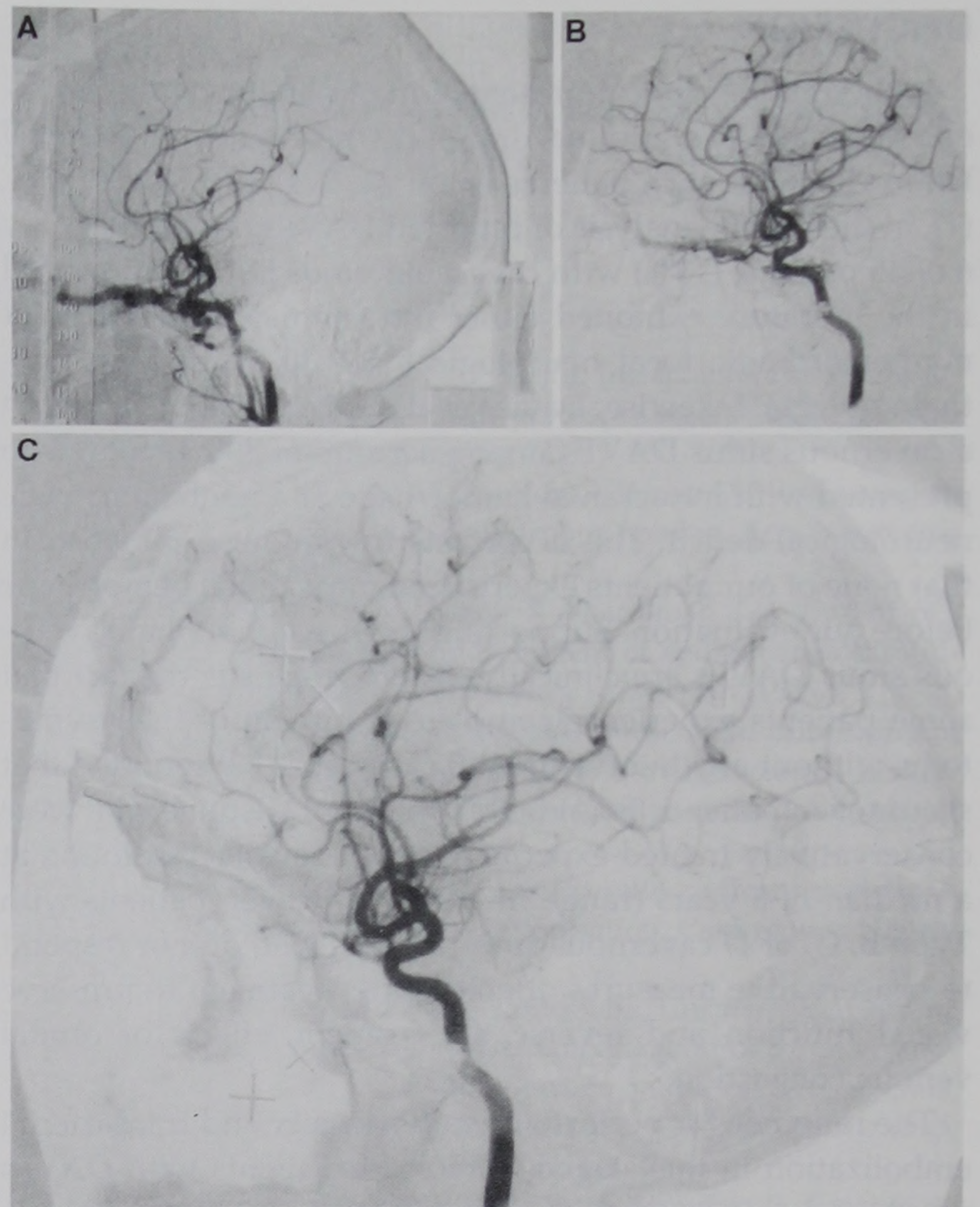
A 67-year-old man presented with chemosis, proptosis, diplopia, and eye pain resulting from a left cavernous sinus DAVF (Fig. 3). The Type D fistula received arterial supply from both the right and left ICA and ECA (3). Venous outflow was retrograde through the left superior ophthalmic vein, with no cortical venous drainage (Type IIa) (7). The patient underwent radiosurgery alone because it was not thought that significant reduction of the arteriovenous shunting could be accomplished by transfemoral embolization with acceptable risk. Two months after radiosurgery, the pain, chemosis, and diplopia of the patient had improved. One year later, the examination results were normal, and angiography showed that the DAVF had been completely obliterated.

### Patient 2

A 34-year-old woman presented with chemosis, proptosis, diplopia, and eye pain resulting from a left cavernous sinus DAVF (Fig. 4). Despite previous transarterial and transvenous embolization procedures performed at another center, the patient remained symptomatic. The arterial supply was from the left ECA and bilateral ICAs (Type D) (3). Venous outflow was through the left superior ophthalmic vein, without cortical venous drainage (Type IIa) (7). The patient underwent radiosurgery, followed by transarterial embolization 1



**FIGURE 3.** Patient 1. Right carotid artery angiograms for a 67-year-old man with chemosis/proptosis, diplopia, and eye pain resulting from a left cavernous sinus DAVF. The fistula also received arterial supply from the left ICA and ECA. *A* and *B*, lateral (*A*) and anteroposterior (*B*) ECA injections performed at the time of radiosurgery. *C* and *D*, lateral (*C*) and anteroposterior (*D*) common carotid artery injections performed 14 months after radiosurgery, showing complete obliteration of the DAVF.



**FIGURE 4.** Patient 2. Left lateral carotid artery angiograms for a 34-year-old woman with proptosis/chemosis, diplopia, and eye pain resulting from a left cavernous sinus DAVF. The patient had undergone an unsuccessful attempt at transvenous embolization 1 month earlier, at another institution. *A*, common carotid injection performed at the time of radiosurgery. *B*, ICA injection performed 11 months after radiosurgery and transarterial embolization, showing persistence of the DAVF. The patient underwent repeat embolization of the residual left ECA supply to the DAVF. *C*, ICA injection performed 22 months after radiosurgery, showing complete obliteration of the DAVF.

day later. The patient showed initial improvement but remained symptomatic 12 months later. Repeat angiography showed obliteration of the right ICA supply to the fistula and reduction of the left ICA and ECA supply. The patient underwent repeat embolization of the remaining left ECA arterial supply. At 20 months after radiosurgery, the patient experienced deterioration in her visual fields and acuity, and angiography showed that the arterial supply was again decreased; however, the patient exhibited nearly complete thrombosis of her inferior and superior ophthalmic veins and significant venous congestion of her entire orbit. The patient began to receive aspirin treatment and subcutaneous low-molecular weight heparin injections. After 2 months of antiplatelet and anticoagulation therapy, the redness and swelling in her left eye were much improved, and her visual acuity and fields had returned to normal. Repeat radiosurgery was planned; however, stereotactic angiography showed that the DAVF had been completely obliterated, and the head-frame was removed. Because the patient continued to exhibit partial thrombosis of her ophthalmic veins, she is still undergoing antiplatelet therapy.



## DISCUSSION

Although the clinical presentation of patients with cavernous sinus DAVFs is often dramatic, the risk of intracranial hemorrhage for such patients is low (1, 3, 4, 6–8). Awad et al. (1), in their meta-analysis of reported DAVFs, found that only 6 of 45 patients (13%) with cavernous sinus DAVFs described in the literature exhibited either intracranial hemorrhage or nonhemorrhagic focal neurological deficits other than ophthalmoplegia. Likewise, Davies et al. (8) found no patient with a cavernous sinus DAVF (among a group of 30 patients) who presented with intracranial hemorrhage or a nonhemorrhagic neurological deficit. This is consistent with our experience, in that none of our patients experienced intracranial hemorrhage before our evaluation. Supporting the perception that cavernous sinus DAVFs are clinically benign lesions is the fact that some patients experience complete remission of their symptoms without any intervention. Barrow et al. (3) reported that six of seven patients (86%) with Type B to D fistulae who were conservatively treated experienced spontaneous resolution at a median of 6 years (range, 1–16 yr). However, patients with Type B, C, or D cavernous sinus DAVFs who do not respond to conservative measures often require treatment to preserve visual function and reverse the cosmetic effects of orbital venous congestion.

The rationale for performing radiosurgery and transarterial embolization in this staged fashion for patients with DAVFs was based on a number of considerations that together maximize patient outcomes. First, radiosurgery was expected to produce long-term obliteration of most DAVFs in the months or years after the procedure (2, 5, 11, 18, 19). Barcia-Salorio et al. (2) reported 20 patients with low-flow cavernous sinus fistulae who underwent stereotactic radiosurgery. In that series, 18 of 20 patients (90%) experienced complete closure of their fistulae, and symptomatic improvement occurred in the first 1 to 2 months after radiosurgery. Second, when radiosurgery was performed before any embolization procedures, the entire DAVF could be demonstrated angiographically, for optimal dose-planning. This avoided the problem of partial irradiation of the fistula because of a component being temporarily occluded by embolization and thus not included in the radiosurgical plan (24). Third, patients with disabling symptoms or cortical venous drainage underwent particulate embolization after radiosurgery whenever possible, to provide rapid symptom improvement and early protection against hemorrhage during the latency period before radiation-induced obliteration. Similar to the experience of Grossman et al. (10), we found that complete relief of symptoms was usually obtained after partial embolization of the arterial supply to these complex lesions. Fourth, because radiation-induced obliteration of the DAVF was ongoing after radiosurgery, it was thought that the number of patients who would experience symptomatic recurrence because of recanalization of the embolized vessels would be low. In fact, no patient in our series has experienced symptomatic recurrence during follow-up periods extending up to 5 years after radiosurgery. We think that this staged approach is very effective

in providing both rapid improvement of symptoms and long-term cure of DAVFs.

With an approach of staged radiosurgery and transarterial embolization, or radiosurgery alone when transarterial embolization was deemed not possible or of little benefit, 19 of 20 patients (95%) with cavernous sinus DAVFs experienced significant symptom improvement within weeks to several months after the procedures. This interval to symptom improvement is much shorter than the natural history of spontaneous symptom resolution for patients treated conservatively (3). No patient has experienced a recurrence of symptoms during the follow-up period. Total or nearly total (more than 95%) obliteration was observed for all patients ( $n = 14$ ) who underwent follow-up angiography 12 months or more after radiosurgery. The rates of temporary and permanent neurological deficits related to this management strategy were 10% and 5%, respectively. These results are quite similar to the recently published report by Guo et al. (11). Among their series of patients treated using gamma knife radiosurgery alone, complete obliteration was observed in follow-up angiograms, obtained 6 to 15 months after radiosurgery, for 12 of 15 patients (80%) with cavernous sinus DAVFs. No patient experienced either symptom recurrence or radiation-related complications after radiosurgery.

Delayed oculomotor or trigeminal nerve deficits have been documented for approximately 10% of patients undergoing radiosurgery for treatment of lesions of the cavernous sinus (22, 28). In our series, no patient developed diplopia or facial numbness, despite the use of a median marginal radiation dose of 20 Gy. This is probably because of the small number of patients in our study, and we certainly do not think that the risk of such deficits is zero for this group of patients. Also, no patient developed a new visual deficit related to the radiosurgical procedure. Because the fistulae were usually located in the inferior or posterior part of the cavernous sinus, we were able to limit the radiation dose to the adjacent optic apparatus to less than 10 Gy by using multiple (median, three) small isocenters of radiation to conformally cover the DAVF. Our group and others have shown that the risk of delayed optic neuropathy after radiosurgery is very low with this level of radiation exposure (17, 22). Lastly, although we have not observed a case of radiation-induced arterial occlusion after more than 1200 radiosurgical procedures, Yamamoto et al. (33) recently reported an asymptomatic patient who was found to have stenosis of the middle cerebral artery after radiosurgical treatment of an adjacent arteriovenous malformation. Therefore, although there may be some degree of injury to the ICA after radiosurgical treatment of cavernous sinus lesions, the risk of symptomatic ICA occlusion is very low.

Transfemoral transvenous embolization is increasingly being recognized as an important therapeutic alternative for cavernous sinus DAVFs (12, 25). We regard transfemoral transvenous embolization as a viable management option when the pertinent venous anatomic features are favorable. However, none of the patients in this series had an angiographically patent inferior petrosal sinus ipsilateral to the cavernous sinus DAVF. In addition, transfemoral transvenous



embolization does involve a risk of vascular perforation and cerebral venous infarction (15, 32). Moreover, the long-term effects of iatrogenic cavernous sinus occlusion are unknown.

We think that our results compare quite favorably with recent studies of both endovascular and microsurgical treatment of patients with cavernous sinus DAVFs. Miller et al. (21) reported the results of 10 patients with Type B to D cavernous sinus DAVFs who underwent transvenous embolization via the superior ophthalmic vein. With a median follow-up period of 6 years, all patients experienced symptom improvement. One patient required an additional transarterial particulate embolization procedure for complete closure of the fistula. Several patients (number not specified) experienced "transient worsening of ocular misalignment"; one patient developed new VIth cranial nerve weakness, which did not resolve and necessitated later strabismus surgery. Roy and Raymond (25) treated 12 patients with cavernous sinus DAVFs, using either a transarterial ( $n = 1$ ), transvenous ( $n = 9$ ), or combined endovascular ( $n = 2$ ) approach. Eleven of 12 patients (92%) were cured at a median time of 6 months after embolization. Transient VIth cranial nerve weakness was observed for five patients (42%); one patient experienced permanent abducens palsy. Day and Fukushima (9) performed microsurgery for nine patients with Type D cavernous sinus DAVFs who experienced failure of prior embolization attempts. All patients experienced resolution of their symptoms, and complete obliteration was confirmed by postoperative angiography. Transient diplopia and facial numbness occurred in all patients but resolved by 6 months after surgery. One patient developed permanent hemiparesis related to occlusion of the ICA. A second patient experienced postoperative stenosis of the ICA, which caused temporary hemiparesis. No patient experienced recurrence of symptoms during follow-up periods that extended from 1 to 14 years. Tu et al. (29) surgically treated three patients with either Type C ( $n = 1$ ) or Type D ( $n = 2$ ) cavernous sinus DAVFs that could not be successfully embolized. The DAVFs were obliterated for all three patients, and no patient experienced symptom recurrence during an average follow-up period of 27 months.

## CONCLUSION

Staged radiosurgery and transarterial embolization, whenever possible, proved to be a safe and effective management strategy for patients with cavernous sinus DAVFs. This approach provides rapid relief of symptoms and long-term angiographic cure and is well tolerated by patients.

## ACKNOWLEDGMENTS

We thank the late Dr. Thoralf M. Sundt, Jr., for envisioning this novel approach to the treatment of patients with DAVFs, based on his vast clinical experience, and Dr. Robert J. Coffey for contributing to the Mayo Clinic gamma knife program between 1990 and 1997.

Received, January 15, 1999.

Accepted, May 14, 1999.

Reprint requests: Bruce E. Pollock, M.D., Department of Neurological Surgery, Mayo Clinic, 200 First Street, SW, Rochester, MN 55905.

## REFERENCES

- Awad IA, Little JR, Akrawi WP, Ahl J: Intracranial dural arteriovenous malformations: Factors predisposing to an aggressive neurological course. *J Neurosurg* 72:839-850, 1990.
- Barcia-Salorio JL, Soler F, Hernandez G, Barcia JA: Radiosurgical treatment of low flow carotid-cavernous fistulae. *Acta Neurochir (Wien)* 52:93-95, 1991.
- Barrow DL, Spector RH, Braun IF, Landman JA, Tindall SC, Tindall GT: Classification and treatment of spontaneous carotid-cavernous sinus fistulas. *J Neurosurg* 62:248-256, 1985.
- Brown RD, Wiebers DO, Nichols DA: Intracranial dural arteriovenous fistulae: Angiographic predictors of intracranial hemorrhage and clinical outcome in nonsurgical patients. *J Neurosurg* 81:531-538, 1994.
- Chandler HC Jr, Friedman WA: Successful radiosurgical treatment of a dural arteriovenous malformation: Case report. *Neurosurgery* 33:139-142, 1993.
- Coffey RJ, Link MJ, Nichols DA, Pollock BE, Gorman DA: Gamma knife radiosurgery and particulate embolization of dural arteriovenous fistulas, with a special emphasis on the cavernous sinus, in Lunsford LD, Kondziolka D, Flickinger JC (eds): *Gamma Knife Brain Surgery*. Basel, Karger, 1998, pp 60-77.
- Cognard C, Gobin YP, Pierot L, Bailly A, Houdart E, Casasco A, Chiras J, Merland J: Cerebral dural arteriovenous fistulas: Clinical and angiographic correlation with a revised classification of venous drainage. *Neuroradiology* 194:671-680, 1995.
- Davies MA, TerBrugge K, Willinsky R, Coyne T, Saleh J, Wallace MC: The validity of classification for the clinical presentation of intracranial dural arteriovenous fistulas. *J Neurosurg* 85:830-837, 1996.
- Day JD, Fukushima T: Direct microsurgery of dural arteriovenous malformation type carotid-cavernous sinus fistulas: Indications, technique, and results. *Neurosurgery* 41:1119-1126, 1997.
- Grossman RI, Sergott RC, Goldberg HI, Savino PJ, Zimmerman RA, Bilaniuk LT, Schatz NJ, Bosely TM: Dural malformations with ophthalmic manifestations: Results of particulate embolization in seven patients. *AJNR Am J Neuroradiol* 6:809-813, 1985.
- Guo W, Pan DHC, Wu H, Chung W, Shiau C, Wang L, Chiou H, Yen M, Teng MMH: Radiosurgery as a treatment alternative for dural arteriovenous fistulas of the cavernous sinus. *AJNR Am J Neuroradiol* 19:1081-1087, 1998.
- Halbach VV, Higashida RT, Hieshima GB, Hardin CW, Pribram H: Transvenous embolization of dural fistulas involving the cavernous sinus. *AJNR Am J Neuroradiol* 10:377-383, 1989.
- Hamby WB: Carotid-cavernous fistula: Report of 32 surgically treated cases and suggestions for definitive operation. *J Neurosurg* 21:859-865, 1964.
- Ishimori S, Hattori M, Shibata Y, Shizawa H, Fujinaga R: Treatment of carotid-cavernous fistula by Gelfoam embolization. *J Neurosurg* 27:315-319, 1967.
- King WA, Hieshima GB, Martin NA: Venous rupture during transvenous approach to a carotid-cavernous fistula. *J Neurosurg* 71:133-137, 1989.
- Kupersmith MJ, Berenstein A, Choi IS, Warren F, Flamm E: Management of nontraumatic vascular shunts involving the cavernous sinus. *Ophthalmology* 95:121-130, 1988.



17. Leber KA, Berglöff J, Pendl G: Dose-response of the visual pathways and cranial nerves of the cavernous sinus to stereotactic radiosurgery. *J Neurosurg* 88:43-50, 1998.
18. Lewis AI, Tomsick TA, Tew JM Jr: Management of tentorial arteriovenous malformations: Transarterial embolization combined with stereotactic radiation or surgery. *J Neurosurg* 81:851-859, 1994.
19. Link MJ, Coffey RJ, Nichols DA, Gorman DA: The role of radiosurgery and particulate embolization in the treatment of dural arteriovenous fistulas. *J Neurosurg* 84:804-809, 1996.
20. Lucas CP, Zabramski JM, Spetzler RF, Jacobowitz R: Treatment for intracranial dural arteriovenous malformations: A meta-analysis from the English language literature. *Neurosurgery* 40:1119-1132, 1997.
21. Miller NR, Monsein LH, Debrun GM, Tamargo RJ, Nauta HJW: Treatment of carotid-cavernous sinus fistulas using a superior ophthalmic vein approach. *J Neurosurg* 83:838-842, 1998.
22. Morita A, Coffey RJ, Foote RL, Schiff D, Gorman DA: Risk of injury to cranial nerves after gamma knife radiosurgery for skull base meningiomas: Experience in 88 patients. *J Neurosurg* 90:42-49, 1999.
23. Mullan S: Treatment of carotid-cavernous fistulas by cavernous sinus occlusion. *J Neurosurg* 50:131-144, 1979.
24. Pollock BE, Kondziolka D, Lunsford LD, Bissonette DJ, Flickinger JC: Repeat stereotactic radiosurgery of arteriovenous malformations: Factors associated with incomplete obliteration. *Neurosurgery* 38:318-324, 1996.
25. Roy D, Raymond J: The role of transvenous embolization in the treatment of intracranial dural arteriovenous fistulas. *Neurosurgery* 40:1133-1144, 1997.
26. Takahashi A, Yoshimoto T, Kawakami K, Sugawara T, Suzuki J: Transvenous copper wire insertion for dural arteriovenous malformations of cavernous sinus. *J Neurosurg* 70:751-754, 1989.
27. Teng MM, Guo WY, Huang CI, Wu CC, Chang T: Occlusion of arteriovenous malformations of the cavernous sinus via the superior ophthalmic vein. *AJNR Am J Neuroradiol* 9:539-546, 1988.
28. Tishler RB, Loeffler JS, Lunsford LD, Duma C, Alexander E, Kooy HM, Flickinger JC: Tolerance of cranial nerves of the cavernous sinus to radiosurgery. *Int J Radiat Oncol Biol Phys* 27:215-221, 1993.
29. Tu YK, Liu HM, Hu SC: Direct surgery of carotid cavernous fistulae and dural arteriovenous malformations of the cavernous sinus. *Neurosurgery* 41:798-806, 1997.
30. Uflacker R, Lima S, Ribas GC, Piske RL: Carotid-cavernous fistulas: Embolization through the superior ophthalmic vein approach. *Radiology* 159:175-179, 1986.
31. Viñuela F, Fox AJ, Debrun GM, Peerless SJ, Drake CG: Spontaneous carotid-cavernous fistulas: Clinical, radiological, and therapeutic considerations—Experience with 20 cases. *J Neurosurg* 60:976-984, 1984.
32. Watanabe A, Hirano K, Suzuki Y, Kamada M, Mohri Y, Okamura H, Ishii R: Venous congestion of the insular cortex after transvenous coil embolization of a dural carotid-cavernous sinus fistula, in Taki W, Picard L, Kikuci H (eds): *Advances in Interventional Neuroradiology and Intravascular Neurosurgery*. Amsterdam, Elsevier Science, 1996, pp 271-274.
33. Yamamoto M, Ide M, Jimbo M, Ono Y: Middle cerebral artery stenosis caused by relatively low-dose irradiation with stereotactic radiosurgery for cerebral arteriovenous malformations: Case report. *Neurosurgery* 41:474-478, 1997.

## COMMENTS

Pollock et al. describe 13 patients who were treated using radiosurgery and then embolization. I do not completely understand the rationale for this study. There are no conclusive data indicating that reductions in flow accelerate occlusion after radiosurgery. In addition, the purpose of embolization before radiosurgical intervention should be to reduce nidus size, so that the volume is decreased and maximal radiation doses can be achieved. It is also known that patients with cortical venous drainage should be treated as soon as possible, to prevent subarachnoid hemorrhage. Patients 1 and 2 had very large superior ophthalmic veins and would be excellent candidates for the transvenous approach, which is associated with relatively low morbidity rates. In addition, embolization was associated with a 15% complication rate for these patients, which would be considered unacceptably high in most centers. I agree that transarterial embolization of Type C and D lesions is often futile, and a transvenous approach is often required. In cases in which the transvenous approach has been attempted and has proven unsuccessful, radiosurgical intervention is certainly reasonable.

**Robert H. Rosenwasser**  
Philadelphia, Pennsylvania

Pollock et al. report 20 patients with cavernous sinus dural arteriovenous fistulae. These lesions are different from traumatic high-flow fistulae and are associated with spontaneous resolution in 10 to 60% of cases.

All patients in this study were symptomatic and had experienced failure of conservative treatment. This article proposes tailored radiosurgery for the entire cavernous sinus, on the basis of stereotactic angiography and stereotactic magnetic resonance imaging. Because radiosurgery involves a latency interval before closure of the fistula, the goal of combining radiosurgery with embolization has been previously addressed by this group (2). The concept of using radiosurgery before embolization is elegant, and this approach can facilitate delineation of the target if the target volume is appropriate for radiosurgery. When the combination of the two techniques was possible, the time to symptom relief was significantly shorter (median, 2 wk versus 6 mo for radiosurgery alone). Nineteen of 20 patients (95%) experienced significant symptom improvement; although the natural course is favorable, this interval to symptom improvement seems to be much shorter. The rates of temporary and permanent neurological deficits related to this management strategy were 10 and 5%, respectively, and deficits were correlated with the endovascular procedures. For each patient, these management risks should be compared with the risk of causing permanent morbidity with a conservative approach.

The results from this study are promising but, because these lesions tend to resolve spontaneously and neurological complications were observed for 15% of the patients, it is wise to reserve treatment for patients with visual deterioration, obstructive diplopia, "malignant" proptosis, or intolerable bruit, as suggested by Barrow et al. (1). These indications are not absolute, however, and depend on the general physical con-



dition of the patient, the severity of the symptoms, and the anatomic features of the fistula.

**Lars Kihlström**  
**Iver A. Langmoen**  
*Stockholm, Sweden*

1. Barrow DL, Spector RH, Braun IF, Landman JA, Tindall SC, Tindall GT: Classification and treatment of spontaneous carotid-cavernous sinus fistulas. *J Neurosurg* 62:248-256, 1985.
2. Link MJ, Coffey RJ, Nichols DA, Gorman DA: The role of radiosurgery and particulate embolization in the treatment of dural arteriovenous fistulas. *J Neurosurg* 84:804-809, 1996.

Pollock et al. report 20 patients who underwent multimodality treatment of dural arteriovenous malformations of the cavernous sinus. Some underwent radiosurgery alone and some underwent both radiosurgery and transarterial embolization. The vast majority of patients experienced improvement of their clinical symptoms, and many of the patients who were eligible for follow-up angiography showed successful obliteration of their malformations. Risks were relatively

low, in terms of both new neurological symptoms and recurrence of the original symptoms. Many of the transient symptoms developed as a result of embolization techniques used in adjuvant treatment in the pre- or postradiosurgical periods. This multimodality approach, sometimes with both radiosurgery and embolization and sometimes with radiosurgery alone, seems to provide low-risk management for these difficult lesions, especially for patients with lesions that are not easily treated or cured by embolization alone. Radiosurgical pretreatment followed by embolization for symptomatic patients, during the wait for the development of radiosurgical benefits, seems to be the proper staging technique. This approach obviates the problems that develop because of the inability to define the target volume when embolization precedes radiosurgery. Radiosurgery seems to provide permanent obliteration, whereas embolization provides only temporary obliteration in certain cases. The symptoms can be temporarily controlled by embolization during the wait for the development of the full benefits of radiosurgery. This report provides longer-term documentation of the sustained benefits of this multimodality approach.

**L. Dade Lunsford**  
*Pittsburgh, Pennsylvania*

### Future Meetings—Congress of Neurological Surgeons

The following are the planned sites and dates for future annual meetings of the Congress of Neurological Surgeons:

1999	Boston, MA	October 30–November 4
2000	San Antonio, TX	September 23–28
2001	San Diego, CA	September 29–October 4
2002	Philadelphia, PA	September 21–26

### Future Meetings—American Association of Neurological Surgeons

The following are the planned sites and dates for future annual meetings of the American Association of Neurological Surgeons:

2000	San Francisco, CA	April 8–13
2001	Toronto, Ontario, Canada	April 21–26
2002	Chicago, IL	April 6–11
2003	San Diego, CA	April 26–May 1