

Serial angiography and endovascular treatment of dissecting aneurysms of the anterior cerebral and vertebral arteries

Case report

KENICHI AMAGASAKI, M.D., TSUTOMU YAGISHITA, M.D., SHINICHI YAGI, M.D., KATSUHIRO KURODA, M.D., KAZUYUKI NISHIGAYA, M.D., AND HIDEAKI NUKUI, M.D.

Department of Neurosurgery, Yamanashi Medical University, Nakakoma-gun, Yamanashi, Japan

✓ This 47-year-old man was admitted to the hospital with disturbance of consciousness due to subarachnoid hemorrhage caused by a ruptured dissecting aneurysm of the left anterior cerebral artery (ACA). Conservative treatment resulted in improvement in the patient's consciousness; however, repeated rupture occurred during the chronic stage. Endovascular coil embolization of the parent artery was successful. Serial angiography demonstrated all stages in the development of the aneurysm. Follow-up angiography demonstrated an incidental dissecting aneurysm of the right vertebral artery. This aneurysm was also treated by endovascular embolization. No new neurological deficit appeared during or after the treatment.

Multiple dissecting aneurysms are rare, especially those involving both supra- and infratentorial regions. A ruptured dissecting aneurysm of the ACA is also an uncommon vascular disorder. This case shows that rebleeding may occur, even during the chronic stage, and thus appropriate treatment for the prevention of subsequent bleeding is essential. Incidental dissecting aneurysms can be treated using the endovascular technique, but further study is necessary.

KEY WORDS • multiple dissecting aneurysm • dissecting aneurysm of the anterior cerebral artery • endovascular therapy

AN intracranial dissecting aneurysm in the posterior circulation often manifests as subarachnoid hemorrhage (SAH) but rarely as ischemic stroke.^{8,18} Those located in the anterior circulation usually manifest as ischemic stroke resulting from arterial stenosis or occlusion; SAH in these cases is rare.^{2,14,16}

Dissecting aneurysms that result in ischemic events can be treated nonsurgically.^{9,23} However, therapeutic intervention should be considered for cases manifesting as hemorrhagic events.¹² Trapping of the aneurysm or proximal ligation of the parent artery is the treatment of choice, but other methods should be considered for cases with vascular complexity or poor blood supply.

The incidence of intracranial dissecting aneurysms has been increasing in recent years, but spontaneous multiple dissecting aneurysms remain very rare and only seven bilateral dissecting aneurysms of the vertebral arteries (VAs) have been described in the literature.^{1,2,12,20} We treated a 47-year-old man with a ruptured dissecting aneurysm of the anterior cerebral artery (ACA). The aneurysm subsequently ruptured during the chronic stage, and angiographic studies led to the incidental discovery of an unrup-

tured dissecting aneurysm of the VA. Serial angiography demonstrated all stages of the development of the first aneurysm. Both lesions were treated successfully by intravascular coil embolization of the parent arteries.

Case Report

This 47-year-old man with known hypertension experienced a sudden onset of headache followed by loss of consciousness and was admitted to our institution in a semicomatose condition.

Initial Examination and Treatment. On admission, the patient's blood pressure was 280/180 mm Hg. Shortly after admission he became stuporous and developed severe right-sided hemiparesis. A physical examination found no abnormality, and the results of blood, urine, and coagulation studies were normal. Computerized tomography (CT) scanning revealed SAH associated with intracerebral hematoma bilaterally in the corpus callosum and a left intraventricular hematoma (Fig. 1 *left*). Digital subtraction (DS) angiography of the left internal carotid artery re-

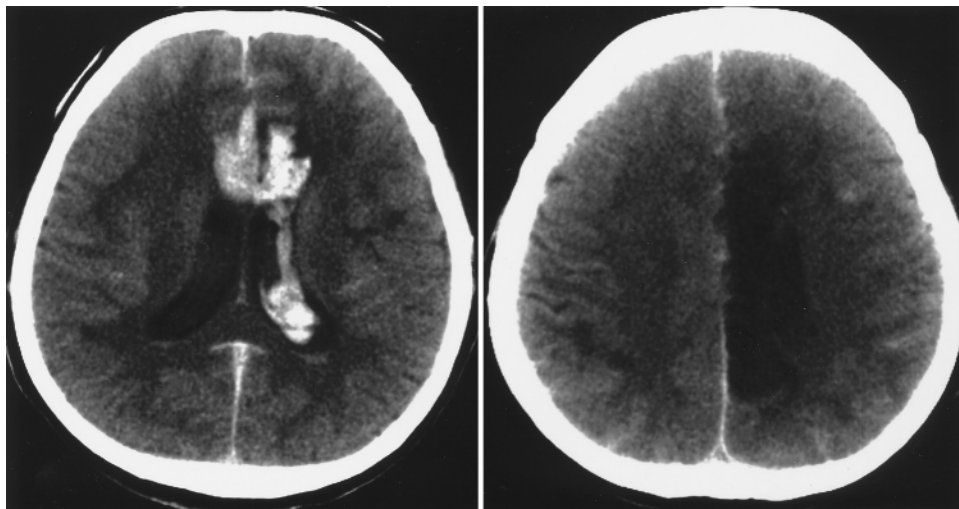


FIG. 1. Computerized tomography scans. *Left:* Scan obtained on admission revealing a massive interhemispheric hemorrhage and left intraventricular hematoma. *Right:* Scan obtained 1 week later demonstrating a new large low-density area in the region of the left ACA.

vealed a fusiform dilation of the left A₃ segment (Fig. 2 upper).

The patient was treated nonsurgically. One week after onset of symptoms, a CT scan demonstrated cerebral infarction in the left ACA perfusion area (Fig. 1 right). Four weeks later the patient became alert, but his severe right-sided hemiparesis persisted. Seven weeks after the initial angiography was performed, a repeated DS angiogram demonstrated remarkable narrowing of the A₃ through A₅ segments and a small widening of the artery proximal to the stenosis (Fig. 2 lower). The patient was transferred to another hospital for rehabilitation.

Second Examination and Treatment. Fifteen weeks after the patient first experienced symptoms, he was alert but complained of severe headache. Computerized tomography scanning revealed an intracerebral hematoma in the same region as the initial hemorrhage and bilateral intraventricular hemorrhage (Fig. 3). Again the patient was transferred to our hospital. Digital subtraction angiography revealed persistence of the narrowing of the left ACA, and a new abnormal irregular widening at the A₄ segment. The lesion had a double lumen (Fig. 4 upper). The patient was treated conservatively. He experienced no deterioration in consciousness; however, the severe right-sided hemiparesis remained. Repeated DS angiography performed 3 weeks after the second bleed demonstrated that the lesion had progressively narrowed; however, the false lumen was more irregular and there was aneurysmal out-pouching (Fig. 4 center). Endovascular treatment via the left internal carotid artery was unsuccessful because of the tortuosity of the right A₁ segment. One week later, treatment was performed from the opposite side.

First Operation. A No. 6 French guiding catheter was inserted into the right internal carotid artery via the right femoral artery, and a catheter (Prowler-10; Cordis/Johnson & Johnson Medical, Miami, FL) was introduced into the left A₃ segment through the anterior communicating artery while the patient was fully heparinized and under-

going electroencephalographic monitoring. A provocation test in which 50 mg isomital and 40 mg lidocaine were administered resulted in no change in either the patient's clinical symptoms or electroencephalographic readings. Ten short platinum coils (five 3/8-mm C-shaped and five 5-mm straight coils) were placed in the A₃ segment to occlude the orifice of the dissecting lumen, and both parent artery and aneurysm were occluded (Fig. 4 lower). After the procedure, heparinization was reversed by intravenous administration of protamine sulfate.

First Postoperative Course and New Findings. The patient's postoperative course was uneventful. Digital subtraction angiography performed 1 week posttreatment confirmed complete occlusion of the dissecting aneurysm but incidentally revealed a right VA dissecting aneurysm (Fig. 5 left). After obtaining informed consent, endovascular treatment for the latter aneurysm was planned. A balloon occlusion test performed 1 week before treatment showed that the patient would tolerate right VA occlusion.

Second Operation. Two No. 6 French guiding catheters were inserted into the right VA via the bilateral femoral arteries. A supernavigator silicone balloon catheter (0.7 mm in diameter when deflated) (Kaneka Medix Corp., Osaka, Japan) was introduced into the anterior inferior cerebellar artery just distal to its origin, and blood flow was decreased by balloon inflation. Using a marker catheter (Fastracker-18MX 2; Target Therapeutics/Boston Scientific Corp., Fremont, CA), five interlocking detachable coils (one measuring 3 mm in diameter, 10 cm long; three 2 mm in diameter, 4 cm long; and one 3 mm in diameter, 6 cm long) were inserted and released carefully. These coils were delivered into both the proximal and distal areas of the parent artery as well as the aneurysm, preserving the right anterior and posterior inferior cerebellar arteries. The coils remained stable after the balloon was deflated, and the patencies of both the anterior and posterior inferior cerebellar arteries were subsequently confirmed (Fig. 5 center and right).

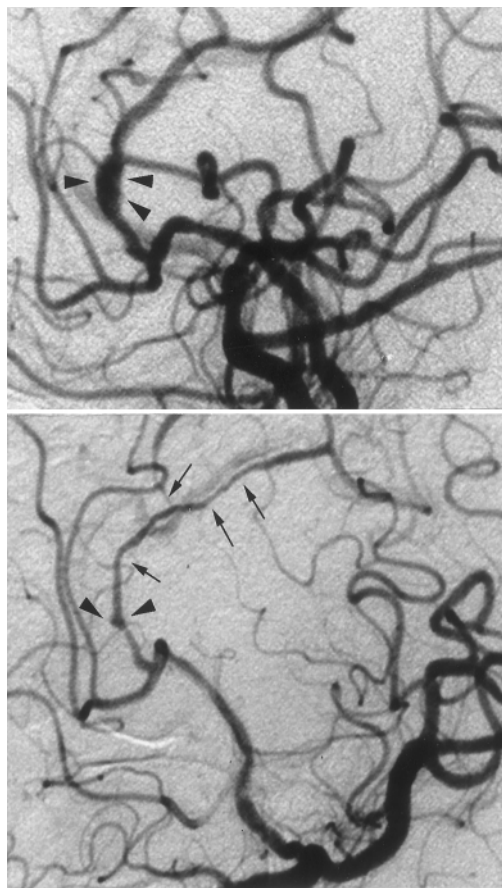


FIG. 2. Lateral left carotid artery angiograms obtained during the patient's first hospitalization. *Upper*: Angiogram obtained on admission revealing a sausagelike swelling of the left A₃ segment (arrowheads). *Lower*: Angiogram obtained 7 weeks later demonstrating narrowing of the A₃ through A₅ segments (arrows) and a small proximal widening (arrowheads).

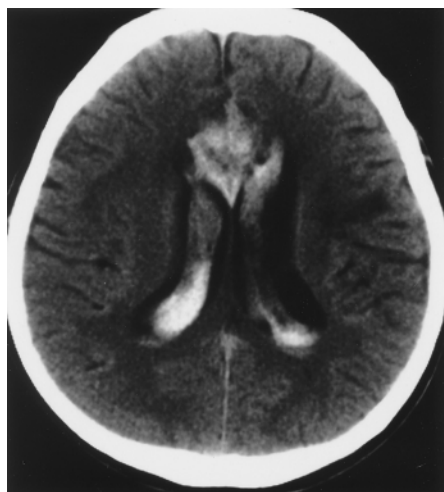


FIG. 3. Computerized tomography scan obtained 15 weeks after the initial scan was obtained, demonstrating recurrent interhemispheric hemorrhage and bilateral intraventricular hematomas.

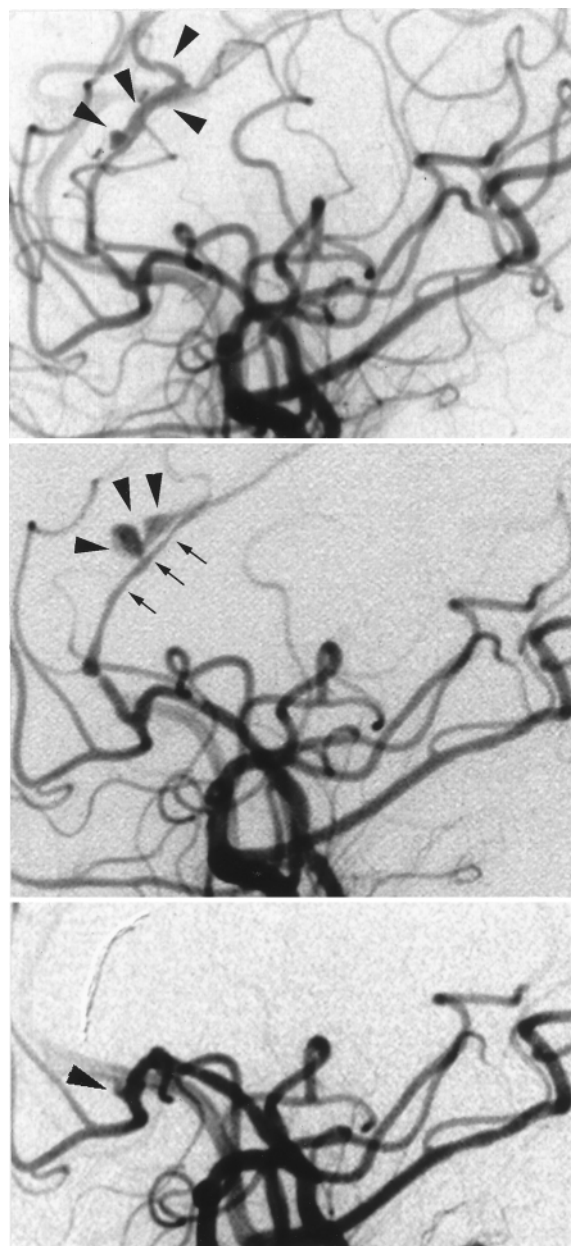


FIG. 4. Lateral left carotid artery angiograms obtained during the patient's second admission. *Upper*: Angiogram obtained on the second admission revealing a new irregular false lumen at the A₄ and A₅ segments (arrowheads), which demonstrate a double lumen. *Center*: Angiogram obtained 3 weeks after the second onset of symptoms, demonstrating progressive narrowing of the lesion (arrows) and aneurysmal outpouching of the false lumen (arrowheads). *Lower*: Angiogram obtained after embolization, confirming complete occlusion of the parent artery (arrowhead).

Second Postoperative Course. The patient exhibited no new neurological symptoms during or after the treatment and was eventually transferred to another hospital for rehabilitation.

Discussion

Ruptured dissecting aneurysms in the posterior circula-

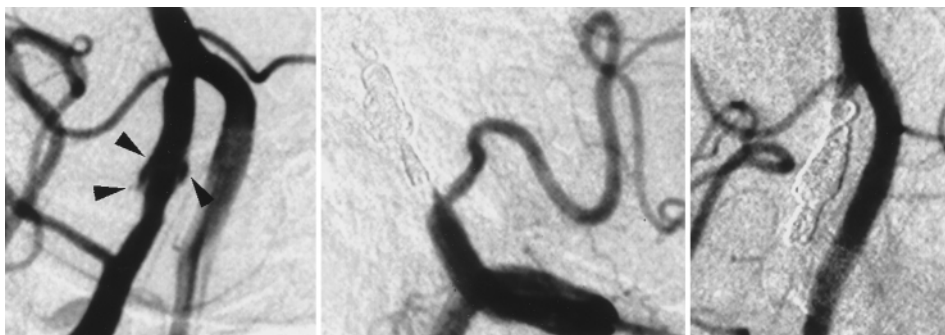


FIG. 5. *Left:* Vertebral artery angiogram obtained before coil embolization, demonstrating a false lumen along the artery between the origin of the anterior and posterior inferior cerebellar arteries (*arrowheads*). *Center and Right:* Right (*center*) and left (*right*) VA angiograms obtained after coil embolization, demonstrating no opacification of the dissecting aneurysm, but both the anterior and posterior inferior cerebellar arteries have been spared.

tion carry the greatest risk of repeated rupture within the first 24 hours.¹² Rebleeding is less likely to occur after 2 weeks and some cases even show spontaneous regression.^{2,18} Dissecting aneurysms in the anterior circulation rarely manifest as hemorrhage, and thus their natural history after hemorrhage is unclear. Nine previous cases of dissecting aneurysm of the ACA presented with onset of hemorrhage, but only one was associated with cerebral infarction in the affected lesion at the initial onset as in our case.^{3,4,6,7,11,15,17,19,21} In our case the patient suffered rebleeding from the dissecting aneurysm 15 weeks after the first attack, and angiography confirmed progressive dissection. Dissecting aneurysms of the ACA may result in subsequent rupture at any stage after the first bleeding. Further accumulation of data in such cases is necessary to determine the natural history of these aneurysms more clearly.

A definitive diagnosis of dissecting aneurysm is sometimes difficult to make because imaging may reveal occlusive lesions. Other well-known angiographic findings such as the pearl-and-string sign and the rosette sign are also found in atherosclerotic disease. A double lumen with opacification of both true and false lumens, as found in our case, may be a specific diagnostic sign; however, its appearance on angiograms occurs only occasionally.^{10,13}

The mechanism responsible for bleeding is thought to be transmural perforation due to the dissection. Intracranial dissecting aneurysms can be classified into two types on the basis of clinicopathological findings.²² Dissection occurs between the internal elastica and the media in the first type and within the media or adventitia in the second type. The first type often presents as ischemic stroke and the second as hemorrhage.²² In our case, only angiographic findings were available; however, based on the serial angiograms, we suggest that dissection can develop from the first type to the second type and finally result in hemorrhage. The initial angiographic study in our case revealed only localized dissection, but the second study revealed remarkable stenosis distal to the fusiform dilation, which implies that the first type of dissection had progressed distally in the first 7 weeks. The third angiographic study performed at the time of the second bleeding revealed a typical double lumen appearing along the narrowing lesion, which was presumably responsible for the bleeding. The dissection between the internal elastica and the media may

have progressed to the adventitia, and finally, collapse of the vascular wall resulted in extravascular bleeding.

Treatment of intracranial dissecting aneurysms depends on the type of their initial onset and their location. Dissecting aneurysms with ischemic onset can be treated nonsurgically,^{9,23} but prevention of subsequent bleeding should be considered in the case of hemorrhagic onset. Dissecting aneurysms in the posterior circulation should be treated surgically during the early stage because of the high risk of rebleeding within 24 hours.¹² Surgical treatment usually includes trapping or proximal ligation of the parent artery. Endovascular treatment of dissecting aneurysms in the posterior circulation also has been used.⁵ However, these treatments can be complicated when applied to the anterior circulation because of the anatomical complexity. Surgical treatment has been used in previous cases, when possible, for prevention of subsequent bleeding. Depending on the location of the aneurysm and the collateral blood flow, wrapping, resection of the lesion, proximal occlusion, and trapping (with or without anastomosis) are the choices of surgical treatment.^{14,19} Surgical treatment of cases of dissecting aneurysms of the ACA include clipping with angioplasty, resection of the dissecting lesion, and trapping.^{4,7,11,15,19,21} In one case, trapping was combined with distal side-to-side anastomosis for preservation of blood flow.²¹ In our case, occlusion proximal to the A₃ segment was considered because the severe hemiparesis due to the ischemic stroke had remained unchanged for 5 months. However, to perform that procedure would have risked the development of a new neurological deficit and, therefore, intravascular treatment using the provocation test was selected. If the patient had proved to be intolerant to the test, possible treatment choices would have been wrapping of the affected lesion with maximum exposure or trapping of the proximal segment with possible distal side-to-side anastomosis. Both procedures would have been very difficult to perform. Fortunately, the patient tolerated the procedure well and endovascular treatment resulted in a successful outcome.

Treatment of an incidental unruptured dissecting aneurysm is not so well known. Unruptured dissecting aneurysms manifesting as ischemic events often result in a benign outcome in response to conservative treatment alone, but the natural history of incidental dissecting aneu-

rysms is not well documented. Intravascular treatment is less invasive than surgical treatment for prevention of bleeding and can be achieved safely using the provocation test.

The present case shows that endovascular treatment can be used to treat a dissecting aneurysm that presents surgical difficulty, as well as such aneurysms found incidentally.

References

1. Caplan LR, Baquis GD, Pessin MS, et al: Dissection of the intracranial vertebral artery. **Neurology** **38**:868–877, 1988
2. Friedman AH, Drake CG: Subarachnoid hemorrhage from intracranial dissecting aneurysm. **J Neurosurg** **60**:325–334, 1984
3. Gherardi GJ, Lee HY: Localized dissecting hemorrhage and arteritis. Renal and cerebral manifestation. **JAMA** **199**:187–188, 1967
4. Guridi J, Gállego J, Monzón F, et al: Intracerebral hemorrhage caused by transmural dissection of the anterior cerebral artery. **Stroke** **24**:1400–1402, 1993
5. Halbach VV, Higashida RT, Dowd CF, et al: Endovascular treatment of vertebral artery dissections and pseudoaneurysms. **J Neurosurg** **79**:183–191, 1993
6. Hayashi N, Fukuda O, Endo S, et al: [Intracerebral hemorrhage secondary to dissecting aneurysm of the anterior cerebral artery.] **No To Shinkei** **48**:1053–1056, 1996 (Jpn)
7. Honda N, Yuge T, Miyagi J, et al: [A surgical case of dissecting aneurysm of the anterior cerebral artery.] **Jpn J Neurosurg** **6**:634–638, 1997 (Jpn)
8. Kidooka M, Okada T, Sonobe M, et al: Dissecting aneurysm of the anterior cerebral artery: report of two cases. **Surg Neurol** **39**:53–57, 1993
9. Kitanaka C, Tanaka JJ, Kuwahara M, et al: Nonsurgical treatment of unruptured intracranial vertebral artery dissection with serial follow-up angiography. **J Neurosurg** **80**:667–674, 1994
10. Kunze S, Schiefer W: Angiographic demonstration of a dissecting aneurysm of the middle cerebral artery. **Neuroradiology** **2**:201–206, 1971
11. Matsumoto T, Yamaura I, Tani E, et al: [A case of anterior cerebral artery dissecting aneurysm presenting subarachnoid hemorrhage.] **Surg Cereb Stroke** **25**:472–475, 1997 (Jpn)
12. Mizutani T, Aruga T, Kirino T, et al: Recurrent subarachnoid hemorrhage from untreated ruptured vertebrobasilar dissecting aneurysms. **Neurosurgery** **36**:905–913, 1995
13. Sasaki O, Koike T, Takeuchi S, et al: Serial angiography in a spontaneous dissecting anterior cerebral artery aneurysm. **Surg Neurol** **36**:49–53, 1991
14. Sasaki O, Koike T, Tanaka R, et al: Subarachnoid hemorrhage from a dissecting aneurysm of the middle cerebral artery. Case report. **J Neurosurg** **74**:504–507, 1991
15. Tajima K, Nishioka H, Sato T, et al: [A case of dissecting aneurysm of the anterior cerebral artery presenting subarachnoid hemorrhage.] **Tokyo Ishikai Zasshi** **41**:74–75, 1988 (Jpn)
16. Terai S, Matsubara T: [A case of dissecting aneurysm involving solely anterior cerebral artery.] **Jpn J Stroke** **13**:159–164, 1991 (Jpn)
17. Yamamoto H, Fukuda O, Saito T, et al: [A subarachnoid hemorrhage secondary to a dissecting aneurysm of the anterior cerebral artery: a case report.] **Jpn J Neurosurg** **7**:310–314, 1998 (Jpn)
18. Yamaura A, Watanabe Y, Saeki N: Dissecting aneurysms of the intracranial vertebral artery. **J Neurosurg** **72**:183–188, 1990
19. Yano H, Sawada M, Shinoda J, et al: Ruptured dissecting aneurysm of the peripheral anterior cerebral artery—case report. **Neurol Med Chir** **35**:450–453, 1995
20. Yasui T, Sakamoto H, Kishi H, et al: Bilateral dissecting aneurysms of the vertebral arteries resulting in subarachnoid hemorrhage: case report. **Neurosurgery** **42**:162–165, 1998
21. Yasukawa K, Kamijo Y, Momose G, et al: [A case of anterior cerebral artery dissecting aneurysm presenting subarachnoid hemorrhage and cerebral infarction at the same time.] **Surg Cereb Stroke** **21**:461–466, 1993 (Jpn)
22. Yonas H, Agamanolis D, Takaoka Y, et al: Dissecting intracranial aneurysms. **Surg Neurol** **8**:407–415, 1977
23. Yoshimoto Y, Wakai S: Unruptured intracranial vertebral artery dissection. Clinical course and serial radiographic imagings. **Stroke** **28**:370–374, 1997

Manuscript received September 28, 1998.

Accepted in final form May 19, 1999.

Address reprint requests to: Kenichi Amagasaki, M.D., Department of Neurosurgery, Yamanashi Medical University, 1110 Shimokato Tamaho-cho, Nakakoma-gun, Yamanashi 409-3898, Japan.