

An Adolescent With Complicated Migraine

Galen N. Breningstall

During an evaluation for complicated migraine, a 14-year-old adolescent female was found to have a left frontoparietal cortical infarction on magnetic resonance imaging study. A transthoracic echocardiogram was normal, but a transesophageal echocardiogram, with contrast study, showed occasional right to left shunting through a patent foramen ovale. The role of cardiac anomalies in the pathogenesis of migraine-associated stroke is discussed.

Copyright © 1999 by W.B. Saunders Company

CASE

A 14-year-old right-handed adolescent girl presented for evaluation of headaches. She had first begun to experience headaches 2 years earlier. Her headaches had been occurring approximately monthly until 6 months before her assessment, when some increase in frequency seemed to correlate with significant difficulties in peer relationships she was experiencing at school. The patient would see scotomata 5 to 30 minutes before a headache occurred. The head pain would be temporal or occipital in locale. The patient had a difficult time characterizing the head pain. Headache was sufficiently intense to cause her to lie down. With a headache, the patient experienced dysesthesia or numbness, generally involving the right upper extremity. She had been noted at the time of headache to have an unequal grasp, with weakness on the right and a lack of dexterity in the right hand. Although the patient complained of abdominal discomfort with a headache, neither nausea nor vomiting occurred. Attempts to treat the headaches with acetaminophen and ibuprofen were generally unsuccessful. Sleep usually relieved the patient's headaches. The patient had no history of motion sickness.

The patient's mother experienced migraine headaches treated with amitriptyline. In addition, the patient's father and two paternal aunts and a paternal uncle were reported to have migraine headaches.

The patient was the product of an uncomplicated term gestation pregnancy. As a neonate, the patient experienced left Erb's palsy, which resolved without intervention. The patient had no significant antecedent medical history. When the patient was in second grade, she was noted to experience mood swings. She seemed to be using physical complaints to avoid components of her school program, reporting frequent headaches and stomach aches. She received a psychology evaluation, followed by an interval of counseling. The patient had reportedly been sexually abused at around 4 years of age by two neighbor children. The patient had two brothers in good health. The patient was in seventh grade. She was experiencing significant difficulties with peer relationships. She was also having greater academic difficulty, making C to F as opposed to her prior B-average grades.

On physical examination her blood pressure was 118/66. Examination of the ears and throat was normal. The neck was supple without adenopathy. There was no cardiac murmur. The lungs were clear to auscultation. Neurological examination found the patient to be alert, fluent, and cooperative. Cranial nerve examination revealed no focal deficits. Funduscopic examination showed sharp optic discs with spontaneous vascular venous pulsations. The deep tendon reflexes were normoactive and symmetrical in the upper and lower extremities. There was no clonus at the ankles. Appendicular motor tone and strength were normal and symmetrical in the upper and lower

extremities. There was no drift or adventitious movement of the outstretched arms. Fine finger and rapid alternating movements were acceptably performed. There was no dysmetria. There was no evident sensory deficit. Gait was narrow based and non-taxic. Tandem walking was well performed. Romberg's test was negative. There was no scoliosis.

The patient was assessed as having a history of classical migraine headaches. Because numerous headaches had been associated with right hemibody disturbance, including numbness and weakness or lack of dexterity, which might persist for an interval of time, arrangements were made for a cranial MRI to be obtained on the patient.

The cranial MRI on the patient (Fig 1) demonstrated a probable small cortical infarct in the left frontoparietal region. Subsequently, MR spectroscopy was performed showing alterations consistent with ischemia or infarction in the left subcortical region of interest. A bilateral carotid and left vertebral angiogram was normal. Prothrombin time was 11.2 seconds and partial thromboplastin time 36.1 seconds. The platelet count was 207,000. Erythrocyte sedimentation rate was 2, C-reactive protein was 0.4, and FANA was less than 1:40. Anticardiolipin antibodies were negative. A transthoracic echocardiogram was normal. Subsequently, a transesophageal echocardiogram was performed. There was thinning of the atrial septum in the area of the foramen, with slight bowing of this thin flap valve left to right. With color Doppler interrogation, there was evidence for left to right shunt through the superior aspect of the patent foramen. Pulse width Doppler also confirmed left to right shunt in this area. A contrast injection of agitated saline showed substantial appearance of contrast bubbles on the left side of the heart in four cardiac cycles. On a repeat injection, there was no significant right to left shunt present. However, when the patient performed a valsalva maneuver, there was significant opacification of the left heart due to right to left shunting. There was no abnormality of the left atrial appendage.

Cardiac consultation was obtained. No abnormality on routine cardiac examination was present. Closure of the patent foramen ovale was recommended. Although a transcatheter closure was considered, suture closure through a median sternotomy was performed due to the patient's desire to have the most expedient procedure performed. Inspection of the atrial

From the Department of Pediatrics (Neurology), Park Nicollet Medical Center, Minneapolis, MN.

Address reprint requests to Galen N. Breningstall, MD, Pediatric Subspecialties, Park Nicollet Medical Center, 910 East 26th St, Suite 325, Minneapolis, MN 55404.

*Copyright © 1999 by W.B. Saunders Company
1071-9091/99/0603-0009\$10.00/0*

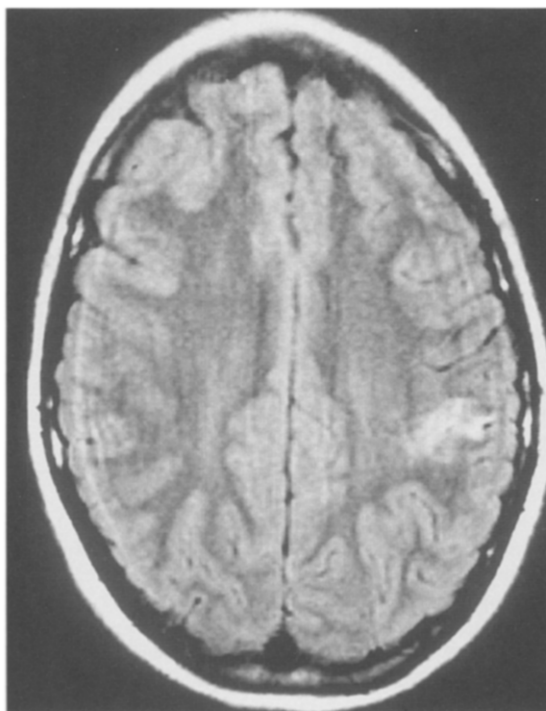


Fig 1. A T2-weighted MRI just above the level of the lateral ventricles. There is a 2 × 2-cm subcortical area of increased T2 signal in the left frontoparietal region.

septum revealed thinning of the fossa ovalis, with a patent foramen that was actually stretched to create a persistent 5- or 6-mm atrial septal defect.

After more than 1 year, the patient continued to experience significant headache on a weekly basis. However, dysesthesia, weakness, or clumsiness of the right upper extremity no longer accompanied the headache. A repeat cranial MRI showed subtle encephalomalacia in the left frontoparietal region. No new lesion was present. Ibuprofen and acetaminophen continued to be used. The patient complained of aching chest pain at the sternotomy site. She received psychiatric and psychologic care. She was prescribed paroxetine and trazodone.

DISCUSSION

During the course of an evaluation for presumptive migraine headaches, complicated by right upper extremity dysesthesia, weakness, and clumsiness, this patient was discovered to have a small cortical infarct in the left frontoparietal region. (Aside from Chiari I malformations and arachnoid cysts deemed unrelated to the presenting complaint, this is the only cerebral imaging abnormality of significance this author has documented on a patient presenting with complaint of headache and having a normal neurological examination in 14

years of active practice.) Subsequent laboratory investigation showed this patient to have a patent foramen ovale (PFO) with intermittent right to left shunting. This abnormality was demonstrated on a transesophageal echocardiogram. Contrast echocardiography was required to demonstrate right to left shunting. A transthoracic echocardiogram had demonstrated no abnormality.

An exceptionally high prevalence of patent foramen ovale or clinically silent atrial septal defect has been described in young adults with unexplained stroke.^{1,2} However, 10% to 18% of persons in the general population have a physiological PFO. Accordingly, management of a patient with unexplained stroke, PFO, and no other identifiable causes of cerebral ischemia remains controversial because the natural history of recurrent emboli in these patients is unknown.³ The cardiologist evaluating this patient, although conceding that complicated migraine might be a cause for the patient's intermittent right upper extremity dysesthesia, weakness, and clumsiness, recommended closure of the atrial communication. Whereas noninvasive technology is available to accomplish this, the patient's parents desired that the most expedient procedure be performed.

Migraine-associated stroke is an alternative explanation for our patient's small cortical infarction. Of 22 patients with acute-migraine associated stroke prospectively evaluated in one series, 91% were female.⁴ Seventy-three percent of these patients suffered permanent neurological deficit and 1 patient (5%) died. Transthoracic echocardiography, performed on 16 patients, revealed 1 with mitral valve prolapse. In another series involving record review, 80% of patients were female.⁵ Seventy percent of these patients had a mild to minimal persisting deficit and 10% a moderate deficit. In a third perspective series, 77% of patients were female.⁶ Transthoracic echocardiography documented mitral valve prolapse in 9%.

Patients with migraine do exhibit a chronic increase in platelet aggregability that, along with plasma coagulability, may increase during acute migraine attacks. This could predispose to thrombus formation, with consequent stroke from primary arterial occlusion or embolization. Aggravation of this inherent tendency by extrinsic factors (eg, oral contraceptive use; cigarette smoking,

alcohol abuse, or sympathomimetic drug abuse) or a combination of coexisting intrinsic conditions (eg, mitral valve prolapse) may facilitate stroke.⁴ No evident extrinsic factors were involved in our patient's presentation. Possibly, the PFO was an intrinsic factor promoting migraine-related stroke.

It is difficult to know what benefit our patient

achieved from surgery. She continues to experience severe headaches, albeit unassociated with right upper extremity dysesthesia or weakness. Repeat cerebral imaging demonstrated resolution of the original lesion and no new lesion. Our patient now perceives chronic pain at the sternotomy site. She remains an emotionally troubled individual.

REFERENCES

1. Lechat P, Mas JL, Lascault G, et al: Prevalence of patent foramen ovale in patients with stroke. *N Engl J Med* 318:1148-1152, 1988
2. Webster MW, Smith HJ, Sharpe DN, et al: Patent foramen ovale in young stroke patients. *Lancet* 2:11-12, 1988
3. DeRook FA, Comess KA, Albers GW, et al: Transesophageal echocardiography in the evaluation of stroke. *Ann Intern Med* 117:922-932, 1992
4. Rothrock JF, Walicke P, Swenson MR, et al: Migrainous stroke. *Arch Neurol* 45:63-67, 1988
5. Broderick JP, Swanson JW: Migraine-related strokes: Clinical profile and prognosis in 20 patients. *Arch Neurol* 44:868-871, 1987
6. Bogousslavsky J, Regli F, Van Melle G, et al: Migraine stroke. *Neurology* 38:223-227, 1988

COMMENTARY

Between 1% and 10% of men and 5% and 25% of women experience migrainous phenomenon each year in the United States. An aura is present in approximately 30% of persons with migraine, whereas "complicated migraine" is estimated to occur in up to 4% of persons with migraine. Although the precise pathogenic mechanism remains unclear, "complicated migraine" is thought to be causative in up to 30% of young adults (ages 15 to 50 years) with ischemic stroke. The International Headache Society defines "complicated migraine" or migraine-induced stroke as: the patient who previously fulfilled criteria for a diagnosis of migraine with aura; the presenting attack is typical of previous attacks with the neurological deficit not completely reversed within 7 days and/or the demonstration of ischemic infarction in relevant areas on neuroimaging; and that other causes of infarction have been ruled out by appropriate investigation.

Did Dr. Breningstall's patient have migraine with aura and, independently, transient ischemic attacks (TIAs), which culminated in a small cortical ischemic infarction? Were his patient's events migrainous or ischemic?

The differential diagnosis for episodes of transient neurological dysfunction includes TIAs, migraine with aura, focal epileptic seizures, hypoglycemia or hyperglycemia, demyelinating disorders, vestibulopathies, transient tumor attacks, and transient subdural attacks. Migraine with aura and TIAs, which may at times be very difficult to

differentiate, remain the most common reasons for transient neurological events. The onset of a TIA is usually abrupt and typically unprovoked. TIA symptoms are "negative" phenomena, such as losing power in one limb, vision in one eye, speech, or sensation in one limb.

However, in young adults, temporal onset and duration of symptoms may be especially atypical or the patient may be unsure or uncertain of the sequence, making the distinction between TIA and migraine with aura particularly difficult. Headache, the hallmark feature of migraine, may be present in 20% to 30% of patients with stroke/TIA.

Although Dr. Breningstall's patient had only transient focal neurological symptoms and signs, her neuroimaging data showed a small cortical stroke. Available data indicate a very low rate of intracranial pathology in patients with migraine and a very low rate of specific pathology in patients with headaches in general when their neurological examination is normal.^{1,2} The Quality Standards Subcommittee of the American Academy of Neurology recommends that in adult patients with recurrent headaches defined as migraine, including those with visual aura, without recent change in pattern of headache and in the absence of a history of seizures, or focal neurological signs or symptoms, the routine use of neuroimaging is not warranted.^{1,3} Patients with atypical headache patterns, a history of seizures, or focal neurological signs or symptoms, as in this case, CT or MRI may be indicated.¹

The mechanisms by which the risk of stroke is

increased or enhanced by the presence of migraine remains unclear. In fact, whether the mechanism or mechanisms responsible for migraine with aura is also causally related to the development of stroke or whether migrainous phenomena serve as a marker of increased risk of stroke unrelated to the migrainous attacks is still unknown.⁴

Dr. Breningstall carefully asks whether his patient had any benefit from cardiac surgery, paralleling the great controversy concerning whether patent foramen ovale are causative of strokes or TIAs and, if so, the best fashion in which to prevent strokes or TIAs in these patients. Were this patients' migraines, especially when they were occurring monthly, menstrually related? Were her other coagu-

lopathic markers, such as lupus anticoagulant, protein S, protein C, activated protein C resistance (Leiden factor V), and antithrombin III levels normal? Were other abortive antimigrainous medications prescribed or effective? Were preventive antimigrainous medications prescribed or effective? The adult neurologist who inherits this patient's care faces a challenging task indeed.

Ross L. Levine, MD
Associate Professor of Neurology,
Radiology, and Kinesiology
University of Wisconsin Medical School
Stroke Program, Board of Directors
Madison, WI

REFERENCES

1. Frishberg BM: The utility of neuroimaging in the evaluation of headache in patients with normal neurologic examinations. *Neurology* 44:1191-1197, 1994
2. Schulman EA, Young WB, Silberstein SD: Investigating headache. *The Neurologist* 2:66-72, 1996
3. Report of the Quality Standards Subcommittee of the American Academy of Neurology: Practice parameter: The utility of neuroimaging in the evaluation of headache in patients with normal neurologic examinations. *Neurology* 44:1353-1354, 1994
4. Buring JE, Herbert P, Romero J, et al: Migraine and subsequent risk of stroke in the Physician's Health Study. *Arch Neurol* 52:129-134, 1995