

Dissection of the Middle Cerebral Artery Caused by Invasion of Malignant Glioma Presenting as Acute Onset of Hemiplegia

N. Aoki¹, T. Sakai¹, A. Oikawa¹, T. Takizawa², and M. Koike³

¹ Department of Neurosurgery, Tokyo Metropolitan Ohkubo Hospital, Tokyo, Japan

² Department of Pathology, Tokyo Metropolitan Ohkubo Hospital, Tokyo, Japan

³ Department of Pathology, Tokyo Metropolitan Komagome Hospital, Tokyo, Japan

Summary

A 57-year-old, previously healthy man who developed acute onset of hemiplegia is presented. Neuro-imaging studies on admission suggested dissection of the middle cerebral artery producing infarction in the frontotemporal region. In contrast to his stable clinical course, serial neuro-imaging studies disclosed rapid growth of malignant glioma, which was confirmed at surgery. Microscopic examination of the surgical specimen demonstrated invasion of glioma cells into the arterial wall associated with intramural haematoma formation of the middle cerebral artery. This case is the first to document dissection of an intracranial artery caused by invasion of tumour cells.

Keywords: Cerebral infarction; malignant glioma; vascular dissection.

Introduction

Acute onset of neurological manifestations have been known to be caused by intracranial haemorrhage associated with brain tumours [7]. In contrast to this relatively frequent phenomenon, brain tumours have been rarely reported to cause development of cerebral infarction. Most physicians do not seem to consider brain tumours as an aetiology of cerebral infarction. Recently, authors encountered a patient presenting with acute onset of hemiplegia which was considered to be secondary to dissection of the middle cerebral artery on the initial carotid angiograms. Follow-up neuro-imaging studies, however, disclosed a rapidly growing tumour. Microscopical examination of the surgical specimen demonstrated invasion by glioma cells of the arterial wall associated with intramural haematoma. This is the first report to document tumour-related dissection which was histologically

verified; the details of the clinical course, neuro-imaging and pathological findings are described.

Case Report

A 57-year-old man without significant past history developed sudden onset of gait disturbance while fishing at 1 pm, on June 14, 1997. He was brought to a nearby hospital by ambulance, where hemiplegia on the left side and dysarthria were noted. Computed tomography (CT) scanning at the hospital was reported to reveal a low-density area in the right frontotemporal region, leading to a diagnosis of cerebral infarction. For residential reasons, the patient was transferred to the Department of Neurosurgery, Tokyo Metropolitan Ohkubo hospital on June 30 (16 days after the onset).

Examination. On arrival, his neurological examination revealed hemiplegia and hemihypaesthesia on the left side, and mild dysarthria. Results of laboratory and cardiovascular check-up were normal. T1 weighted magnetic resonance (MR) imaging showed discrete periventricular low-intensity lesions and diffuse low intensity in the frontotemporal region (Fig. 1). No effacement of the lateral ventricles was observed. Enhanced MR studies were not performed at that time. Carotid angiography on the right side revealed dilatation of the middle cerebral artery associated with stenosis at its proximal and distal portion, suggesting the possibility of arterial dissection (Fig. 2).

Clinical course. After admission, he was treated by the administration of 200 mg of ticlopidine per day and rehabilitation, resulting in a mild degree of improvement of his neurological deficit. On August 23, he was transferred to another institute for further rehabilitation. On September 13, however, he was readmitted to our hospital because a brain tumour was detected on CT scanning performed as a routine admission examination at the referral institute. At the time of readmission, his neurological status was improving. T1 weighted MR images revealed a remarkable mass effect and a well enhanced mass lesion in the right frontotemporal region (Fig. 3). Right carotid angiography showed pronounced vascular "stain," suggesting malignant glioma (Fig. 4).

Operation. The patient underwent subtotal removal of the tumour via right frontotemporal craniotomy. Massive haemorrhage from the main trunk of the middle cerebral artery embedded in the tumour

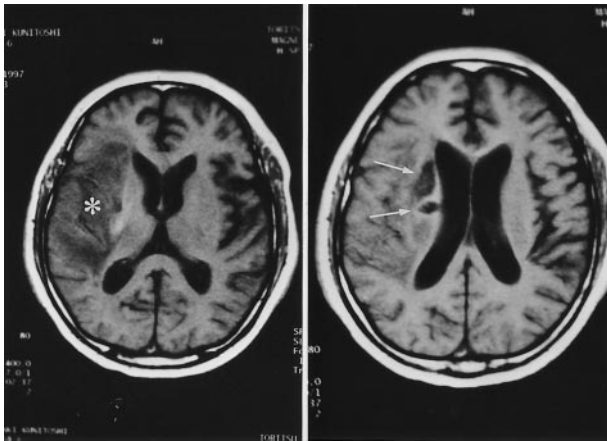


Fig. 1. T1 weighted magnetic resonance images on admission, showing diffuse low intensity (asterisk) in the right frontotemporal region (a), and discrete low intensity (arrows) in the periventricular regions (b)

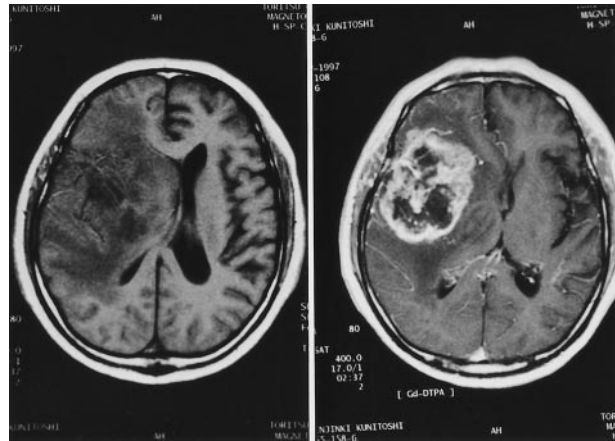


Fig. 3. T1 weighted magnetic resonance images on readmission, delineating remarkable mass effect (a), without gadolinium, and a well enhanced mass lesion (b) with gadolinium, in the right frontotemporal region

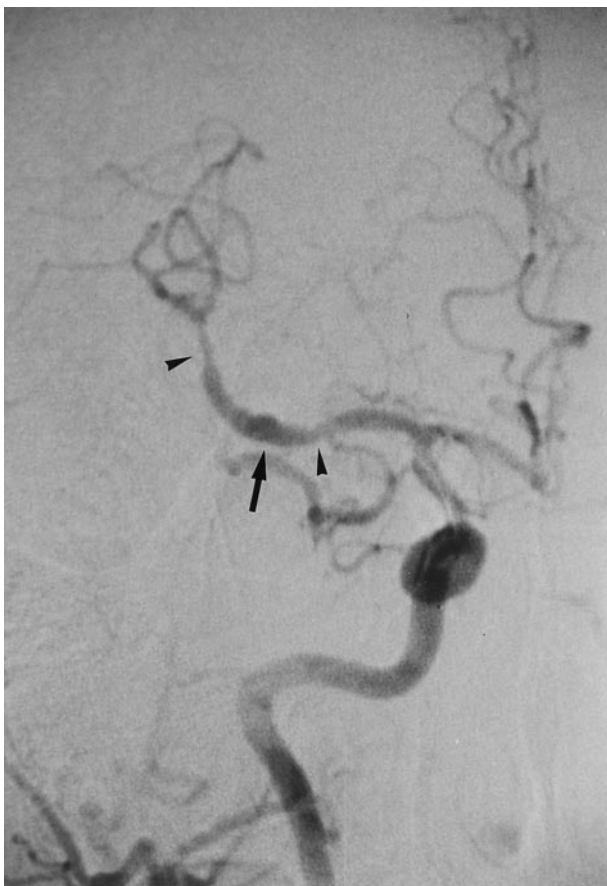

Fig. 2. Right carotid angiogram on admission, anteroposterior view revealing dilatation (arrow) with stenosis at its proximal and distal portion (arrowheads) of the middle cerebral artery suggestive of dissection

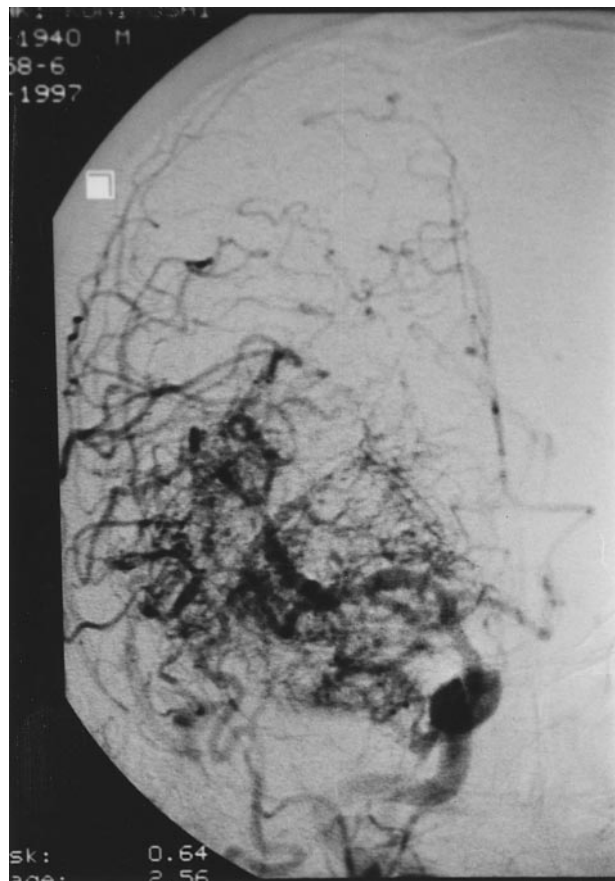


Fig. 4. Right carotid angiogram on readmission, anteroposterior view revealing dense vascular "stain"

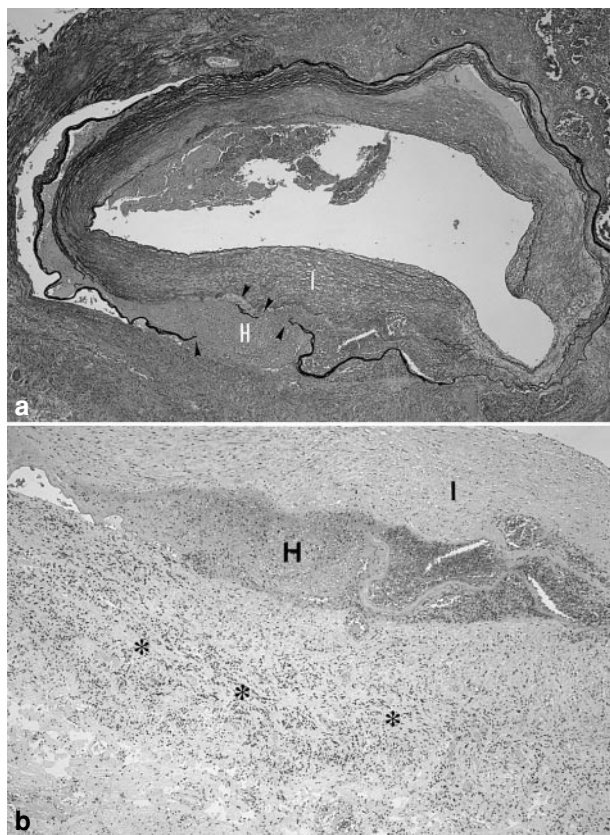


Fig. 5. Photomicrographs of a section through the middle cerebral artery. (a) Disruption of the internal elastic lamina (arrowheads) and haematoma formation between the thick intima and the muscle layer. Elastica van Gieson stain, original magnification $\times 40$. (b) Invasion of glioblastoma multiforme (asterisks) in the muscle layer. H & E stain, original magnification $\times 60$. I Thick intima; H haematoma formation.

was encountered at the final stage of surgery. Haemostasis was achieved only after sacrificing the first segment of the middle cerebral artery by clipping with titanium haemoclips.

Microscopic examination. Surgical specimen was reported to be typical of glioblastoma multiforme, which invaded the muscle layer of the middle cerebral artery. In addition, disruption of the internal elastic lamina associated with haematoma formation between the muscle layer and the thick intima indicating arterial dissection was demonstrated (Fig. 5).

Postoperative course. His postoperative course was complicated by transient disturbance of consciousness due to brain oedema. He recovered to his preoperative status two weeks later, and received 50 Gy of radiation therapy. No recurrence was observed 6 months after the operation, at the time writing.

Discussion

Based on the clinical course presenting as acute onset of hemiplegia together with the presence of periventricular old infarctions, the low-intensity area in

the right frontotemporal region on the initial MR imaging in this patient was considered to represent cerebral infarction. The diagnosis was supported by angiographic features showing dilatation associated with proximal and distal stenosis which is usually seen in dissection. Moreover, he showed neurological improvement during 3-months of hospitalization; this clinical course also made it difficult for the authors to recognize the presence of a brain tumour. Intracranial vascular impairment has been known to be most commonly caused by meningioma which can produce stenosis or occlusion of the internal carotid artery [2, 9, 11]. The mechanism is proposed to be direct vascular compression and/or arterial encasement by the tumour. Whereas meningioma-related vasculopathy is usually slowly progressive or asymptomatic, recent reports revealed that glioma can present as acute onset of hemiparesis as in the present patient [4, 12]. In these reports, however, the mechanism of acute onset of neurological presentation is not clarified pathologically. Glioma, though very rare, is reported to invade vascular walls, resulting in dilatation or rupture of the major arteries [1, 5, 8]. The present patient is also histologically verified to have vascular invasion by glioma cells; however, there have been no reports which document dissection of an intracranial artery secondary to tumour invasion. Recently dissection of the middle cerebral artery is sporadically published [3, 6, 10], but its a etiology remains unelucidated. In this respect, it is worthwhile to keep in mind that glioma may induce dissection of intracranial arteries.

Conclusion. The importance of this report is two-fold; intracranial glioma may manifest as cerebral infarction, and dissection of a major intracranial artery can be induced by direct invasion by glioma cells.

References

1. Cowen RD, Siquiera ED, Gerges E, Richard L, Edir B (1970) Angiographic demonstration of a glioma invading wall of anterior cerebral artery: report of a case. *Radiology* 97: 573–578
2. Daly DD, Svien HJ, Yoss RE (1961) Intermittent cerebral symptoms with meningiomas. *Arch Neurol* 5: 287–293
3. Fu Y, Komiyama M, Inoue T, Ohtaka K, Matsuoka Y, Hakuba A (1996) A case of middle cerebral artery occlusion caused by dissecting aneurysm. *No Shinkei Geka* 24: 955–959 (in Japanese)
4. Fisher M, Recht LD (1989) Brain tumor presenting as an acute pure motor hemiparesis. *Stroke* 20: 288–291
5. Hart MN, Byer JA (1974) Rupture of middle cerebral artery branches by invasive astrocytoma. *Neurology (Minneapolis)* 24: 1171–1174
6. Kawaguchi T, Kohno T, Kazekawa K, Honma T, Kaneko Y, Koizumi T, Dousaka Y (1977) Dissecting aneurysm of the mid-

- dle cerebral artery with subarachnoid hemorrhage and brain infarction: a case report. *No Shinkei Geka* 25: 1033–1037 (in Japanese)
7. Kondziolka D, Berstein M, Resh L, Tator CH, Fleming JFR, Vanderlinden RG, Schutz H (1987) Significance of hemorrhage into brain tumors: clinicopathological study. *J Neurosurg* 67: 852–857
 8. Kung PC, Lee JC, Bakay L (1969) Vascular invasion by glioma cells in man: an electron microscopic study. *J Neurosurg* 31: 339–345
 9. Launay M, Fredy D, Merland JJ, Bovies J (1979) Narrowing and occlusion of arteries by intracranial tumors. Review of the literature and report of 25 cases. *Neuroradiology* 14: 117–126
 10. Piepgras DG, McGrail KM, Tazelaar HD (1994) Intracranial dissection of the distal middle cerebral artery as uncommon cause of distal cerebral artery aneurysm. *J Neurosurg* 80: 909–913
 11. Spallone A (1981) Occlusion of the internal carotid artery by intracranial tumors. *Surg Neurol* 15: 51–57
 12. Yamaki T, Nonaka T, Akiyama K, Tanaka S, Hashi K (1997) Supratentorial glioma manifesting as acute onset of pure motor hemiparesis: case report. *Neurol Med Chir (Tokyo)* 37: 422–425

Comments

The authors should be commended for a very important, well designed and presented case of invasion of glioma cells into the arterial wall causing intramural haematoma in the MCA.

The case is well documented from the first manifestation of the symptoms and signs with the initial MRI, and in addition also by angiography which presented already at that time the changes in the caliber of the MCA. At the readmission the repeated MRI revealed a rapid progress of the lesion, as demonstrated also by angiography, which at the same time showed more pronounced changes (stenosis and dilatation) of the MCA.

This report does carry the important message that disruption of the artery wall may occur in GBM tumours because of the infiltration by tumour cells of the artery wall, thus destroying it. A formation of intramural haematoma may then lead to well known complications in the dissection along the individual layers of the artery wall; occlusion of the artery or rupture of the artery wall.

V. Dolenc

Correspondence: N. Aoki, M.D., Department of Neurosurgery, Tokyo Metropolitan Ohkubo Hospital, 22-1, Kabukicho 2-chome, Shinjuku-ku, Tokyo 160-8488, Japan.