

Variants of Congenital Ocular Motor Apraxia: Associations With Hydrocephalus, Pontocerebellar Tumor, and a Deficit of Vertical Saccades

Irene Anteby, MD,^a Benjamin Lee, MD,^b Michael Noetzel, MD,^c and Lawrence Tychsen, MD^a

Background: Congenital ocular motor apraxia (COMA) is characterized by the inability to generate volitional horizontal saccadic eye movements in the absence of other focal neurologic abnormalities. **Subjects:** We report on two children (ages 5 months and 3 years) whose COMA did not adhere to these classic criteria. The children were followed up clinically with serial ocular motor examinations and neuroimaging over a period of 3 years. **Results:** In the first child horizontal COMA was associated initially with neonatal communicating hydrocephalus. Two and one half years after the first signs of COMA, a fourth ventricle medulloblastoma appeared. The second child, who recovered from a periventricular hemorrhage caused by perinatal asphyxia, manifested vertical COMA and compensatory vertical head thrusts. **Conclusions:** COMA may be associated with hydrocephalus, pontocerebellar tumor, and periventricular hemorrhage. These rare variants of COMA emphasize that the eye movement deficits may arise from several locations, cerebral as well as pontocerebellar, in the neuronal pathways generating saccades. (J AAPOS 1997;1:201-8)

Congenital ocular motor apraxia (COMA) is characterized by the inability to generate voluntary saccadic eye movements. Reflexly induced saccades and quick phases of vestibular nystagmus are relatively preserved.¹⁻⁴ In classic cases of COMA the saccadic deficit is horizontal, whereas vertical saccades are normal. The disorder is typically recognized at the age of 5 to 6 months when the infant acquires head and neck control, manifested by head thrusts to substitute for the inability to make saccades.¹ The etiology and pathogenesis of COMA is currently unknown. Brain stem tumors,⁵⁻⁷ cerebellar abnormalities,^{8, 9} and hypoplasia or agenesis of the corpus callosum^{8, 10, 11} have been reported rarely in association with COMA.

We describe two children with COMA, one of whom had an atypical clinical course and the other atypical

clinical signs. In the first case horizontal COMA was associated with neonatal communicating hydrocephalus followed years later by the appearance of a fourth ventricle neoplasm. In the second case a child who had a cerebral periventricular hemorrhage from birth asphyxia manifested a rare form of persistent vertical COMA.

REPORT OF CASES

Case 1

A 5-month-old male infant was referred to our unit for suspected poor vision. His mother noted that he was unable to follow moving targets but did smile when she placed herself directly in his line of sight. The infant, a twin, was delivered at a gestational age of 37 weeks by cesarean section, which was prompted by preeclampsia. The child's birth weight was 3990 gm. Routine neonatal examination documented a head circumference above the 95th percentile. A head computed tomographic (CT) scan was performed (Figure 1), which revealed communicating hydrocephalus. The ventricular system was slightly dilated but had otherwise normal configuration. There was no evidence of a mass lesion. Because of progressively increasing head circumference (46.5 cm), a ventriculoperitoneal shunt was placed by the pediatric neurosurgery service when the patient was 3 months old. Repeat CT scans showed a functioning shunt and normal head growth.

From the Department of Ophthalmology and Visual Sciences,^a the Mallinckrodt Institute of Radiology,^b and the Department of Neurology,^c St. Louis Children's Hospital, Washington University School of Medicine, St. Louis, Missouri.

Supported by National Institutes of Health program project grant No. 01 NS 17763-12 (L.T.), National Institutes of Health grant No. R01 EY10214-01A3 (L.T.), a McDonnell Center for Higher Brain Function Research Grant (L.A.), Knights Templar Eye Foundation Research Grant (L.A.), and in part by National Institutes of Health grant No. EY02687 and an unrestricted grant to the Department of Ophthalmology and Visual Sciences from Research to Prevent Blindness, Inc.

Reprint requests: L. Tychsen, MD, St. Louis Children's Hospital, Washington University School of Medicine, One Children's Place, Room 2 South 89, St. Louis, MO 63110. Copyright © 1997 by the American Association for Pediatric Ophthalmology and Strabismus. 1091-8531/97 \$5.00 + 0 7511/84884

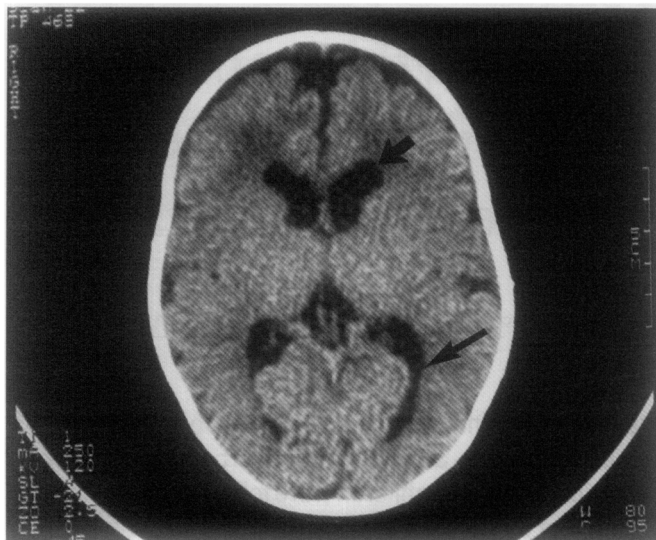


FIG. 1. CT scan of child No. 1 at age of 2.5 months showing mildly dilated frontal (*short arrow*) and occipital horns (*longer arrow*) of lateral ventricles. Child had unusually large head circumference. CT supported diagnosis of communicating hydrocephalus.

Examination in our unit 2 months after the shunt procedure revealed that the infant fixated well with each eye but could not initiate voluntary saccadic eye movements to fixate on a novel target presented at an eccentric location along the horizontal plane. Vertical saccades appeared clinically to be of normal latency, amplitude, and velocity. The fast phases of small-field optokinetic nystagmus (OKN), induced by a hand-held drum, were infrequent in the horizontal plane but normal vertically. When the vestibuloocular reflex was evoked by whole-body rotation, fast phases were deficient so that the eyes tended to remain deviated at the extreme edges of the orbits (e.g., to the right edge of each orbit as the child's head rotated to the left). Versions evoked by head rotation were normal. The infant was orthotropic and made normal convergence and divergence eye movements. The visual field was fully intact, as evidenced by the fact that the infant made head thrusts to acquire targets in all visual field quadrants. Pupillomotor and fundoscopic examinations were normal. A diagnosis of COMA was made.

A follow-up examination at age 2 years documented improvement in the initiation of horizontal voluntary saccades. Horizontal small-field optokinetic nystagmus was normal with no nasotemporal asymmetry under conditions of monocular viewing.¹² Visual field testing with use of the evoked-saccade method,¹³ pupillomotor examination, and fundoscopic examinations again had normal results. General motor development was considered by the parents to be slightly delayed compared with that of the normal twin brother. Language skills were appropriate. Follow-up examinations in the pediatric

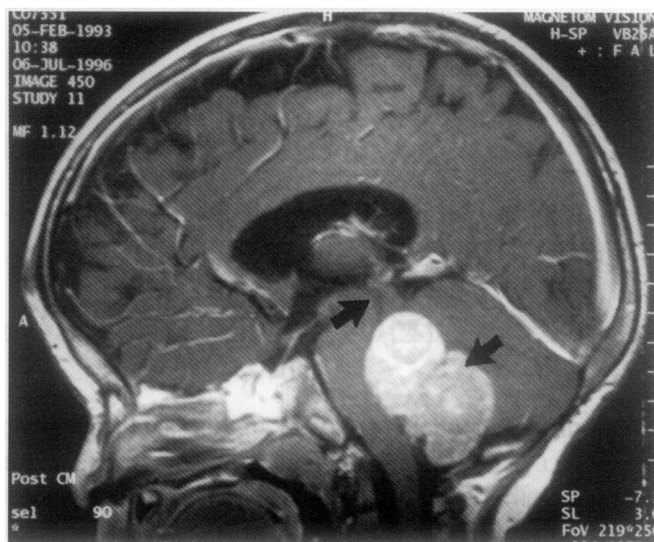


FIG. 2. Sagittal T1-weighted MRI after infusion of gadolinium showing large, intensely enhancing tumor within fourth ventricle compressing pons and ventral part of cerebellum (*bottom arrow*). Cerebral aqueduct (*top arrow*) is dilated slightly.

neurosurgery unit had revealed no evidence of shunt malfunction. Follow-up magnetic resonance imaging (MRI), performed at age 2 years, showed no intracranial abnormality.

At the age of 3 years (i.e., 2.5 years after the initial diagnosis of COMA), the patient was admitted to the pediatric neurology service for sudden onset of ataxic gait causing frequent falls. MRI of the brain showed a 4.3×3.8 cm posterior fossa mass occupying and enlarging the fourth ventricle (Figure 2). The mass displaced the pons anteriorly and compressed the ventral cerebellum. A smaller second mass lesion was present in the cerebellar tonsils. A subtotal resection of the tumor was performed through an infratentorial posterior craniotomy incision. Histopathologic examination documented a medulloblastoma. The child received chemotherapy with cisplatin and etoposide followed by radiation therapy to treat cerebellar and lumbar spine metastasis. Follow-up examination 8 months after the craniotomy showed no additional eye movement deficits as a consequence of the tumor resection. The ataxia had resolved, but the ocular motor apraxia remained unchanged.

Case 2

A 3-year-old boy was referred to our unit for evaluation of abnormal head movements present since infancy. He was born in Tübingen, Germany, by a cesarean section prompted by preeclampsia at 36 weeks' gestation. The pregnancy was complicated by fetal growth retardation, diagnosed by intrauterine ultrasonography in the third trimester. The birth weight was 2060 gm. In the neonatal



FIG. 3. Typical vertical head thrust observed in child No. 2. **1,** After introduction of target in superior visual field, child's strategy is to thrust head (and orbits) upward, activating vertical slow-phase vestibuloocular reflex, which allows visual axes to be vertically realigned on target. **2,** Examiner begins to move target downward abruptly. **3,** Child initiates downward head thrust, activating upward slow phase of vestibuloocular reflex, deviating eyes upward in orbits. **4,** Child hyperflexes his head so that head deliberately overshoots target. **5,** Child raises his head slightly, now using downward slow-phase of vertical vestibuloocular reflex to achieve alignment of his visual axes on target.

TABLE 1. Reports of horizontal COMA in presence of intracranial tumors

Authors	Patient sex, age	Interval between COMA onset and diagnosis of tumor	Location of lesion	Type of lesion	Improvement of COMA after tumor excision
Zaret et al. (1980) ⁷	Male, 8 months	4 months	Cerebellar vermis, cerebral peduncle, thalamus	Small cell neoplasm	Yes
Lyle (1961) ⁶	Male, 16 months	11 months	Pons, lateral wall fourth ventricle, cerebellar hemisphere	Medulloblastoma	Yes
Summers et al. (1987) ⁵	Female, 10 months	7 months	Cerebellar hemisphere (venous sinus) and cerebellar vermis	Lipoma	No
Case No. 1	Male, 5 months	2.5 yr	Fourth ventricle, compressing pons and cerebellum	Medulloblastoma	No

period he was noted to be initially hypotonic, followed by hypertonicity. A small left hemispheric subependymal hemorrhage (attributed to perinatal asphyxia) was documented on an MRI scan obtained at age 1 month. Follow-up neurologic examination performed at age 2.5 years showed mild diplegic spastic cerebral palsy affecting gross motor functions and language skills.

On examination in our unit the mother reported that from early infancy the patient had displayed consistently unusual vertical head movements. He was unable to generate voluntary vertical saccades. To refixate a target presented in the superior or inferior visual field, the child used vertical head thrusting (Figure 3) and the

vertical vestibuloocular reflex. His strategy was to blink and flex his head forward or backward rapidly so that his head overshoot the target, evoking an upward (or downward) slow-phase vestibuloocular reflex movement. The slow-phase deviation allowed him to achieve fixation, after which he returned his orbital axis to align with the object. Fast phases of small-field and full-field vertical OKN were rare. In the horizontal plane the patient fixated and followed normally with prompt, normometric saccades and fast phases of OKN. Cover testing documented that he was orthotropic. Pupillomotor and fundoscopic examinations were normal. Visual acuity was normal (20/36 in the right eye and 20/

TABLE 2. Clinical features and birth history of children with vertical COMA

Authors	Patient age, sex	Birth, weight, gestational age	Perinatal asphyxia	Neuroimaging lesions (age)	Neurologic development
Hughes et al. (1985) ¹⁸	Male, 4.5 yr	1135 gm, 30 wk	Yes	CT: normal (1 wk and 4.5 yr)	Delayed motor development, deficit language skills
Ro et al. (1989) ¹⁹	Female, 1 yr	3200 gm, 41.5 wk	Yes	CT and MRI: normal (2 wk)	Hypotony in infancy, delayed motor development
Ebner et al. (1990) ²⁰	Male, 2.5 yr	3150 gm, not reported	Yes	CT: low-density areas on both sides of third ventricle (2.5 yr) MRI: bilateral lesions at mesencephalic-diencephalic junction (4.5 yr)	Delayed motor development
Buncic and Crawford (1985) ²¹	Female, 7 months	"Normal," term	Yes	CT and MRI: bilateral, medial thalamic lesions (7 months)	Severe memory deficit
Case No. 2	Male, 3 yr	2060 gm, 36 wk	Yes	MRI: hemispheric subependymal hemorrhage (1 month), normal (3 yr)	Mild spastic cerebral palsy deficient gross motor function and language skills

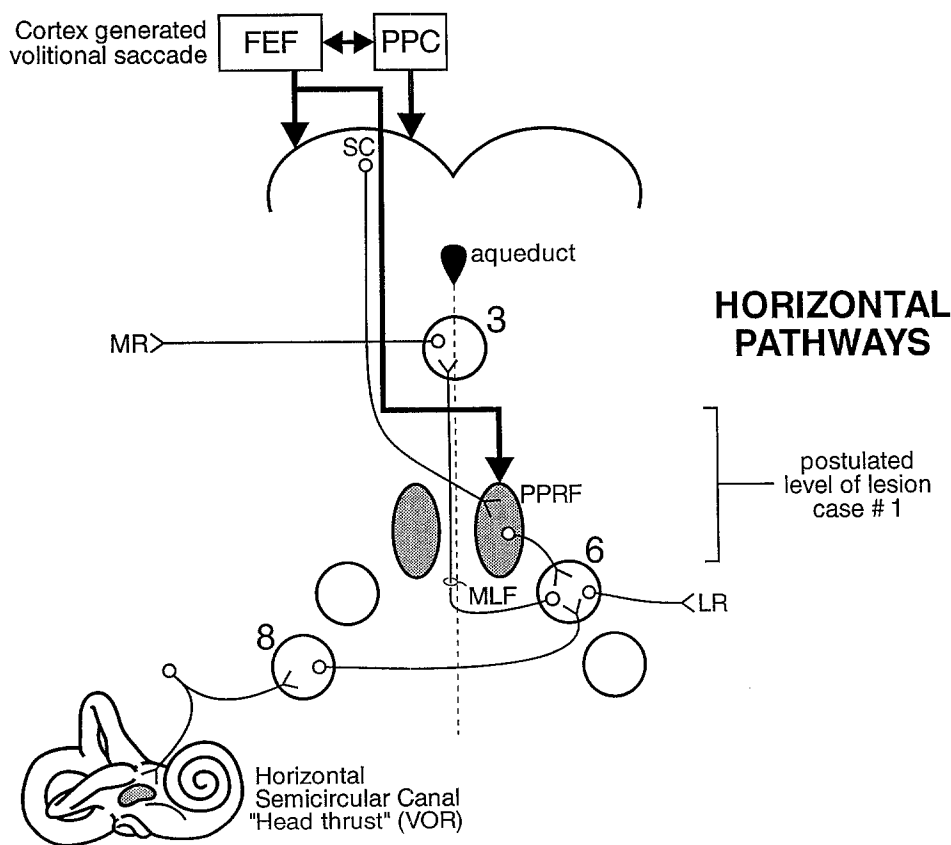


FIG. 4. Horizontal saccadic eye movement pathways in coronal view. Postulated lesion in case 1 is between level of oculomotor and abducens nuclei, involving either decussating corticopontine fibers or saccade-related neurons of pontine raphe. Generation of horizontal saccades involves activation of both posterior parietal cortex (PPC) and frontal eye field (FEF) of one cerebral hemisphere. Signals descend from both these, through the internal capsule and basal ganglia (*bold downward arrows*), to ipsilateral midbrain superior colliculus (SC), which sends projection to neurons of paramedian pontine reticular formation (PPRF) on opposite side of pons. Frontal eye field also sends parallel projection to paramedian pontine reticular formation that does not involve synapse in superior colliculus. Activation of left paramedian pontine reticular formation excites motoneurons of ipsilateral abducens nucleus (6) and interneurons, which project through medial longitudinal fasciculus (MLF) to contralateral medial rectus motoneurons in the oculomotor nucleus (3). When corticopontine pathways are impaired, as in horizontal COMA, infant learns to head thrust. Head thrusting activates neurons within semicircular canal and hence vestibuloocular reflex (VOR), generating slow-phase movements that compensate partially for saccadic deficit. MR, Medial rectus; LR, lateral rectus. Dotted line from cerebral aqueduct indicates midline. 8, Vestibular nucleus.

33 in the left eye), as documented with use of the spatial-sweep visual-evoked potential method.

Vertical COMA was diagnosed. A repeat MRI of the brain, obtained at age 3 years, revealed no sign of structural abnormality. No white matter or cortical lesion was detectable in the region of the previous neonatal subependymal hemorrhage.

DISCUSSION

Cogan¹ introduced COMA into the clinical lexicon in 1952 at the Jackson Memorial Lecture. The key features, described in four patients, included the absence of willed eye movements in the horizontal plane only and telltale, jerky overshooting of the head on fixation. None of

Cogan's patients in this report had an associated neurologic abnormality. He presumed the syndrome was congenital; its pathogenesis was obscure.

COMA and hydrocephalus

Hydrocephalus, especially of the noncommunicating type, may cause a variety of neuro-ophthalmologic manifestations in children. The motility abnormalities associated with increased intracranial pressure include the setting sun sign; the dorsal midbrain syndrome; sixth, fourth, or third nerve palsies; comitant esotropia; skew deviation; and internuclear ophthalmoplegia.¹⁴ Our case No. 1 had communicating hydrocephalus resulting from extraventricular obstruction of cerebrospinal fluid flow in associa-

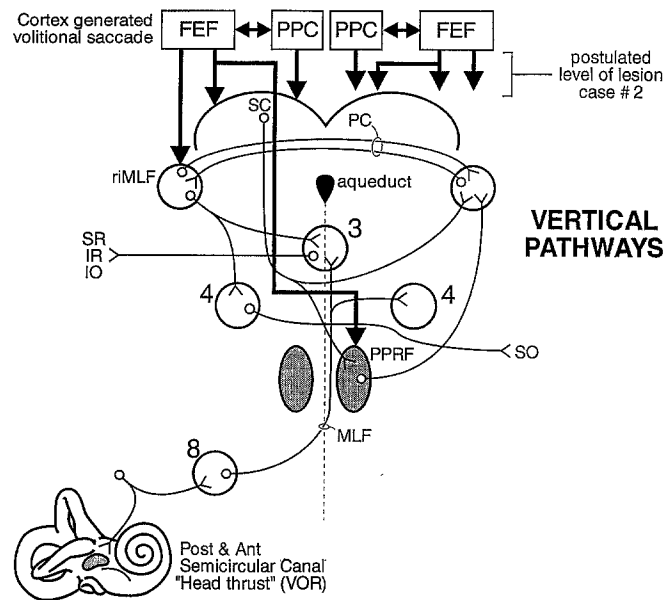


FIG. 5. Vertical saccadic eye movement pathways in coronal view. Postulated lesion in case 2 is in subcortical white matter neurons or contiguous basal ganglia. Generation of vertical saccades involves activation of posterior parietal cortex (PPC) and frontal eye field (FEF) in both cerebral hemispheres. For sake of clarity, descending projections are shown fully for only right frontal eye field and posterior parietal cortex. Both send descending projections through internal capsule and basal ganglia to midbrain and pons. Right and left rostral interstitial nucleus of medial longitudinal fasciculus (riMLF) receives projections from frontal eye field, from superior colliculus (SC) and paramedian pontine reticular formation (PPRF), and from contralateral rostral interstitial nucleus of medial longitudinal fasciculus through interconnecting fibers of posterior commissure (PC). Rostral interstitial medial longitudinal fasciculus provides signals to vertical eye muscle motoneurons in oculomotor³ and trochlear⁴ nuclei. Vertical head thrusting excites neurons within the posterior (Post) and anterior (Ant) semicircular canals, and hence the vestibuloocular reflex (VOR), generating vertical slow-phase vestibuloocular reflex movements that compensate partially for saccadic deficit. SR, Superior rectus; IR, inferior rectus; IO, inferior oblique; SO, superior oblique. Dotted line from cerebral aqueduct indicates midline. 8, Vestibular nucleus.

tion with COMA. The COMA in this infant did not resolve after the shunting procedure and subsequent control of intracranial pressure. PeBenito and Cracco¹⁵ described a case of COMA associated with noncommunicating hydrocephalus. The child they reported had congenital aqueductal stenosis, and a ventriculoperitoneal shunt was placed at age 1 month because of enlarged ventricles and multiple arachnoid cysts. The child was referred to them to rule out blindness, a common misdiagnosis in infants with COMA who are younger than age 6 months and who have poor head control.^{16,17} They established the diagnosis of COMA at age 8 months, after the onset of typical head thrusts. Follow-up beyond infancy in their case also documented motor and speech delay.

COMA and intracranial tumor

Among the six dozens of cases of COMA reported in the literature, four (listed in Table 1) have been associated with intracranial tumors (for a prevalence of ~5%).⁵⁻⁷ The tumors in each of these four cases were located in the midbrain, pons,

or cerebellum, implying a brainstem locus for the COMA. It is important to note, however, that the brainstem is the most common site of pediatric brain tumors. In our case No. 2 several years lapsed between the onset of COMA and the diagnosis of tumor. In the previous reports (see Table 1, column 3) the diagnosis of brain tumor was established 4 to 11 months after the appearance of COMA. The lag period in the cases reported by Lyle⁶ in 1961 and Zaret et al.⁷ in 1980 could be attributed in part to lack of sensitive neuroimaging techniques. In our case state-of-the-art CT and MRI scans, performed serially from age 1 month, failed to reveal, for a span of 2.5 years, any posterior fossa or brainstem lesion.

Vertical COMA

It is important to differentiate vertical COMA from acquired ocular motor apraxias. In the acquired type a horizontal saccadic deficit is accompanied by a vertical saccadic deficit.³ In our case horizontal saccades were normal. The only manifestation of an ocular motility disorder was the inability to initiate vertical saccades and OKN fast phases.

Only four cases of isolated vertical COMA have been reported.¹⁸⁻²¹ Our case No. 2 had perinatal asphyxia and a hemorrhage in the region of the internal capsule noted on MRI scanning at age 1 month. Although perinatal insults are uncommonly associated with horizontal COMA, asphyxia at birth (Table 2, column 4) has been a feature of each of the previously reported cases of vertical COMA.¹⁸⁻²¹ Neonatal asphyxia is known to cause damage to the germinal matrix in the region of the internal capsule and basal ganglia, structures through which pass corticopontine fibers, which are important in saccadic control.

Pathophysiologic features of COMA

The pathophysiologic features of COMA remain obscure. Our two cases, along with those listed in Tables 1 and 2, lead to the conclusion that horizontal and vertical COMA are due to lesions at different levels of the saccadic pathway. As shown in Figure 4, the generation of horizontal saccades in primates appears to involve activation of both the posterior parietal cortex and the frontal eye field of the cerebral hemispheres.²²⁻²⁵ Signals are conveyed from the posterior parietal cortex and the frontal eye field in one cerebral hemisphere, through the internal capsule and basal ganglia, to the ipsilateral superior colliculus, which sends a projection to neurons of the paramedian pontine reticular formation on the opposite side of the pons. When the corticopontine pathway is impaired, as in horizontal COMA, the infant learns to head thrust, activating neurons within the semicircular canal, and hence the vestibuloocular reflex, to partially compensate for the saccadic deficit.^{3, 4} In each of the reported cases of horizontal COMA with tumor (Table 1), the tumor has involved the dorsal pons or cerebellum (depicted as the "level of lesion" in Figure 4).

The generation of vertical saccades (Figure 5) appears to involve activation of the frontal eye field and posterior parietal cortex in both cerebral hemispheres.^{22, 23} The frontal eye fields and posterior parietal cortexes send descending projections through the internal capsule and basal ganglia to the brainstem. The right and left rostral interstitial medial longitudinal fasciculus (riMLF) receive projections from the frontal eye field, the superior colliculus, and the paramedian pontine reticular formation and are interconnected through fibers of the posterior commissure. The riMLF provides the signals to vertical eye muscle motoneurons in the nuclei of cranial nerves III and IV. Each of the reported cases of vertical COMA has been associated with perinatal hypoxic-ischemic encephalopathy (Table 2). Perinatal hypoxic encephalopathy is known to damage especially subcortical neurons in the region of the internal capsule and basal ganglia,^{26, 27} which is depicted as the "level of lesion" in Figure 5.

Our cases and those previously reported in the literature support the notion that dysgenesis of saccade-

related neurons, at brainstem or cerebral levels, gives rise to horizontal, or rarely, vertical COMA. The improbable concurrence of horizontal COMA and brainstem tumor, and the latency between onset of horizontal COMA and subsequent appearance of tumor, implies that in a minority of cases an occult neoplastic process, present from early infancy, contributes to the neuronal dysfunction responsible for COMA.

References

1. Cogan DG. A type of congenital ocular motor apraxia presenting jerky head movements. *Trans Am Acad Ophthalmol Otolaryngol* 1952;56:853-62.
2. Cogan DG, Chu FC, Reingold D, Tychsen L. A long-term follow-up of congenital ocular motor apraxia. *Neuro-Ophthalmol* 1980;1:145-7.
3. Leigh JR, Zee DS. *The neurology of eye movements*. 2nd edition. Salem (MA): FA Davis; 1991.
4. Zee DS, Yee RD, Singer HS. Congenital ocular motor apraxia. *Brain* 1977;100:581-99.
5. Summers GC, MacDonald JT, Wirtschafter JD. Ocular motor apraxia associated with intracranial lipoma. *J Pediatr Ophthalmol Strabismus* 1987;24:267-9.
6. Lyle DJ. Discussion of ocular motor apraxia with a case presentation. *Trans Am Ophthalmol Soc* 1961;59:274-85.
7. Zaret CR, Behrens MM, Eggers HM. Congenital ocular motor apraxia and brainstem tumor. *Arch Ophthalmol* 1980;98:328-30.
8. Fielder AR, Gresty MA, Dodd KL, Meller DH, Lefene MI. Congenital ocular motor apraxia. *Trans Ophthalmol Soc U K* 1986;105:589-98.
9. Eda I, Takashim S, Kitahara T, Ohno D, Takeshita K. Computed tomography in congenital ocular motor apraxia. *Neuroradiology* 1984;26:359-62.
10. Orrison W, Robertson J. Congenital ocular motor apraxia: a possible disconnection syndrome. *Arch Neurol* 1979;36:29-31.
11. Borchert MS, Sadun AA, Sommers JD, Wright KW. Congenital ocular motor apraxia in twins: findings with magnetic resonance imaging. *J Clin Neuro-Ophthalmol* 1987;7:104-7.
12. Tychsen L. Binocular vision. In: Hart WM, editor. *Adler's physiology of the eye: clinical applications*. 9th edition. St. Louis: Mosby-Year Book; 1992. p. 773-853.
13. Tychsen L. Pediatric ocular motility disorders of neuro-ophthalmic significance. In: Shults WT, editor. *Ophthalmology clinics of North America*. Volume 4. Philadelphia: WB Saunders; 1991. p. 615-43.
14. Brodsky MC, Baker RS, Hamed LM. *Pediatric neuro-ophthalmology*. New York: Springer-Verlag; 1996.
15. PeBenito R, Cracco JB. Congenital ocular motor apraxia. *Clin Pediatr* 1988;27:27-31.
16. Rosenberg ML, Wilson E. Congenital ocular motor apraxia without head thrusts. *J Clin Neuro-Ophthalmol* 1987;7:26-8.
17. Gittinger JW, Sokol S. The visual-evoked potential in the diagnosis of congenital ocular motor apraxia. *Am J Ophthalmol* 1982;93:700-3.
18. Hughes JL, O'Connor PS, Larsen PD, Mumma JV. Congenital vertical ocular motor apraxia. *J Clin Neuro-Ophthalmol* 1985;5:153-7.
19. Ro A, Gummesson B, Orton RB, Cadera W. Vertical congenital ocular motor apraxia. *Can J Ophthalmol* 1989;24:283-5.
20. Ebner R, Lopez L, Ochoa S, Croveto L. Vertical ocular motor apraxia. *Neurology* 1990;40:712-3.
21. Buncic JR, Crawford JS. Congenital vertical apraxia [abstract]. *Proceedings of the annual meeting of the American Association for Pediatric Ophthalmology and Strabismus*; 1997 Mar 3-7; San Juan, Puerto Rico.

22. Sparks DL. The neural translation of sensory signals into commands for the control of saccadic eye movements: the role of the primate superior colliculus. *Physiol Rev* 1985;66:118-71.
23. Tusa RJ. Saccadic eye movements: supranuclear control. *Bull Soc Belge Ophtalmol* 1989;237:67-111.
24. Sparks DL. Signal transformations required for the generation of saccadic eye movements. *Annu Rev Neurosci* 1990;13:309-36.
25. Arai K, Keller EL, Edelman JA. Two-dimensional neural network model of the primate saccadic system. *Neural Networks* 1994;7:1115-35.
26. Volpe JJ. Brain injury in the premature infant—current concepts. In *Proceedings of the Current Concepts of Cerebral Palsy Following Preterm Birth Conference*; 1993 Nov 18-20; St. Louis.
27. Volpe JJ. Hypoxic-ischemic encephalopathy: neuropathology and pathogenesis. In: Volpe JJ, editor. *Neurology of the newborn*. Volume 22. Philadelphia: WB Saunders; 1987. p. 209-35.

O **ON THE MOVE?**

Send us your new address at least six weeks ahead

Don't miss a single issue of the journal! To ensure prompt service when you change your address, please photocopy and complete the form below.

Please send your change of address notification at least six weeks before your move to ensure continued service. We regret we cannot guarantee replacement of issues missed due to late notification.

JOURNAL TITLE:

Fill in the title of the journal here. _____

OLD ADDRESS:

Affix the address label from a recent issue of the journal here.

NEW ADDRESS:

Clearly print your new address here.

Name _____

Address _____

City/State/ZIP _____

COPY AND MAIL THIS FORM TO:

Journal Subscription Services
Mosby-Year Book, Inc.
11830 Westline Industrial Dr.
St. Louis, MO 63146-3318

OR FAX TO:

314-432-1158

 **Mosby**

OR PHONE:

1-800-453-4351
Outside the U.S., call
314-453-4351