

## Long-lasting improvement following (-)-OSU6162 in a patient with Huntington's disease

J. Tedroff, MD, PhD; A. Ekesbo, MD, PhD; C. Sonesson, PhD; N. Waters, PhD; and A. Carlsson, MD, PhD

Huntington's disease (HD) is a hereditary, incurable neurodegenerative disorder characterized by a progressive loss of frontostriatal integrity.<sup>1</sup> Clinically, progressive movement disorder, dementia, and liability for behavioral disturbances and psychosis characterize the disorder. It is well known that dopaminergic drugs modify some clinical features of HD. In this respect, different agonists and antagonists of dopaminergic function may improve or worsen chorea. Whereas levodopa may offer relief from hypokinesia, concomitant worsening of chorea and mental deterioration are commonly seen.<sup>2</sup> On the other hand, neuroleptics may decrease chorea but with an accompanying global functional worsening and increased hypokinesia.<sup>3</sup>

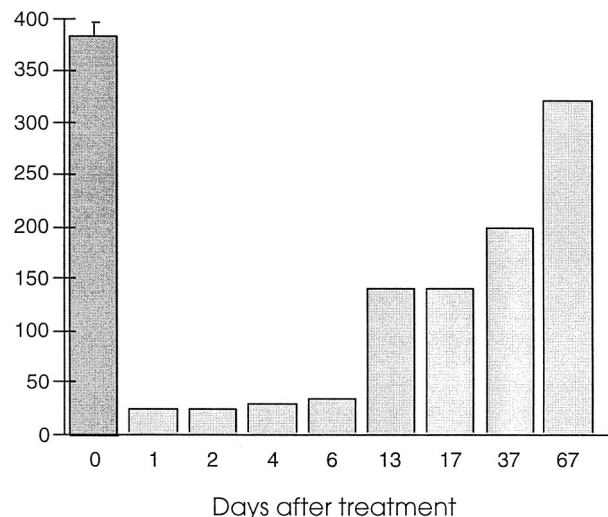
S-(-)-3-(3-methylsulphonyl-phenyl)-N-n-propylpiperidine [(-)-OSU6162] belongs to a novel class of functional modulators of dopaminergic systems displaying stabilizing effects on psychomotor function.<sup>4,6</sup> This means that the compound is able to state-dependently modify dopaminergic influence on corticostriatal functions. Such effects, among others, have been demonstrated by the ability of (-)-OSU6162 to decrease levodopa-induced dyskinesias in MPTP primates without appreciably affecting the antiparkinsonian response,<sup>7</sup> and to increase psychomotor activity in rodents with low psychomotor tone.<sup>5</sup> Given the condition-dependent effects of (-)-OSU6162 on the dopaminergic system, we investigated the effects of a single dose in a patient with HD.

**Case report.** A 50-year-old woman diagnosed with definite HD since 3 years of age volunteered to take part in the study. Moderate chorea, right hand dystonia, moderate dementia, and a postural tremor characterized her clinical features. A postural instability clinically expressed as sudden unpredictable falls appearing about twice a week was also a major source of functional disability. Six months previously, she had been treated with pimozide, but due to worsening of her functional status and intense drooling the medication was discontinued after 2 weeks. Apart from oral estradiol 2 mg daily, which was maintained throughout the investigation, she did not take any other medication.

Before drug administration the patient underwent repeated clinical assessments for 2 days. Chorea was rated according to a standardized procedure using video recordings with the patient sitting in a chair. The patient received 0.5 mg/kg (-)-OSU6162 as an IV infusion for 30 minutes (all together 30 mg). Side effects, lasting about 1 to 2 hours, including moderate sedation, light-headedness, dizziness, and nausea, were reported immediately after infusion. Beginning about 2 hours after infusion was a remarkable decrease in chorea (figure). This decrease in chorea was maximal 5 hours after infusion, at a time when the patient no longer felt sedated, and persisted for several weeks. This decrease in chorea was considerably more pronounced than the retest variability obtained at baseline. Concomitantly, a general clinical and subjective improvement of the patients' functional status occurred for about 10 days. During this time the patient was able to independently drink and feed herself without spilling, things she had not been able to do readily for at least 2 years. The patient did not experience any falls for 14 days. A subsequent placebo infusion performed 6 months later under identical conditions did not affect the number of choreatic events assessed repeatedly during 1 day.

**Discussion.** The preclinical profile of (-)-OSU6162 differs in many respects from the classically defined dopaminergic agonists, antagonists, and partial agonists. The compound belongs to a novel class of functional modulators of dopaminergic systems, not previously described. (-)-OSU6162 lacks intrinsic activity in a dopamine-depleted environment but displays a stabilizing profile in the presence of dopamine, suggesting that the compound is able to indirectly decrease the spread of dopaminergic influence in subregions of the vast dopaminergic projection areas in the striatum and the frontal lobes. The long-lasting effect of (-)-OSU6162 cannot easily be explained, but may be argued to relate to an

Choreatic events/10 min



*Figure.* Choreatic events at baseline and following 0.5 mg/kg (-)-OSU6162 in a patient with Huntington's disease. Chorea was assessed from standardized video recordings made with the patient instructed to sit still in a chair. Each bar represents the mean number of choreatic events counted from the videotape recordings during three 10-minute sessions. Baseline value comprises ratings from 2 consecutive days.

ability of the compound to affect sensitization processes. Plasma samples taken 24 hours after drug infusion showed negligible levels of (-)-OSU6162 and no metabolites. Although chorea is not regarded as a major source for functional disability or even the cause of subjective discomfort in HD, the symptom can be reliably measured in some patients without the use of subjective rating scales. In this patient sequential video ratings performed at baseline showed consistency with low variability. An important feature of the pharmacologic effect was that the reduction of chorea was accompanied by clinical and subjective improvements, indicating a coinciding functional improvement.

**Key words:** (-)-OSU6162—Huntington's disease—Chorea.

### Disclosure

Coauthors N. Waters, C. Sonesson, and A. Carlsson, as inventors of (-)-OSU6162, are subject to potential royalties for the use of the compound in the treatment of Huntington's disease.

*From the Department of Neuroscience (Drs. Tedroff and Ekesbo), Neurology, University Hospital, Uppsala; and the Department of Pharmacology (Drs. Sonesson, Waters, and Carlsson), Göteborg University, Göteborg, Sweden.*

*Received March 3, 1999. Accepted in final form June 14, 1999.*

*Address correspondence and reprint requests to Dr. Joakim Tedroff, Department of Neuroscience, Neurology, University Hospital, SE-751 85, Uppsala, Sweden; e-mail: joakim.tedroff@swipnet.se*

Copyright © 1999 by the American Academy of Neurology

### References

- Haddad MS, Cummings JL. Huntington's disease. *Psychiatr Clin North Am* 1997;20:791–807.
- Sishta SK, Templer DI. Levodopa in Huntington's chorea. *Can Med Assoc J* 1976;114:798–799.
- van Vugt JP, van Hilten BJ, Roos RA. Hypokinesia in Huntington's disease. *Mov Disord* 1996;11:384–388.
- Sonesson C, Barf T, Nilsson J, et al. Synthesis and evaluation of pharmacological and pharmacokinetic properties of monopropyl analogs of 5-

- 7-, and 8-[[trifluoromethyl)sulfonyl]oxy]-2-aminotetralins: central dopamine and serotonin receptor activity. *J Med Chem* 1995;38:1319–1329.
- Sonesson C, Tedroff J, Svensson K, Carlsson A, Hansson L, Waters N. (-)-OSU6162: a representative from a unique class of functional modulators of dopaminergic systems. *Soc Neurosci Abstr* 1997;207:531.
  - Tedroff J, Torstenson R, Hartvig P, et al. Effects of the substituted (S)-3-phenylpiperidine (-)-OSU6162 on PET measurements in subhuman primates: evidence for tone-dependent normalization of striatal dopaminergic activity. *Synapse* 1998;28:280–287.
  - Ekesbo A, Andren PE, Gunne LM, Tedroff J. (-)-OSU 6162 inhibits levodopa-induced dyskinesias in a monkey model of Parkinson's disease. *Neuroreport* 1997;8:2567–2570.

## Subacute thyroiditis in a patient with MS treated with interferon beta-1a

Yitshak Kreiss, MD; Ohad Cohen, MD; Elon Pras, MD; and Anat Achiron, MD, PhD

A 28-year-old woman was admitted for investigation of fever of 6 weeks' duration. The patient had relapsing-remitting MS for 3 years with two relapses during the last 12 months.

Eight weeks before admission, the patient's treatment with interferon beta-1a (IFN $\beta$ -1a) (Avonex; 6 MIU, intramuscular injection once weekly; Biogen Inc., Cambridge, MA) was initiated. After the second injection, persistent fever appeared and the drug was discontinued. Two weeks before admission, the patient developed generalized weakness, myalgia, weight loss of 4 kg, palpitations, increased appetite, hair loss, and anxiety.

On admission, the patient appeared well with a temperature of 37.8 °C and heart rate of 108 beats per minute. A physical examination showed the skin, lungs, heart, and abdomen to be normal. Neurologic status disclosed hyperactive tendon reflexes with bilateral Tromner and Babinski signs and no other abnormalities. There was exquisite tenderness over the anterior neck in the thyroid region.

Laboratory findings revealed marked elevation of erythrocyte sedimentation rate (106 mm/hour) and normal blood counts. Thyroid test results, which were normal before therapy, showed free T4 of 61.9 pmol/L (normal values: 11.7–28), TT3 of 4.3 nmol/L (normal values: 1.1–2.7), and thyroid-stimulating hormone < 0.02 mU/L (normal values: 0.2–3). Antithyroid peroxidase antibody level was 23 mU/L (normal <10), and antithyroglobulin titer was normal. A thyroid iodine scan showed minimal iodine uptake suggestive of subacute thyroiditis.

Treatment with naproxen and propranolol led to rapid resolution of the fever and neck tenderness and a decrease in erythrocyte sedimentation rate. Three weeks later, the patient reported weakness and weight gain. Serum thyroxine levels decreased to 8.3 pmol/L, while thyroid-stimulating hormone increased to 6.95 mU/L, findings consistent with hypothyroidism. The patient was treated with 50 mcg/d of thyroxine and 3 months later became asymptomatic with normalization of thyroid function tests.

The rapid onset of neck pain, low-grade fever without leukocytosis, and elevated erythrocyte sedimentation rate and clinical signs of hypermetabolism with laboratory evidence of thyrotoxicosis all suggest subacute thyroiditis. The depressed radioactive iodine uptake confirms the diagnosis.

Interferon alpha (IFN $\alpha$ ) has been associated with the induction or exacerbation of autoimmune and inflammatory disorders, including systemic lupus erythematosus, rheumatoidlike arthritis, and glomerulonephritis, as well as thrombocytopenia, autoimmune hemolytic anemia, exacerbation of psoriasis, sarcoidosis, and, particularly, autoimmune thyroid disease.<sup>1</sup>

Between 5% and 12% of patients receiving IFN $\alpha$  for chronic hepatitis C develop thyroid dysfunction.<sup>2</sup> Autoimmune hypothyroidism is most frequent, but Graves' disease and subacute thyroiditis also occur.

In contrast to IFN $\alpha$ , interferon beta (IFN $\beta$ ) has rarely been associated with any autoimmune diseases. In the two major series of patients treated with IFN $\beta$ , no autoimmune complications have been reported.<sup>3,4</sup> Moreover, there was no increase in autoantibodies, including antithyroid antibodies, during short-term treatment of patients with MS with IFN $\beta$ -1a.<sup>5</sup> We found only two reported cases of thyroid disease associated with interferon beta-1b (IFN $\beta$ -1b) treatment<sup>6</sup> and none associated with IFN $\beta$ -1a.

The difference in the induction of autoimmune diseases has been attributed to the low-sequence homology and to the demonstration that certain Type-I interferon receptor mutants show dif-

ferential responses to IFN $\alpha$  and IFN $\beta$ , presumably because of the complex nature of the Type-I interferon receptor.

The cause of subacute thyroiditis is not known, but one hypothesis is that it results from viral infection in genetically susceptible patients, as a link to HLA-Bw35 has been established.<sup>7</sup>

We cannot be certain that IFN $\beta$ -1a therapy was responsible for the thyroiditis, but the temporal sequence suggests that treatment either initiated or enhanced the thyroid destruction process. One possible mechanism is related to the fact that interferon production typically is stimulated by viral infection and thus may play a role in the pathogenesis of acute thyroiditis. Another mechanism is related to the ability of interferons to induce Class-I major histocompatibility complex antigen expression, which is responsible for induction of antithyroglobulin antibody and antithyroid peroxidase antibody.<sup>6</sup> These autoantibodies appear to reflect damage to thyroid tissue but may have a pathophysiologic role.

The association between IFN $\alpha$  and thyroid disease is now well-established. It appears there may be an association between treatment with IFN $\beta$  and thyroid disease. Because some symptoms of thyroid dysfunction may be difficult to distinguish from interferon-related symptoms, thyroid hormone levels should be evaluated when unexplained constitutional symptoms occur during IFN $\beta$ -1a therapy.

**Key words:** Subacute thyroiditis—MS—Interferon beta-1a.

From the Department of Medicine C, Internal Medicine (Drs. Kreiss and Pras), the Endocrinology Unit (Dr. Cohen), and the Multiple Sclerosis Unit (Dr. Achiron), Sheba Medical Center and Sackler School of Medicine, Tel Aviv University, Tel Hashomer, Israel.

Received March 19, 1999. Accepted in final form June 11, 1999.

Address correspondence and reprint requests to Dr. Yitshak Kreiss, Sheba Medical Center and Sackler School of Medicine, Tel Aviv University, Tel Hashomer, Israel 52621.

Copyright © 1999 by the American Academy of Neurology.

## References

- Vial T, Descotes J. Immune-mediated side effects of cytokines in humans. *Toxicology* 1995;105:31–57.
- Baudin E, Marcellin P, Pouteau M, et al. Reversibility of thyroid dysfunction induced by recombinant alpha interferon in chronic hepatitis C. *Clin Endocrinol* 1993;39:657–661.
- Jacobs LD, Cookfair DL, Rudick RA, et al. Intramuscular interferon Beta-1a for disease progression in relapsing multiple sclerosis. *Ann Neurol* 1996;39:285–294.
- The IFNB Multiple Sclerosis Study Group and the University of British Columbia MS/MRI Analysis Group. Interferon beta-1b in the treatment of multiple sclerosis: final outcome of the randomized controlled study. *Neurology* 1995;45:1277–1285.
- Colosimo C, Pozzilli C, Farina D, et al. No increase of serum autoantibodies during therapy with recombinant human interferon- $\beta$ 1a in relapsing-remitting multiple sclerosis. *Acta Neurol Scand* 1997;96:372–374.
- Schwid SR, Goodman AD, Mattson DH. Autoimmune hyperthyroidism in patients with multiple sclerosis treated with interferon beta-1b. *Arch Neurol* 1997;54:1169–1170.
- Schubert MF, Kountz DS. Thyroiditis—a disease with many faces. *Postgrad Med* 1995;98:101–112.

## Cerebellar ataxia associated with subclinical celiac disease responding to gluten-free diet

M.T. Pellecchia, MD; R. Scala, MD; A. Perretti, MD; G. De Michele, MD; L. Santoro, MD; A. Filla, MD; C. Ciacci, MD; and P. Barone, MD

Patients with idiopathic cerebellar ataxia may be affected by subclinical celiac disease (CD), with or without typical features of CD at duodenal biopsy.<sup>1,2</sup> The efficacy of a gluten-free diet in improving neurologic complications of CD is controversial. We describe clinical and electrophysiologic improvement in a patient with ataxia and peripheral neuropathy associated with subclinical CD after 2 years of a gluten-free diet.

**Case report.** A 34-year-old man was first observed in June 1994 with a 7-year history of slowly progressive ataxia. Neurologic examination revealed wide-based gait, positive Romberg's sign, horizontal nystagmus on lateral gaze, mild dysarthria, dysmetria in right upper limb and lower limbs, and brisk reflexes in lower limbs with mild spasticity. Results of sensory examination and muscle strength were normal. Plantar responses were flexor. The patient's score on the Inherited Ataxias Clinical Rating Scale

**Table** Central and peripheral electrophysiologic findings

| Study                                    | June 1994   | July 1996   | July 1998 | Normal values |
|--|-------------|-------------|-----------|---------------|
| MEPs                                     |             |             |           |               |
| Amplitude in rectus femoris muscle (mV)  | <b>0.35</b> | NP          | 4         | ≥0.4          |
| CMCT in rectus femoris muscle (msec)     | 15          | NP          | 11.3      | ≤15           |
| VEPs                                     |             |             |           |               |
| P100 latency (msec)*                     | <b>113</b>  | NP          | 109       | ≤112          |
| Median nerve conduction study            |             |             |           |               |
| SAP amplitude at wrist (mV)              | 8.1         | 8.8         | 9.8       | ≥6            |
| at elbow (mV)                            | 2.5         | 2.5         | 3.2       | ≥2.5          |
| SCV digit III-wrist (m/sec)              | 53.2        | <b>42.5</b> | 54.6      | ≥51           |
| wrist-elbow (m/sec)                      | 63          | 64.1        | 65.4      | ≥60           |
| Tibial nerve conduction study            |             |             |           |               |
| SAP amplitude at medial malleolus (mV)   | 2.2         | <b>0.5</b>  | 1.5       | ≥0.6          |
| at popliteal fossa (mV)                  | 0.5         | 0.5         | 1         | ≥0.2          |
| SCV first toe-medial malleolus (m/sec)   | 39          | <b>30.7</b> | 44.1      | ≥38           |
| medial malleolus-popliteal fossa (m/sec) | 53.6        | 55.7        | 52        | ≥49           |

Abnormal values are presented in bold.

\* OZ-Fpz derivation, stimulation of each eye in turn.

MEPs = motor evoked potentials; CMCT = central motor conduction time; VEPs = visual evoked potentials; SAP = sensory action potentials; SCV = sensory conduction velocity; NP = not performed.

(IACRS)<sup>3</sup> was 10. Brain MRI showed vermian atrophy. Neurophysiologic data are summarized in the table. Motor responses to transcranial cortical magnetic stimulation (MEPs) had reduced amplitude and central conduction time (CMCT) at the upper limit of normal in rectus femoris muscle. MEPs were undetectable in tibialis anterior muscle. Pattern-reversal visual evoked potentials (VEPs) showed a slight increase in latency of the P100 wave bilaterally. Somatosensory evoked potentials as well as peripheral nerve conduction study results were normal.

The disorder progressed in the following 2 years with worsening of lower limb ataxia and appearance of right Babinski sign. Total IACRS score was 12. Serum vitamin E and B12 levels were normal. Results of screening for anticerebellar antibodies were normal. Peripheral nerve conduction study showed a distal sensory neuropathy suggesting a mainly demyelinating process.

The patient was screened for antigliadin (AGAs) and antien-domysium antibodies (EMAs), which were both altered. Small bowel biopsy revealed total villous atrophy, crypt hyperplasia, and increased number of lymphocytes in the lamina propria. Subclinical CD was diagnosed and a gluten-free diet was instituted in July 1996.

Duodenal biopsy repeated 1 year later showed resolution of villous atrophy. AGAs fell to normal values and EMAs disappeared.

Neurologic examination after 2 years of gluten restriction showed improved gait ataxia and dysmetria, and normal stance, tone, and flexor plantar responses. Total IACRS score was 6. Brain MRI was unmodified. VEPs were in the normal limits, as were MEP amplitude and CMCT in rectus femoris muscle; MEPs remained undetectable in tibialis anterior muscle. Peripheral nerve conduction parameters became normal.

**Discussion.** We describe the first case of ataxic syndrome associated with subclinical CD responding to a gluten-free diet. Cerebellar ataxia with classic CD has frequently been reported, but clinical response to a gluten-free diet was never found. In three patients with spinocerebellar syndromes associated with classic CD, long-term dietary restriction did not revert neurologic complications.<sup>4</sup> Spinocerebellar degeneration and classic CD has also been described in a patient who initially deteriorated despite a gluten-free diet and vitamin E therapy, but later stabilized.<sup>5</sup> An improvement of cerebellar syndrome was reported in a woman with classic CD not responsive to a gluten-free diet, following vitamin E therapy.<sup>6</sup> In our case, gluten restriction, in absence of

malabsorption signs and vitamin deficits, resulted in a clear improvement of clinical and electrophysiologic abnormalities and resolution of villous atrophy. We suggest that neurologic complications in subclinical CD may be more responsive to gluten restriction than in classic CD. Furthermore, irreversible neurologic complications were more likely to occur in patients with persistent villous atrophy despite a gluten-free diet.<sup>4</sup>

Although peripheral neuropathy was not clinically evident in our patient, neurophysiologic signs of neuropathy appeared during follow-up and were reverted by gluten restriction. This is consistent with previous reports of peripheral neuropathy responding to a gluten-free diet.<sup>7</sup>

Corticospinal signs are described in only 1 of 28 patients with gluten ataxia, but the efficacy of a gluten-free diet is not reported.<sup>2</sup> Here we report, for the first time, the improvement of clinical and neurophysiologic corticospinal signs in a patient with CD following a gluten-free diet.

The etiology of neurologic damage in CD is poorly understood. A possible pathogenic role has been proposed for AGAs, which could be directly or indirectly neurotoxic.<sup>1</sup> The neuropathologic finding of lymphocytic infiltration confined to cerebellum and posterior columns has been reported in one ataxic patient with gluten sensitivity, thus suggesting an immune-mediated neurotoxicity.<sup>2</sup>

Further studies on large populations are required to characterize both pathogenesis of neurologic disorders in the classic versus subclinical form of CD and the efficacy of a gluten-free diet.

**Key words:** Cerebellar ataxia—Subclinical celiac disease—Gluten-free diet.

*From the Departments of Neurological Sciences (Drs. Pellicchia, Scala, Perretti, De Michele, Santoro, Filla, and Barone) and Systematic Pathology (Dr. Ciacci), University of Napoli Federico II, Napoli, Italy.*

*Received April 2, 1999. Accepted in final form June 11, 1999.*

*Address correspondence and reprint requests to Dr. Paolo Barone, Clinica Neurologica, Ed. 17, Department of Neurological Sciences, Via S. Pansini 5, 80131 Napoli, Italy.*

Copyright © 1999 by the American Academy of Neurology

## References

1. Pellicchia MT, Scala R, Filla A, De Michele G, Ciacci C, Barone P. Idiopathic cerebellar ataxia associated with celiac disease: lack of dis-

- tinctive neurological features. *J Neurol Neurosurg Psychiatry* 1999;66:32–35.
- Hadjivassiliou M, Grunewald RA, Chattopadhyay AK, et al. Clinical, radiological, neurophysiological, and neuropathological characteristics of gluten ataxia. *Lancet* 1998;352:1582–1585.
  - Campanella G, Filla A, De Falco F, Mansi D, Durivage A, Barbeau A. Friedreich's ataxia in the south of Italy: a clinical and biochemical survey of 23 patients. *Can J Neurol Sci* 1980;7:351–358.
  - Muller AF, Donnelly MT, Smith CML, Grundman MJ, Holmes GKT, Toghil PJ. Neurological complications of celiac disease: a rare but continuing problem. *Am J Gastroenterol* 1996;191:1430–1435.
  - Ward ME, Murphy JT, Greenberg GR. Celiac disease and spinocerebellar degeneration with normal vitamin E status. *Neurology* 1985;35:1199–1201.
  - Mauro A, Orsi L, Mortara P, Costa P, Schiffer D. Cerebellar syndrome in adult celiac disease with vitamin E deficiency. *Acta Neurol Scand* 1991;84:167–170.
  - Kaplan JG, Pack D, Horoupian D, DeSouza T, Brin M, Schaumburg H. Distal axonopathy associated with chronic gluten enteropathy: a treatable disorder. *Neurology* 1988;38:642–645.

## A medullary syndrome characterized by wild arm ataxia

Robert D. Currier, MD; and Jose Bebin, PhD, MD

Two or three decades ago we saw a patient who had a lateral medullary infarct characterized in the first few days by wild movements on attempted motion of the ipsilateral arm. It was postulated that this unusual picture might have resulted from involvement of the sensory centers of the caudal medulla. Four similar patients have since been examined, two in the acute phase, and followed. One was studied by MRI scan and one by autopsy.

The five patients were men, age 44 to 74. The clinical picture was consistent. There was less nausea, vomiting (two of the five vomited), vertigo, dysphagia, and dysarthria than with the usual lateral medullary syndrome<sup>1</sup> but more ipsilateral arm and to a lesser extent leg ataxia. The bulbar symptoms were not severe and were short lived. Hoarseness was present in four of the five and hiccups that lasted a few days were noted in three. The unilateral ataxia was characterized by wild motion of the proximal ipsilateral arm and in two of the ipsilateral legs, with any voluntary movement. When upward movement of the affected arm was attempted the arm would fling itself over the head in a grossly ataxic jerky fashion. At rest the arm was still without tremor and with normal tone, strength, and sensory examination. It resembled neither the alien hand nor arm pseudochoreoathetosis.

A 51-year-old man, disabled because of diabetes and hypertension, became unbalanced with vertigo. With any attempt at movement of the right arm it would fling over his head. When examined 5 days after onset there were findings of a right lateral medullary syndrome plus a severe dysmetric wild awkwardness and overshooting of the right arm and leg, worse in the arm.

Vibratory sense and light touch were normal in the four limbs. The movements of the arm and leg decreased to the usual ataxia by the ninth day. An MRI head scan showed a lateral medullary infarction extending from mid to caudal medullary levels.

A 74-year-old man with a history of chronic lung disease had sudden vertigo and could not rise from the chair. Five days later he was hoarse and had findings of a right lateral medullary infarct. Proprioception and vibratory and tactile senses were normal. He was markedly ataxic in the right shoulder and arm and slightly in the proximal right leg. The right arm moved wildly over his head when he was asked to raise both arms to the front.

He experienced two respiratory arrests and died. The cause of death was a completely thrombosed right vertebral artery but the basilar artery was not thrombosed and the cerebellum was not infarcted.

The right sided medullary infarct included rostral, mid, and caudal medulla but did not extend into the inferior cerebellar peduncle or the cervical cord. It did not involve the crossed pyramidal tract but did affect the crossing fibers of the sensory decussation, the gracilis and cuneate nuclei and funiculi, the lateral cuneate nucleus, the olivocerebellar tract, and the dorsal and ventral spinocerebellar tracts (figure).

The lateral cuneate nucleus, a proprioceptive relay center, receives fibers originating in the arm that have traveled through the cervical cord dorsal roots and turned cephalad with fasciculus cuneatus. They synapse in the lateral cuneate nucleus with projections to the ipsilateral cerebellar cortex through the restiform body. This does not relay conscious proprioception. There is not a similar nucleus for the leg. Because lateral cuneate nucleus and spinocerebellar tract involvement are common in the typical lateral medullary lesion it is probably the additional involvement of the sensory decussation and cuneate nucleus in the caudal medulla that cause this clinical picture.

The arm wildness was apparently largely produced by the shoulder muscles. No testing was done of wrist–finger proprioception to compare with elbow–shoulder.

Manto et al.<sup>2</sup> and Gilman<sup>3</sup> believe that cerebellar tremor is distinct from hypermetria, the latter resulting from delayed or inadequate antagonist muscle activity. These movements had the appearance of much delayed agonist cessation and antagonist onset. Because cuneate nucleus or sensory decussation loss do not produce such a gross disorder of arm function, there must be an additive effect that becomes evident when the other two proprioceptive paths (lateral cuneate and spinocerebellar) are interrupted.

Hoarseness was the most common persisting bulbar symptom (four of five patients). The caudal end of the nucleus ambiguus gives rise to the laryngeal nerves innervating the vocal cords. This was still present 5 years later in one patient.

We believe the slightly more caudal location with involvement of the cuneate and lateral cuneate nuclei, the crossing fibers of the sensory decussation, and the spinocerebellar pathways give an



Figure. Right lateral medullary infarct at level of sensory decussation including gracilis, cuneate and lateral cuneate nuclei, and internal arcuate fibers of the sensory decussation (luxol fast blue, H-E).

unusual syndrome of severe but temporary proximal unilateral arm ataxia usually unaccompanied by and therefore not masked by dysphagia, nausea, vomiting, and vertigo. It is quite striking when seen and probably has localizing value. Further research is needed on proximal arm proprioception during the acute phase of this syndrome.

**Key words:** Wallenberg—Lateral medullary infarct—Arm ataxia—Hypermetria—Cuneate and lateral cuneate nuclei.

### Acknowledgment

The authors are indebted to the following members of the faculty and staff of the University of Mississippi Medical Center: Drs. James Hardy, James Neill, Jon Fratkin, and Duane Haines, and Mrs. Marilyn Currier.

From the Departments of Neurology (Dr. Currier) and Pathology (Dr. Bebin), University of Mississippi, Medical Center, Jackson.

Received December 17, 1997. Accepted in final form June 19, 1999.

Address correspondence and reprint requests to Dr. Robert D. Currier, 5529 Marblehead Dr., Jackson, MS 39211.

Copyright © 1999 by the American Academy of Neurology

### References

1. Currier RD, Giles CL, DeJong RN. Some comments on Wallenberg's lateral medullary syndrome. *Neurology* 1961;11:778–791.
2. Manto M, Godaux E, Jacquy J. Cerebellar hypermetria is larger when the inertial load is artificially increased. *Ann Neurol* 1994;35:45–52.
3. Gilman S. Cerebellar control of movement. *Ann Neurol* 1994;35:3–4.

## Possible usefulness of lamotrigine in the treatment of SUNCT syndrome

G. D'Andrea, MD; F. Granella, MD; and M. Cadaldini, MD

Short-lasting unilateral neuralgiform headache attacks with conjunctival injection and tearing (SUNCT syndrome), first described by Sjaastad et al. in 1989,<sup>1</sup> is an uncommon form of strictly unilateral headache accompanied by local autonomic signs. The pain is of short duration (5 to 120 seconds), stabbing or burning in quality, abrupt in onset, and accompanied by marked lacrimation, conjunctival injection, nasal stiffness, and rhinorrhea ipsilateral to pain.<sup>2</sup> The natural history of the disease is poorly understood. Generally, a periodic pattern has been reported, with active periods erratically alternating to remission phases. During symptomatic periods, the frequency of attacks varies from less than one per day to more than 30 per hour. The pathophysiology of SUNCT is unknown. Recently, Goadsby and Lipton<sup>3</sup> proposed classifying SUNCT syndrome within the trigeminal autonomic cephalgias (TACs), putatively characterized by a nexus of activation between trigeminal afferents (giving rise to pain) and cranial parasympathetic efferents (giving rise to autonomic features). Results of treatment for SUNCT are disappointing. Several types of drugs, such as nonsteroidal anti-inflammatory drugs (NSAID), calcium channel blockers, sumatriptan, and carbamazepine, have shown little benefit.<sup>3</sup>

We describe a woman with SUNCT who was successfully treated with lamotrigine.

**Case report.** A 66-year-old woman presented with a 7-month history of headache. The painful attacks, characterized by a short-lasting (5 to 10 seconds) severe throbbing or stabbing pain in the left retro-orbital region, were accompanied by ipsilateral intense tearing, conjunctival injection, and nasal obstruction. No photophobia, phonophobia, or nausea were present. No precipitating mechanisms, either spontaneous or provoked, were identified. In the first 6 months, the attacks were sporadic, occurring no more than four to five times a month. Subsequently, the frequency of the attacks increased dramatically. At the time of our observation, the patient had been having 10 to 15 attacks per day for 40 days. The majority of the attacks occurred in the morning and in the afternoon; a few attacks, however, woke up the patient during the night. The attacks were not responsive to aspirin or other NSAID.

The family history for headache was negative. Anamnesis was unremarkable, except for an operation for hysterectomy at age 52.

Results of physical and neurologic examinations were normal. Routine laboratory data were normal, except for a mild hypercholesterolemia. CT scan of the brain and orbits did not reveal any abnormality.

Treatment with indomethacin (50 mg tid) was unsuccessful, causing no improvement either in the frequency or severity of the attacks. A second attempt with carbamazepine (400 mg tid) was equally disappointing. Subsequently, we decided to treat the patient with lamotrigine (LTG), 50 mg a day. Under this regimen, although the frequency of the attacks did not change, a substantial reduction of the intensity was noted. After 2 weeks, however, an abrupt worsening of the frequency (up to 40 per day, mainly at night) and the severity of attacks occurred. We increased the dosage of LTG to 100 mg daily, obtaining an 80% reduction in the attack frequency. A further dosage increase to 150 mg per day abolished the attacks. Three months later, LTG was stopped without any recurrence of the painful attacks. The patient has been pain-free during the subsequent 15-month follow-up.

**Discussion.** SUNCT is a pathologic condition generally refractory to treatment. Pareja et al.<sup>4</sup> have systematically tried several drugs used in cluster headache, against trigeminal neuralgia or other headache types, such as NSAID, tricyclic antidepressants, and calcium channel blockers, for SUNCT with no or minimal effect.

In our case, treatment with LTG was effective in reducing and, at higher dosage, abolishing the painful attacks. Our patient did not experience any adverse event. However, considering that the risk of severe cutaneous reaction appears to be increased with a rapid titration, a lower (25 mg per day) initial dosage and a slower titration should be used in the future in the treatment of similar cases.

LTG is a new antiepileptic drug used for treating neurologic painful syndromes, trigeminal neuralgia in particular.<sup>5</sup> LTG acts by stabilizing the neuronal sodium channel.<sup>6</sup> By this mechanism, the drug may suppress the excessive release of glutamate, which is an *N*-methyl-D-aspartic acid neurotransmitter involved in the antinociceptive pathway responsible for the establishment of chronic pain.<sup>7</sup> Because the pathophysiology of painful attacks in SUNCT is obscure, we do not know if LTG in our patient acted through this mechanism of action. We hope that the positive effect of LTG observed in our patient can be confirmed in other cases. If so, LTG could become the first specific treatment for SUNCT syndrome.

**Key words:** SUNCT syndrome—Lamotrigine—Headache.

From the Headache Center (Drs. D'Andrea and Cadaldini), Este Hospital, Este; and the Institute of Neurology (Dr. Granella), University of Parma, Italy.

Received April 20, 1999. Accepted in final form June 22, 1999.

Address correspondence and reprint requests to Dr. Franco Granella, Istituto di Neurologia, Università di Parma, Strada del Quartiere, 4, 43100 Parma, Italy.

Copyright © 1999 by the American Academy of Neurology

### References

1. Sjaastad O, Saunte C, Salvesen R, et al. Shortlasting, unilateral neuralgiform headache attacks with conjunctival injection, tearing, sweating, and rhinorrhea. *Cephalalgia* 1989;9:147–156.
2. Pareja JA, Sjaastad O. SUNCT syndrome. A clinical review. *Headache* 1997;37:195–202.
3. Goadsby PJ, Lipton RB. A review of paroxysmal hemicranias, SUNCT syndrome and other short-lasting headaches with autonomic feature, including new cases. *Brain* 1997;120:193–209.
4. Pareja JA, Kruszewski P, Sjaastad O. SUNCT syndrome: trials of drugs and anesthetic blockades. *Headache* 1995;35:138–142.
5. Zakrzewska JM, Chaudhry Z, Nurmikko TJ, Patton DW, Mullens EL. Lamotrigine (Lamictal) in refractory trigeminal neuralgia: results from a double-blind placebo controlled crossover trial. *Pain* 1997;73:223–230.
6. Xie X, Lancaster B, Peakman T, Garthwaite J. Interaction of the antiepileptic drug lamotrigine with recombinant rat brain type IIA Na<sup>+</sup> channels and with native Na<sup>+</sup> channels in rat hippocampal neurons. *Pflugers Arch Eur J Physiol* 1995;430:437–446.
7. Woolf CJ, Thompson SWN. The induction and maintenance of central sensitization is dependent on *N*-methyl-D-aspartic acid receptor activation: implications for post-injury pain hypersensitivity states. *Pain* 1991;44:293–299.