



## Case report

## Migraine associated bilateral intracerebral haemorrhages

Andreas Raabe <sup>a,\*</sup>, Udo Krug <sup>b</sup><sup>a</sup> Department of Neurosurgery, University of Leipzig, Johannisallee 34, 04103 Leipzig, Germany<sup>b</sup> Department of Neurosurgery, Klinikum Chemnitz, Flemmingstraße 2, 09116 Chemnitz, Germany

Received 22 December 1998; received in revised form 6 January 1999; accepted 22 March 1999

**Abstract**

The authors report a case of bilateral basal ganglionic haemorrhages which occurred during an attack of classical migraine. The patient had a history of migraine associated with aura of neurological deficit for 10 years and a history of arterial hypertension for 20 years, which was treated with propranolol. Intracerebral haemorrhage during an attack of migraine is very rare and up to now the existence of true migraine-induced intracerebral haemorrhage has been controversial. Our case of bilateral occurrence of the haemorrhages supports the theory of the existence of migraine-induced damage of the wall of intraparenchymal vessels during vasoconstriction and focal ischaemia at the beginning of a migraine attack. Subsequent vessel rupture may occur during the following period of increased cerebral blood flow especially with coexisting arterial hypertension. The terminology of the syndrome of migraine associated with intracerebral haemorrhage is reviewed. © 1999 Elsevier Science B.V. All rights reserved.

*Keywords:* Migraine; Bilateral intracerebral haemorrhages

**1. Introduction**

Migraine-related intracerebral haemorrhage is a rare syndrome with only few cases reported in the literature. The existence of true migraine-induced intracerebral haemorrhage is controversial, because intracerebral haemorrhage (ICH) can present as symptomatic migraine and risk factors for ICH may exist and interact with the vascular changes which occur during an attack of migraine.

We report a case of bilateral basal ganglionic ICH that developed during an attack of migraine in a patient with a history of arterial hypertension.

**2. Case report**

A 46-year-old man began experiencing headache attacks associated with aura of neurological deficit (Inter-

national Headache Society (IHS) classification 1.2, previously termed classical migraine) when he was 36 years of age. He developed visual disturbances such as stars, spark photopsia, scotoma and hemianopia followed by throbbing bitemporal headache. Over the next 10 years, he experienced six to 12 such episodes per year. Scotoma and hemianopia resolved completely following all episodes. There were two migraine attacks occurring 5 and 2 days prior to emergency admission. There was a history of arterial hypertension for 20 years, which was treated with propranolol. Monitoring of arterial blood pressure was performed quarterly. Systolic peak values were 150 mmHg and diastolic peak values were 95 mmHg during the recent 5 years. No other risk factors such as smoking, coagulopathy or vasculopathy could be established. There was no ergotamine administration. On the day of admission to hospital he suffered again from an attack of classical migraine. The actual symptoms of migraine exactly mimicked the symptoms of previous attacks. There was no specific treatment during this attack, especially no aspirine administration. As usual he went to bed to alleviate his complaints. After 12 h he was found by his wife unconscious and was admitted to hospital.

\* Corresponding author. Tel.: +49-341-9712000; fax: +49-341-9712009.

E-mail address: araa@server3.medizin.uni-leipzig.de (A. Raabe)

On emergency admission he was not responding to painful stimuli and so intubated and ventilated. Arterial blood pressure was 135/75 mmHg. Computed tomography scanning revealed two distinct intracerebral haemorrhages situated bilateral within the basal ganglia (Fig. 1). Four vessel angiography performed 24 h after admission showed signs of mass effect due to the haemorrhage but otherwise normal findings. There was no angiographic vasospasm. Coagulation tests including platelets, partial thromboplastin time, prothrombin time, fibrinogen and antithrombin III showed normal values. There was no need for surgical evacuation of the left sided hematoma. The patient improved gradually and was severely disabled at 6 months (Glasgow Outcome Scale 3).

### 3. Discussion

Although rare, migraine-associated permanent neurological deficits have been reported since 1882 [1]. True migraine-induced stroke is an accepted separate entity within the IHS classification (migrainous cerebral infarction, IHS 1.6.2). Contrary to migraine-induced stroke there are only few reports of migraine associated haemorrhage in the literature [2–9]. To date the theory of migraine as a cause of ICH is controversial, because it is difficult to prove a specific migraine induced mechanism. The main criticism is that these cases are most likely symptomatic or mimicking migraine. However, from the viewpoint of pathogenesis it might be possible that ischaemic softening of tissue during vasoconstriction, spreading oligoemia and focal ischaemia followed

by increased cerebral blood flow during the headache phase of a migraine attack may cause ICH. Severe vasospasm may result in ischaemia of intraparenchymal vessel walls, leading to necrosis and subsequent vessel rupture when perfusion is restored. Vessel wall necrosis associated with subacute inflammatory changes has been demonstrated by surgical pathology in two cases following the evacuation of migraine-induced ICH [3].

Spontaneous multiple intracerebral haemorrhages of any cause are an exceptionally rare phenomenon. Although bilateral or multifocal occurrence of ICH have been observed in association with several diseases such as amyloid angiopathy, angitis, neuro-Behcet disease [10], migraine [7] or severe arterial hypertension [11], the common mechanism is probably bilateral or multifocal vasculopathy. The spasm induced ischaemia of intraparenchymal vessel wall with subsequent rupture may explain the bilateral occurrence of the ICH, which supports a migraine induced mechanism rather than arterial hypertension.

To our knowledge there is only one case of migraine-associated bilateral ICH reported in the literature [7]. Contrary to our case the haemorrhages were situated occipitally and there were signs of cerebral amyloid angiopathy.

In our patient the frequency of his migraine attacks increased before the occurrence of the ICH and he did not receive treatment during those attacks. Four vessel angiography was normal but angiography performed 36 h after the migraine attack might have missed transient spasm and a negative study does not exclude spasm in small intraparenchymal lenticulostriatal branches. Although blood pressure was treated vigorously and there

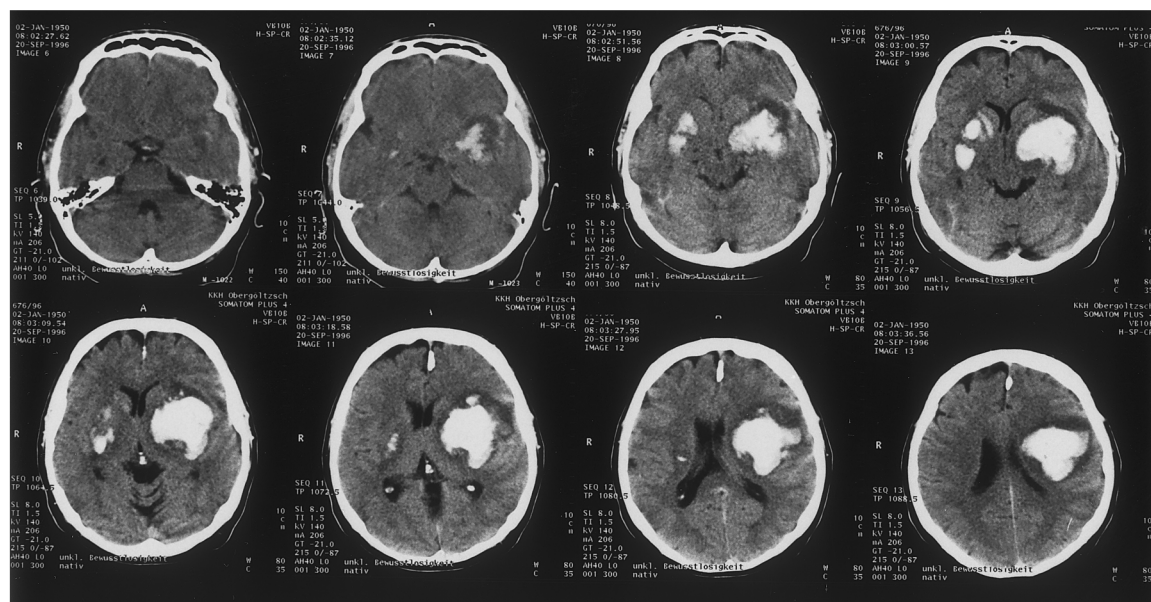


Fig. 1. Computed tomography scans obtained 2 h after admission showing separate bilateral basal ganglia haemorrhage which occurred 12 h after the onset of an attack of classical migraine.

were no increased values found during the recent 5 years, pathologically increased pressure during the migraine attack and thus a hypertensive origin of the haemorrhage cannot be ruled out.

In summary, we believe that in our case arterial hypertension increased the risk for developing ICH but the main pathogenic event that led to the bilateral occurrence of the basal ganglionic haemorrhages were probably the migraine-induced changes of the wall of lenticulostriatal vessels that took place during the repeated attacks the days before admission.

True migraine-induced ICH has to be distinguished from other forms of migraine-related ICH:

1. coexisting ICH and migraine, where the ICH occurs remotely in time from a typical attack of migraine. These two conditions may coexist without migraine being a cause of ICH; and
2. ICH with clinical features of migraine where the hematoma is unrelated to migraine pathogenesis but is presenting with symptoms of migraine. A typical example for the this category are symptoms which mimic migraine that may occur in ICH without a previous history of migraine.

In true migraine-induced ICH the patient must have previously fulfilled the criteria for migraine, the attack must have started with the typical neurological symptoms known from previous attacks and the ICH must occur during the course of a typical migraine attack. In most cases, unusually severe and protracted headache were reported [3] and the ICH developed in the late phase of the attack. Therefore, contrary to the definition of migrainous stroke [12], neurological deficits caused by the ICH may cause new symptoms previously not experienced by the patient such as hemiparesis, aphasia and disturbances of consciousness. Other causes of ICH such as aneurysm, arteriovenous malformation, vasculitis, coagulopathy or drug abuse must be ruled out. However as with migraine-induced stroke, risk factors such as arterial hypertension may exist and might contribute to the development of ICH. According to this classification, our case would be classified as true migraine-induced ICH with a history of arterial hypertension.

Our report adds one more interesting case to the issue of migraine-related complications and supports the existence of true migraine-induced ICH. We agree with others that true migraine-induced ICH might be avoided if migraine is treated vigorously [12]. Likewise, arterial hypertension in patients with migraine should be more aggressively treated and increased arterial blood pressure during attacks of migraine should strictly be avoided.

### Acknowledgements

We gratefully acknowledge the editorial assistance of Dr Hugh Richards, MRC Cambridge Centre for Brain Repair, Addenbrooke's Hospital, University of Cambridge, England.

### References

- [1] Galezowski X. Ophthalmic megrim. *Lancet* 1882;1:176.
- [2] Aldrey JM, Castillo J, Leira R, Suarez P, Sobrido MJ, Noya M. Cerebral hemorrhage and migraine. *Rev Neurol* 1996;24:183–6.
- [3] Cole AJ, Aube M. Migraine with vasospasm and delayed intracerebral hemorrhage. *Arch Neurol* 1990;47:53–6.
- [4] Fujita T, Nakai O, Seo H. Migraine equivalent and hemorrhagic infarction (letter). *Stroke* 1994;25:912–2.
- [5] Furui T, Iwata K. Intracerebral hemorrhage associated with migrainous headache—a case report. *Angiology* 1993;44:164–8.
- [6] Gautier JC, Majdalani A, Juillard JB, Carmi AR. Cerebral hemorrhage in migraine. *Rev Neurol Paris* 1993;149:407–10.
- [7] Nakamura K, Saku Y, Ibayashi S, Fujishima M. Simultaneous multiple brain hemorrhage associated with migraine—a case report. *Angiology* 1997;48:551–5.
- [8] Saper JR, Carter D, Hamel R. Brain hemorrhage during acute migraine. *Headache* 1989;29:310–1.
- [9] Shuaib A, Metz L, Hing T. Migraine and intracerebral hemorrhage. *Cephalalgia* 1989;9:59–61.
- [10] Hasegawa Y, Okada H, Okamoto S. Neuro-Behcet disease with bilateral cheiro-oral syndrome following simultaneous multiple brain hemorrhage. *Rinsho Shinkeigaku* 1991;31(7):754–9.
- [11] Sugiura M, Himuro H, Tanikawa T, Beppu T. A case of bilateral hypertensive intracerebral hemorrhage which occurred simultaneously. *No Shinkei Geka* 1982;10(2):193–8.
- [12] Welch KM, Levine SR. Migraine-related stroke in the context of the International Headache Society classification of head pain. *Arch Neurol* 1990;47:458–62.