



## Case report

## Ondine's curse in association with diabetes insipidus following transient vertebrobasilar ischemia

J. Kraus \*, J.G. Heckmann, A. Druschky, F. Erbguth, B. Neundörfer

*Department of Neurology, Friedrich–Alexander–Universität Erlangen–Nürnberg, Schwabachanlage 6, 91054 Erlangen, Germany*

Received 15 December 1998; received in revised form 2 February 1999; accepted 22 March 1999

**Abstract**

Ischemic lesions of the brainstem can lead to complex neurologic deficits. Failure of the automatic control of ventilation (Ondine's curse syndrome) is a possible but rare syndrome following localized brainstem dysfunction. We report on a 49-year-old man with intermittent bradycardia, cranial nerves' dysfunctions and a slight right-sided hemiparesis. An acute brainstem ischemia was diagnosed and treated immediately with high-dose heparin. Cerebral angiography revealed a proximal occlusion of the left vertebral artery but a normal right vertebral artery and a hyperplastic right posterior inferior cerebellar artery. Cranial Computed Tomography and MRI scan demonstrated multiple ischemic lesions in the posterior circulation. During a 4-week treatment course the patient underwent six episodes of acute severe hypoxia and hypercapnia requiring orotracheal intubation twice and manual ventilation by air mask over a few minutes for four times after a tracheostomy had been performed. Twice a short-term episode of hypothalamic Diabetes insipidus was observed following hypoventilation. We conclude that both Ondine's curse syndrome and diabetes insipidus were due to transient vertebrobasilar ischemia. © 1999 Elsevier Science B.V. All rights reserved.

*Keywords:* Ondine's curse syndrome; Stroke; Brainstem infarction; Diabetes insipidus; Respiratory centers

**1. Introduction**

Ondine's curse syndrome is described as failure of automatic control of ventilation when mechanical ventilation disorders are excluded. This rare central alveolar hypoventilation disorder can appear both as congenital and acquired disease [1,2]. The acquired form of Ondine's curse syndrome can be associated with numerous pathological conditions such as multiple sclerosis [3], Shy–Drager syndrome [4], infectious diseases like viral [5] and bacterial encephalitis [6], vascular malformation [7] and generalized anoxia-ischemia [8]. A prominent coincidence has been found between this syndrome and Hirschsprung's disease, which is due to segmental colonic aganglionosis [9,10]. However, failure of automatic control of ventilation is rarely reported following brainstem infarction and verte-

brobasilar ischemia in adults [11–13].

In literature Ondine's curse in association with diabetes insipidus in adults is well known following tuberculosis and Shy–Drager syndrome but none of them was combined with cerebral infarction [4,14]. We recently cared for a patient suffering from acute brainstem infarction in combination with Ondine's curse syndrome and central diabetes insipidus.

**2. Case report**

The 49-year-old male patient was admitted suffering from intermittent bradycardia with heart rates down to 35 bpm, acute dysphagia, dysarthria, left-sided facial sensory deficit and a slight right-sided hemiparesis. These signs and symptoms led to the diagnosis 'acute brainstem ischemia' and high-dose heparin treatment was initiated.

\* Corresponding author. Present address: Department of Neurology, Justus–Liebig–Universität Gießen, Am Steg 10, 35385 Gießen, Germany. Tel.: +49-641-9945400; fax: +49-641-9945449.

Because of his cardiac problems and fluctuating brainstem symptoms the patient was transferred to the intensive care unit 2 days later. On admission the patient was awake, well orientated. The neurological examination revealed nystagmus to the left and the right lateral gaze with a vertical component, pupils' anisocoria (right > left), left-sided reduced cornea reflex, facial sensory deficit on the left side, dysphagia and dysarthria, slight flaccid left-sided hemiparesis, hemiataxia and hemihypalgesia on the right side.

Cerebral angiography (Fig. 1) as well as Doppler's sonography demonstrated a proximal occlusion of the left vertebral artery. The right vertebral artery was normally filled and the right posterior inferior cerebellar artery (PICA) was found to be hyperplastic. However, the connection from the right vertebral artery to the basilar artery was hypoplastic. There was no affection of the basilar artery. Cranial Computed Tomography showed slight hypodense lesions in both thalamus regions, both occipital lobes and in the left cerebral pedunculus. MRI scan additionally revealed infarction

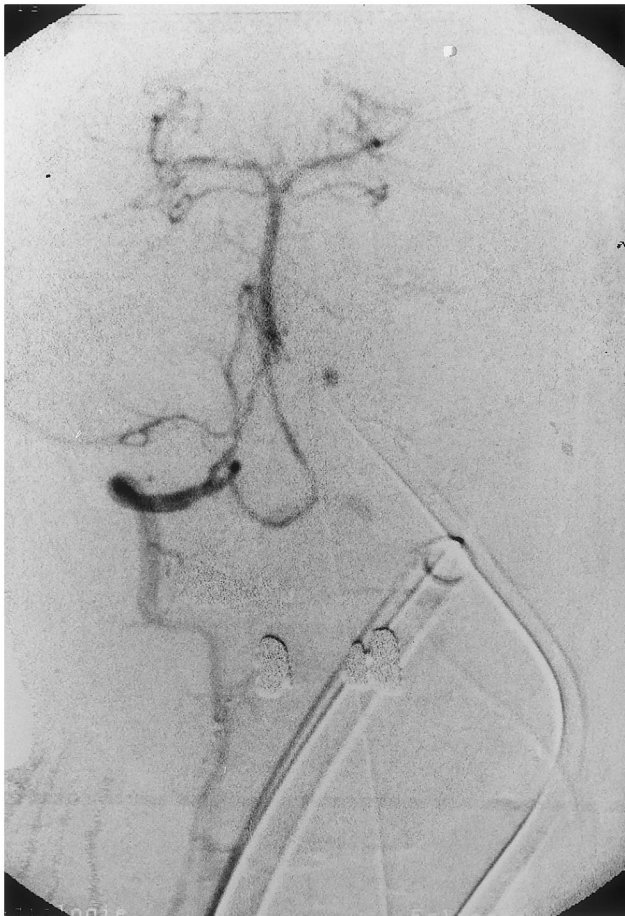


Fig. 1. Cerebral angiography of a 49-year-old patient: proximal occlusion of the left vertebral artery, normal right vertebral artery and hyperplastic right PICA; the connection from the right vertebral artery to the basilar artery is hypoplastic.

of the left cerebellum as well as pontine and medullar ischemic lesions on both sides.

After a temporary stabilization the patient had an acute respiratory arrest which led to an emergency orotracheal intubation followed by respirator therapy. The patient could be extubated without any problems after 9 days of respirator treatment. Ten hours later, the sleeping patient suddenly stopped breathing again and a new orotracheal intubation was necessary following blood gas study with PaO<sub>2</sub> of 56.7 mmHg, oxygen saturation of 83.4% and PaCO<sub>2</sub> of 68.5 mmHg. Respirator therapy was necessary for another 2 days. The subsequent pulmonary test was normal.

A tracheostomy was performed because of the two attacks and several blood gas tests with hypoxia and hypercapnia. In the further course of treatment another four episodes of respiratory arrests requested manual ventilation by an air mask. In addition, two episodes with diagnosed central diabetes insipidus were treated with vasopressin for several days.

Finally, the patient was stabilized after 4 weeks of intensive care treatment and could be transferred to a rehabilitation center. The follow-up examination after 6 months revealed discrete dysphagia and dysarthria, left-sided spastic hemiparesis so that the patient was only ambulatory with assistance. The tracheostomy was closed because the patient did not have any more hypoventilation attacks.

### 3. Discussion

In our patient acquired Ondine's curse syndrome was diagnosed based on six episodes with isolated respiratory arrest with hypoxia and hypercapnia but without a mechanical ventilation failure. Ondine's curse syndrome is described in many clinical situations like multiple sclerosis, Shy-Drager syndrome, encephalitis, vascular malformation, generalized anoxia-ischemia and very rarely in vertebrobasilar ischemia in adults [3–5,7–9,11].

For three reasons the described case is unusual:

Firstly, the etiological aspect with ischemia of the posterior circulation is very rare [11–13]. There are only a few reports in literature describing brainstem infarction as the cause of Ondine's curse syndrome. The severe vertebrobasilar arteriosclerosis in our patient led to multiple ischemic lesions of the brainstem and the posterior circulation. Thus, the pathogenetic concept of Ondine's curse syndrome is hypoperfusion of the brainstem and in particular of the respiratory centers. The course with six isolated apnea attacks with complete remission with stable ventilation for 6 months is atypical. It can be assumed that complete occlusion of the left vertebral artery appeared accidentally. The small connection of the hypoplastic distal vertebral artery on the right side might also be

responsible for hypoperfusion in the more distal part of the vertebrobasilar system. The consequences were cranial nerve dysfunctions and left-sided hemiparesis as signs of brainstem infarction and as transient ischemic attacks (TIA) of the brainstem with symptoms of Ondine's curse syndrome. When perfusion of the brainstem was improved by anticoagulant treatment, potential spontaneous thrombolysis and revascularization including collateralization, the attacks of alveolar hypoventilation disappeared.

Secondly, our patient developed the combination of Ondine's curse syndrome with central diabetes insipidus. To our knowledge there is no report in the literature of a combination of both diseases attributed to vertebrobasilar ischemia. We consider that transient diabetes insipidus can be regarded to hypothalamic TIA as the condition appeared in two short-term episodes and was completely reversible. Central diabetes insipidus following hypothalamic infarction or other lesions is well known as thalamus and hypothalamus are supplied by perforant arteries from the posterior cerebral artery [15,16].

Thirdly, it is atypical that both syndromes are completely reversible. It may be speculated that recovery occurred after increased perfusion of the brainstem by improved vascularization, collateralization and anticoagulant therapy. Another possible explanation for this positive course of the disease might be that the function of affected respiratory centers of the lower brainstem has been taken over by different structures, a phenomenon known as cerebral plasticity [17,18]. In addition, the positive outcome in our patient might be a consequence of anatomical variations in the brainstem's functional architecture as well as in its vascular supply. Cerebral angiography revealed a known anatomical variation of the vertebrobasilar system in our patient [19]. PICA has been found to be hyperplastic in combination with a hypoplastic or even absent connection from the vertebral artery to the basilar artery on the same side.

In conclusion when caring for patients with vertebrobasilar ischemia Ondine's curse should be considered as a possible clinical condition.

Probably, the bilaterality of the brainstem lesions as seen in MRI scan might be responsible for the occurrence and severity of Ondine's curse syndrome in our patient [8,20,21].

## References

- [1] Severinghaus JW, Mitchell RA. Failure of respiratory center automaticity while awake. *Clin Res* 1962;10:122.
- [2] Deonna T, Arczynska W, Torrado A. Congenital failure of automatic ventilation (Ondine's curse). *J Pediatr* 1974;84:710–4.
- [3] Auer RN, Rowlands CG, Perry SF, Remmers JE. Multiple sclerosis with medullary plaques and fatal sleep apnea (Ondine's curse). *Clin Neuropathol* 1996;15:101–5.
- [4] Lockwood AH. Shy-Drager syndrome with abnormal respiration and antidiuretic hormone release. *Arch Neurol* 1976;33:292–5.
- [5] Giangaspero F, Schiavina M, Sturani C, Mondini S, Cirignotta F. Failure of automatic control of ventilation (Ondine's curse) associated with viral encephalitis of the brainstem: a clinicopathologic study of one case. *Clin Neuropathol* 1988;7:234–7.
- [6] Jensen TH, Hansen PB, Brodersen P. Ondine's curse in listeria monocytogenes brain stem encephalitis. *Acta Neurol Scand* 1988;77:505–6.
- [7] Mukhopadhyay S, Wilkinson PW. Cerebral arteriovenous malformation, Ondine's curse and Hirschsprung's disease. *Dev Med Child Neurol* 1990;32:1087–9.
- [8] Beal MF, Richardson EP, Brandstetter R, Hedley-White ET, Hochberg FH. Localized brainstem ischemic damage and Ondine's curse after near-drowning. *Neurology* 1983;33:717–21.
- [9] Stern M, Erttmann R, Hellwege HH, Kuhn N. Total aganglionosis of the colon and Ondine's curse (letter). *Lancet* 1980;1(8173):877–8.
- [10] Minutillo C, Pemberton PJ, Goldblatt J. Hirschsprung's disease and Ondine's curse: further evidence for a distinct syndrome. *Clin Genet* 1989;36:200–3.
- [11] Vingerhoets F, Bogousslavsky J. Respiratory dysfunction in stroke. *Clin Chest Med* 1994;15:729–37.
- [12] Bogousslavsky J, Khurana R, Deruaz JP, Regli F, Janzer R, Perret C. Respiratory failure and unilateral caudal brainstem infarction. *Ann Neurol* 1990;28:668–73.
- [13] Yamada A, Kamoda M, Ikezoe K, Tsukaguchi M, Katanaka J, Deguchi K, Miki H, Takeuchi H. A case of central alveolar hypoventilation syndrome associated with cerebral infarction. *No To Shinkei* 1993;45:273–6.
- [14] Zakariadze TV. Undine and Erysichton syndrome in diabetes insipidus patients. *Problemy Tuberkuleza* 1983;7:70–1.
- [15] Rudelli R, Deck JH. Selective traumatic infarction of the human anterior hypothalamus. Clinical anatomical correlation. *J Neurosurg* 1979;50:645–54.
- [16] Lie TA. Congenital malformations of the carotid and vertebral arterial systems, including persistent anastomoses. In: Vinken PJ, Bruyn GW, editors. *Handbook of Clinical Neurology*. Vol. 12. *Vascular Diseases of the Nervous System*. Part II. Amsterdam: North Holland, 1972:289–339.
- [17] Grady MS, Jane JA, Steward O. Synaptic reorganization within the human central nervous system following injury. *J Neurosurg* 1989;71:534–7.
- [18] Johansson BB, Grabowski M. Functional recovery after brain infarction: plasticity and neural transplantation. *Brain Pathol* 1994;4:85–95.
- [19] Caplan LR. *Posterior Circulation Disease: Clinical Findings, Diagnosis, and Management*. Cambridge, Massachusetts: Blackwell Science, 1996:27–45.
- [20] Dooling EC, Richardson EP. Ophthalmoplegia and Ondine's curse. *Arch Ophthalmol* 1977;95:1790–3.
- [21] Feldman JL. Interactions between brainstem respiratory neurons. *Fed Proc* 1981;40:2384–8.

[1] Severinghaus JW, Mitchell RA. Failure of respiratory center