

## Cerebral venous sinus thrombosis associated with hepatic cirrhosis

Aneesh B. Singhal\*, Ferdinando Buonanno, Guy Rordorf

VBK 802, Department of Neurology, Massachusetts General Hospital, 55 Fruit Street, Boston, MA 02114, USA

Received 8 December 1998; received in revised form 24 August 1999; accepted 26 August 1999

### Abstract

Cerebral venous sinus thrombosis is not a recognized complication of end-stage liver disease. A case of sagittal sinus thrombosis in a 44-year-old male with end-stage hepatic cirrhosis is described. Recurrent seizures were the only manifestation. Work-up revealed severe deficiency of protein C, protein S, and antithrombin III. He was treated with low molecular weight heparin and underwent an orthotopic liver transplant after three months. Follow-up helical CT venogram showed resolution of the sinus thrombosis. © 1999 Elsevier Science B.V. All rights reserved.

*Keywords:* Cerebral venous sinus thrombosis; Cirrhosis; Protein C; Protein S; Antithrombin III; Spinal puncture; Low molecular weight heparin

### 1. Introduction

End-stage liver disease has been associated with thrombotic complications due to acquired deficiency of naturally occurring anticoagulants (e.g. protein C, protein S, and antithrombin III) [1]. However, cerebral venous sinus thrombosis (CVST) has rarely been associated with liver disease [2,3] and has not previously been related to the acquired anticoagulant factor deficiency in cirrhosis. There have been anecdotal reports of treatment of this condition with low molecular weight heparin [4]. We describe a patient with cirrhosis who developed CVST. He was treated with low molecular weight heparin and underwent an orthotopic liver transplant after three months. Follow-up CT venogram showed interval recanalization of the sinus.

### 2. Case report

A 44-year-old male with end-stage cirrhosis from chronic alcohol use and hepatitis C virus infection pre-

sented with grade II hepatic encephalopathy. Results of routine blood tests and lumbar puncture were normal. The encephalopathy was presumed to have resulted from dehydration due to recent excessive diuretic use; he improved with intravenous fluid treatment and was discharged on day three. On day five, he had a generalized tonic-clonic seizure with focal onset in the right leg. A non-contrast head CT scan was normal and he was treated with oral phenytoin sodium. However, he had recurrent secondarily generalized seizures on day six and day eight and was admitted. On exam he was afebrile, mildly icteric, and vital signs were normal. The abdomen was soft, without hepatosplenomegaly or ascites. Neurological exam was unremarkable. The white cell count was 6500/ $\mu$ l, hemoglobin 13.1 g/dl, platelets 63 000/ $\mu$ l, prothrombin time 17.8 (control 11.2–13.2), partial thromboplastin time 39.1 (control 22.1–34.1), sodium 130 mEq/l, potassium 4.6 mEq/l, BUN 15 mg/dl, creatinine 0.8 mg/dl, total bilirubin 7.2 mg/dl, alkaline phosphatase 113 U/l, alanine transaminase 42 U/l, lactate dehydrogenase 271 U/l, and Dilantin 5.3  $\mu$ g/ml. Magnetic resonance imaging (MRI) with gadolinium revealed a linear filling defect in the posterior and superior regions of the superior sagittal sinus (Fig. 1a). Although T-1, T-2, diffusion-weighted (DWI) and fluid attenuated inversion recovery (FLAIR) sequences

\*Corresponding author. Tel.: +1-617-726-8459; fax: +1-617-726-5043.

E-mail address: asinghal@partners.org (A.B. Singhal)

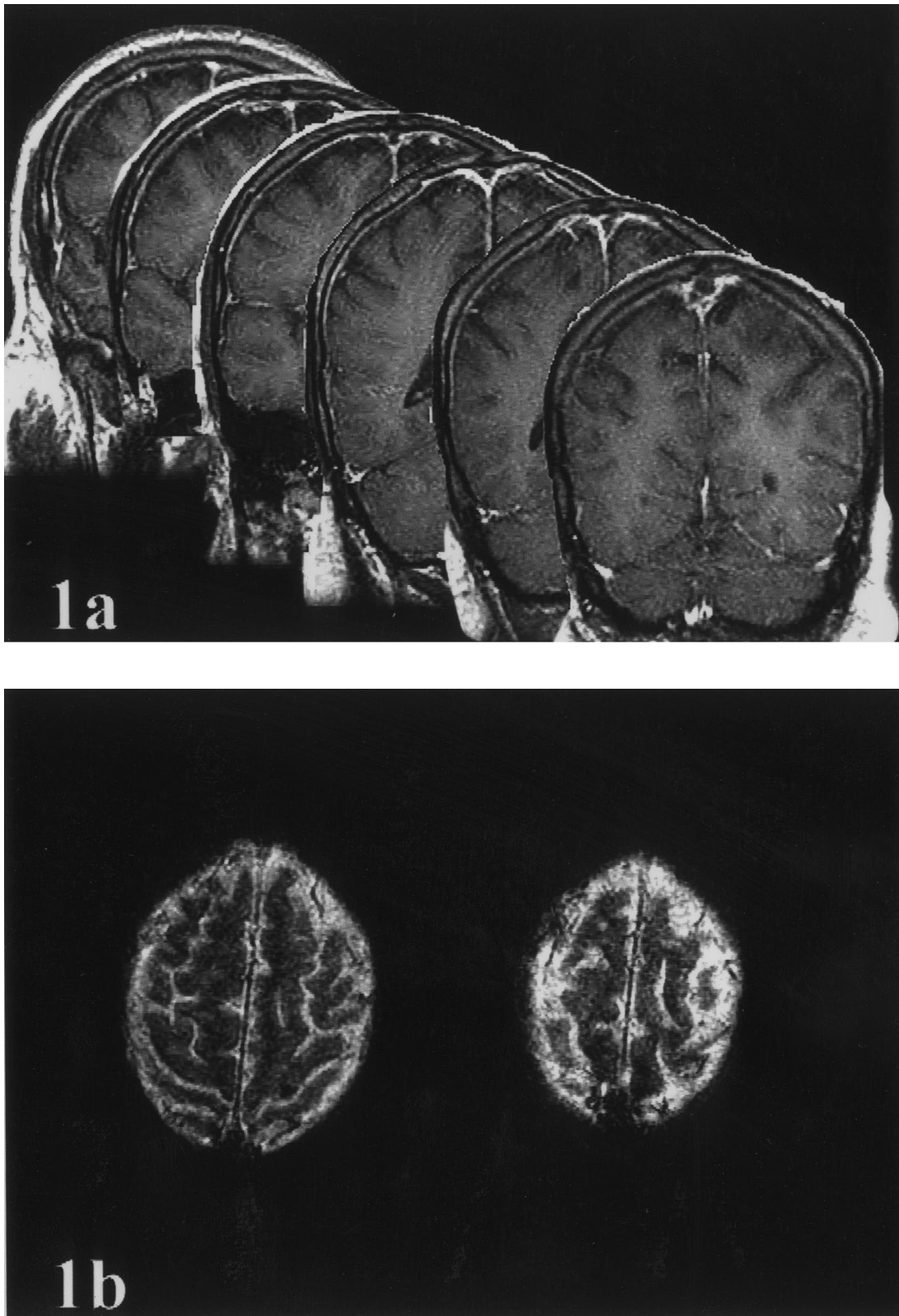


Fig. 1. MRI findings: (a) Gadolinium-enhanced coronal T-1 images, arranged postero-anteriorly, showing filling defects in the superior sagittal sinus compatible with thrombus. (b) Multi-planar gradient echo (MPGR) images, showing areas of increased susceptibility in the high parasagittal region.

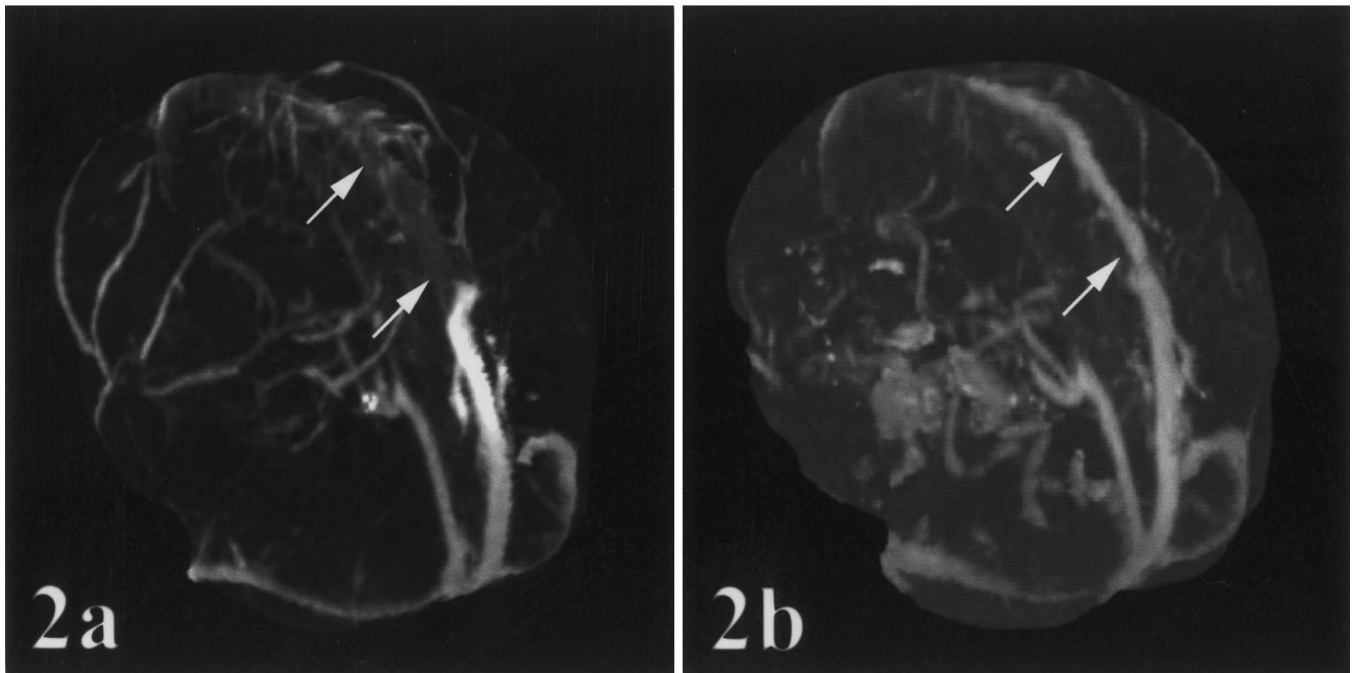


Fig. 2. Three-dimensional reconstruction of the CT venogram, posterior oblique views. (a) Initial study, showing non-opacification of the anterior and mid-portions of the superior sagittal sinus (arrows). (b) Follow-up image after treatment with low molecular weight heparin, showing opacification of the entire superior sagittal sinus (arrows).

were normal, multi-planar gradient echo (MPGR) MRI imaging revealed areas of increased susceptibility in the high parasagittal regions, possibly explaining the focal onset of seizures (Fig. 1b). Helical contrast-enhanced computerized tomogram (CT) with venogram confirmed the diagnosis of venous sinus thrombosis (Fig. 2a). A hypercoagulable screen revealed several abnormalities: protein C (functional) 18%, protein C (antigenic) 20%, protein S (functional) 23%, protein S (antigenic) 57%, antithrombin III (functional) 21%, antithrombin III (antigenic) 8.0 mg/dl (normal 22–39), factor VIII assay 204% (normal 50–200), and fibrinogen 85 mg/dl. Activated protein C resistance screen was normal, indicating absence of factor V Leiden mutation. PT and PTT mixing studies showed near complete correction, consistent with the factor deficiencies rather than inhibitors. Anticardiolipin IgG and IgM levels were 1.6 GPL and 5.8 MPL, respectively (normal 0–15). He was treated with low molecular weight heparin. He had no further seizures, and underwent a successful orthotopic liver transplant 90 days after his first seizure. A follow-up CT venogram four days after the liver transplant showed interval recanalization of the sagittal sinus (Fig. 2b).

### 3. Discussion

Prothrombotic disorders include congenital and acquired deficiencies of natural plasma anticoagulants (protein C, protein S, antithrombin III), Factor V Leiden mutation, and

the antiphospholipid antibody syndrome. CVST has been associated with a variety of conditions that predispose to prothrombotic states (e.g. pregnancy, ulcerative colitis, nephrotic syndrome, acquired immune deficiency syndrome, systemic lupus) [5–7]. Severe liver disease can also predispose to thrombosis due to impaired synthesis of natural plasma anticoagulants and has been associated with portal vein thrombosis, especially around the time of liver transplant [1]. However, CVST has rarely been described in patients with liver disease [2,3], and has not previously been associated with deficiency of protein C, protein S, or antithrombin III in patients with cirrhosis. To our knowledge, this is the first report of CVST associated with deficiency of natural anticoagulants due to hepatic cirrhosis.

The patient described had marked elevation of PT and PTT; however, the severe deficiency of protein C, protein S, and antithrombin III probably resulted in a shift of the overall hemostatic balance towards thrombosis. Besides severe anticoagulant factor deficiency, other factors may also have contributed to the development of venous thrombosis. The patient had recently been treated for probable dehydration, which has a strong association with CVST [5]. He suffered from chronic hepatitis C virus infection, which is known to have a prothrombotic effect in cirrhosis [8]. Lastly, he had undergone a lumbar puncture three days prior to his first seizure, and lumbar puncture has been implicated in precipitating CVST in patients with pregnancy, oral contraceptive use, and factor V Leiden mutation [9,10]. It would be difficult to quantify the role of

each of these contributing factors, but the severe deficiency of anticoagulant factors in this case suggests that it played a major etiologic role.

In patients with severe liver disease, seizures are commonly associated with alcohol withdrawal, subdural hematoma, and secondary infection. As demonstrated by our case, CVST should also be considered in the differential diagnosis of unexplained, recurrent, focal-onset seizures in patients with cirrhosis. Non-contrast CT scans may be normal and one may need to rely on contrast-enhanced CT venogram or MRI for diagnosis.

Anticoagulation is now the accepted mode of treatment of CVST, and intravenous heparin followed by oral warfarin is the usual regimen followed. Low molecular weight heparin has been used anecdotally in CVST [4]. Since the patient described was first on the waiting list for liver transplant, low molecular weight heparin was chosen as the method of anticoagulation. The sagittal sinus completely recanalized within three months, possibly proving the efficacy of this form of treatment. It is conceivable that orthotopic liver transplant (by correcting the dysregulated coagulation) also had a therapeutic role. However, protein C levels are known to fall in the immediate postoperative period following liver transplant, giving rise to a brief period of hypercoagulability [1]. Treatment with anticoagulant factors and heparin has been advocated to prevent thrombosis in this situation. In this case, the follow-up scan was performed only four days after surgery and showed resolution of the sagittal sinus thrombosis, thereby favoring the therapeutic role of heparin.

In conclusion, this case demonstrates that CVST may complicate end-stage liver disease as a result of acquired deficiency of natural plasma anticoagulants. Dehydration and lumbar puncture may be precipitating factors. The presence of unexplained new or recurrent focal onset

seizures in a patient with cirrhosis must prompt an aggressive search for CVST. Low molecular weight heparin may be an effective treatment modality.

## References

- [1] Harper PL, Edgar PF, Luddington RJ, Seaman MJ, Carrell RW, Salt AT, Barnes N, Rolles K, Calne RY. Protein C deficiency and portal thrombosis in liver transplantation in children. *Lancet* 1988;2(8617):924–7.
- [2] Boita F, Garnier D, Boutad P, Patte F, Lefevre JP, Beauchant G. Scattered arteriovenous fistulae of the lung associated with alcoholic cirrhosis: about one case complicated by neurological involvement. *Sem Hosp Paris* 1979;55(9–10):499–502.
- [3] Kesler A, Pomeranz I, Huberman M, Novis B, Kott E. Cerebral venous thrombosis and chronic active hepatitis as part of the antiphospholipid syndrome. *Postgrad Med J* 1996;72(853):690–2.
- [4] Hauser D, Barzilai N, Zalish M, Oliver M, Pollack A. Bilateral papilledema with retinal hemorrhages in association with cerebral venous sinus thrombosis and paroxysmal nocturnal hemoglobinuria. *Am J Ophthalmol* 1996;122(4):592–3.
- [5] Bousser MG, Russel RR. Causes. In: *Cerebral venous thrombosis*, WB Saunders, 1997, p. 48.
- [6] Daif A, Awada A, al-Rajeh S, Abduljabbar M, al-Tahan AR, Obeid T, Malibary T. Cerebral venous thrombosis in adults. A study of 40 cases from Saudi Arabia. *Stroke* 1995;26(7):1193–5.
- [7] Iranzo A, Domingo P, Cadafalch J, Sambeat MA. Intracranial venous and dural sinus thrombosis due to protein S deficiency in a patient with AIDS. *J Neurol Neurosurg Psychiatry* 1998;64:688–94.
- [8] Violi F, Ferro D, Basili S, Artini M, Valesini G, Levrero M, Cordova C. Increased rate of thrombin generation in hepatitis C virus cirrhotic patients. Relationship to venous thrombosis. *J Investig Med* 1995;43(6):550–4.
- [9] Ravindran RS, Zandstra GC, Viegas OJ. Postpartum headache following regional anesthesia: a symptom of cerebral venous thrombosis. *Can J Anaesth* 1989;36:705–7.
- [10] Wilder-Smith E, Kothbauer-Margreiter I, Lammle B, Sturzenegger M, Ozdoba C, Hauser SP. Dural puncture and activated protein C resistance: risk factors for cerebral venous sinus thrombosis. *J Neurol Neurosurg Psych* 1997;63(3):351–6.