

Short communication

Motor neglect following left thalamic hemorrhage: a case report

Yasuhiro Manabe^{a,*}, Kenichi Kashihara^a, Taisei Ota^b, Toshikiyo Shohmori^a, Koji Abe^a

^aDepartment of Neurology, Okayama University Medical School, Okayama, Japan

^bDepartment of Neurology, Ota Memorial Hospital, Fukuyama, Japan

Received 3 September 1998; received in revised form 31 August 1999; accepted 1 September 1999

Abstract

We present a report on a patient who developed unilateral motor neglect of the right hemibody after a left thalamic hemorrhage. He presented with pure motor neglect without aphasia, ideomotor apraxia, or unilateral spatial neglect due to a lesion in the centromedian parafascicular (CMPF) and ventrolateral (VL) nuclei of the left thalamus. Although unilateral motor neglect is usually associated with right hemispheric lesions, a left thalamic lesion may also result in isolated motor neglect. © 1999 Elsevier Science B.V. All rights reserved.

Keywords: Unilateral motor neglect; Left thalamic hemorrhage

1. Introduction

Unilateral motor neglect is characterized by an under utilization of one side of the body without defects of strength, reflexes or sensibility [1]. The lesions underlying unilateral motor neglect have been ascribed to various topographic sites of the brain such as the parieto-temporal cortex [1], frontal cortex [2], anterior limb of the internal capsule [3], thalamus [4], and ventrolateral nucleus of the thalamus [5]. However, the above regions are usually located in the right cerebral hemisphere, and unilateral motor neglect following a lesion of the left thalamus is very rare. We report here a patient who developed unilateral motor neglect of the right hemibody after a left thalamic hemorrhage.

2. Case history

A 43-year-old right-handed man had sudden mild right hemiparesis. He had suffered from hypertension for two years. When admitted to a local hospital, the general physician found him alert with normal speech and no other symptoms other than mild right hemiparesis. A CT scan 5 h after onset showed an intracerebral hematoma in the left thalamus (Fig. 1a). The general physician noticed his underutility of the right hand and leg four days after the hemorrhage. When he was transferred to our hospital six months later, he was alert and well oriented. The cranial nerves were intact, and muscle power and sensation were normal and symmetrical. Deep tendon reflexes were normal and plantar responses were extensor bilaterally.

Upon neuropsychological examination, a marked reduction of the free gesture of the right upper extremity was noted during the conversation. In ordinary bimanual motor activities such as eating or dressing, the patient failed to use the right hand or merely made the beginning of the appropriate gesture. When lying in bed, his right arm was in an awkward position behind the body or hanging out of the bed. Underutility of the right leg was also noted. In contrast, when the examiner actively encouraged the patient to use his right arm, the under utilization markedly

Abbreviations: CMPF, centromedian parafascicular; CT, computed tomography; MRI, magnetic resonance imaging; PET, positron emission tomography; SPECT, single photon emission computed tomography; VL, ventrolateral

*Corresponding author. Tel.: +81-86-235-7365; fax: +81-86-235-7368.

E-mail address: manabe@cc.okayama-u.ac.jp (Y. Manabe)

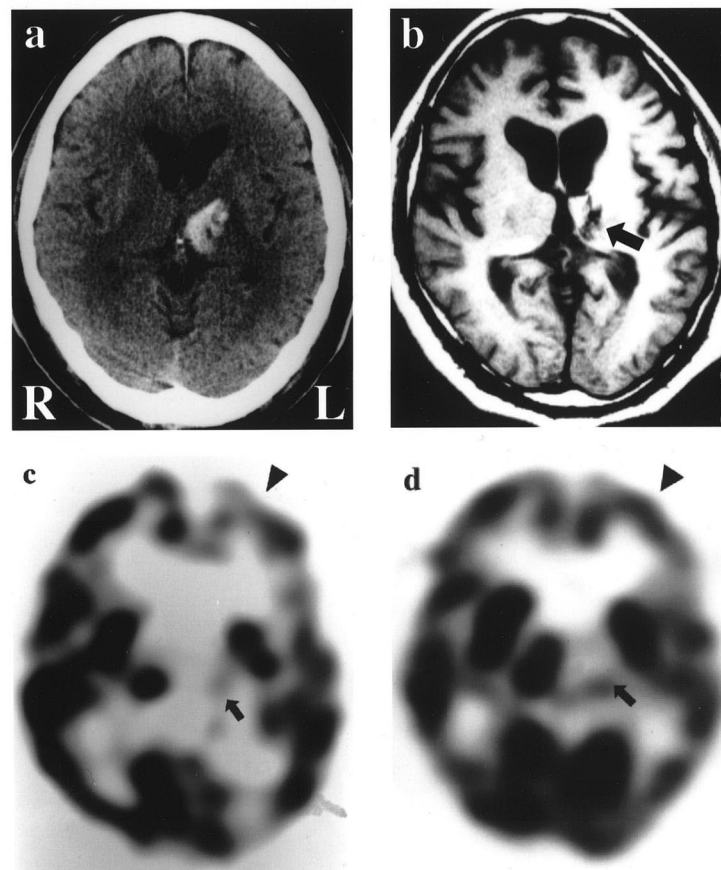


Fig. 1. (a) Plain CT 5 h after onset showing high density area in the left thalamus. (b) T1 weighted axial MR image 6 months after onset showing a hypointensity in the left thalamus (arrow). (c) SPECT image with ^{123}I -IMP showing a complete perfusion defect in the left thalamus (arrow) with a slight reduction of perfusion in the left frontal lobe (arrowhead). (d) SPECT image 15 months after onset showing an improvement of the hypoperfusion in the left frontal lobe (arrowhead), but not in the thalamus (arrow).

improved to almost normal levels of strength and movement. Neither aphasia, ideomotor apraxia nor anosognosia were observed. No unilateral spatial neglect was found upon performing the following tasks: complex image description, tridimensional constructive praxia, clock, and room drawing. Motor neglect began to improve approximately eleven months after the onset of the thalamic bleeding. Fourteen months later, bimanual motor activity was almost normal, although clinical examination still revealed slight under utilization of the right arm and leg. Repeated neurological examinations showed the disappearance of motor neglect over the next 17 months.

MR imaging six months after onset showed evidence of left thalamic lesion. A detailed examination of MRI abnormality in the axial slice revealed that the lesion exhibited hypointense signals on T1 and T2 weighted images which are the ventrolateral and intralaminar portions of the thalamus including the parafascicular and the centromedian nuclei (Fig. 1b, arrow). Eleven months after the hemorrhage, single photon emission computed tomography (SPECT) using ^{123}I -IMP showed a complete perfusion defect in the left thalamus (Fig. 1c, arrow) with a slight reduction of perfusion in the left frontal lobe (Fig.

1c, arrowhead). Fifteen months after the hemorrhage, SPECT showed an improvement of the hypoperfusion in the left frontal lobe (Fig. 1d, arrowhead), while left thalamic blood flow did not improve (Fig. 1d, arrow). The Wechsler Adult Intelligence Scale test gave the low full scale intelligence quotient of 67 with verbal and performance quotients of 76 and 64, respectively. This score was similar to one obtained from a test given before the hemorrhage.

3. Discussion

In general, motor neglect is thought to be a defect of intention from an arousal–attention mechanism resulting from disruption of the cortical network involved in conscious awareness [6]. This network is composed of right hemispheric local components including the parietal and frontal cortices, cingulate gyrus, mesencephalic reticular formation, ventrolateral thalamus, and intralaminar thalamic nuclei [7–9]. Lesions in only one component of this network yield partial unilateral motor neglect. In the present case, CT and MR imagings showed a left thalamic

legion (Fig. 1a,b). SPECT revealed reduced perfusion of the left frontal lobe (Fig. 1c, arrowhead) in addition to a complete perfusion defect in the left thalamus (Fig. 1c, arrow), suggesting reduced neuronal activity in the left frontal cortex due to diaschisis from the primary thalamic lesion. We speculate that the reduction of ipsilateral frontal cortical activity may be the main cause of motor neglect in the present case. Reduced cerebral cortical perfusion demonstrated by SPECT improved along with the patient's recovery from motor neglect, while thalamic blood flow did not (Fig. 1d). In general, the supplementary motor area, premotor area or posterior inferior parietal area is recognized as responsible for motor neglect [6]. Cerebral cortical perfusion was reduced in both the supplementary and premotor areas in the present case.

Thalamic lesions causing motor neglect were located in the right side in the majority of previous reports [10,11], and only two cases of left thalamic lesion have been reported [12,13] since Castaigne first described pure motor neglect in 1970 (Table 1). De la Sayette et al. [12] mentioned one case of right motor neglect, amnesia, aphasia and loss of drive following bilateral thalamic and subthalamic infarctions. Von Giesen et al. [13] described a case of left thalamic hemorrhage causing right motor neglect and amnesic aphasia. These two previous cases also revealed reduction of frontal and parietal activity in positron emission tomography (PET). We speculate that the reduction of cerebral cortical blood flow in the supplementary and premotor areas contributed significantly to right motor neglect following the left thalamic lesion. Our patient is symptomatically noteworthy because he presented pure motor neglect due to a lesion in the left thalamus without aphasia, ideomotor apraxia, or unilateral spatial neglect. Although it is not clear whether a hemorrhagic or ischemic lesion in the thalamus would produce more cortical hypoperfusion, the left thalamic lesion may

be associated with isolated motor neglect without evident motor weakness or signs of sensory impairment.

References

- [1] Castaigne P, Laplane D, Degos JD. Trois cas de négligence motrice par lésion rétro-rolandique. *Rev Neurol Paris* 1970;122:233–42.
- [2] Castaigne P, Laplane D, Degos JD. Trois cas de négligence motrice par lésion pré-rolandique. *Rev Neurol Paris* 1972;126:5–15.
- [3] De la Sayette V, Bouvard G, Eustache F, Chapon F, Rivaton F, Viader F, Lechevalier B. Infarct of the anterior limb of the right internal capsule causing left motor neglect: case report and cerebral blood flow study. *Cortex* 1989;25:147–54.
- [4] Laplane D, Escourolle R, Degos JD, Sauron B, Massion H. La négligence motrice d'origine thalamique. A propos de deux cas. *Rev Neurol Paris* 1982;138:201–11.
- [5] Zoll JG. Transient anosognosia associated with thalamotomy: Is it caused by proprioceptive loss? *Confin Neurol* 1969;31:48–55.
- [6] Heilman KM, Van den Abell T. Right hemisphere dominance for attention: The mechanism underlying hemispheric asymmetries of inattention (neglect). *Neurology* 1980;30:327–30.
- [7] Laplane D, Degos JD. Motor neglect. *J Neurol Neurosurg Psychiatry* 1983;46:152–8.
- [8] Mesulam MM. Large-scale neurocognitive networks and distributed processing for attention, language, and memory. *Ann Neurol* 1990;28:597–613.
- [9] Watson RT, Heilman KM. Thalamic neglect. *Neurology* 1979;29:690–4.
- [10] Laplane D, Baulac M, Carydakis C. Négligence motrice d'origine thalamique. *Rev Neurol Paris* 1986;142:375–9.
- [11] Schott B, Laurent B, Manguiere F, Chazot G. Négligence motrice par hématorne thalamique droit. *Rev Neurol Paris* 1981;137:447–55.
- [12] De la Sayette V, Le Doze F, Bouvard G, Marin I, Eustache F, Fiorelli M, Viader F, Morin P. Right motor neglect associated with dynamic aphasia, loss of drive and amnesia: case report and cerebral blood flow study. *Neuropsychologia* 1992;30:109–21.
- [13] Von Giesen HJ, Schlaug G, Steinmetz H, Benecke R, Freund H-J, Seitz RJ. Cerebral network underlying unilateral motor neglect: evidence from positron emission tomography. *J Neurol Sci* 1994;125:29–38.

Table 1
Three cases with right unilateral motor neglect by left thalamic lesion^a

Case	Sex	Age (years)	Lesion of left thalamus	Other cortical symptoms	Cerebral blood flow reduction in SPECT or PET	References
1	M	30	DM VL	Amnesia Aphasia	lt. thalamus (moderate) lt. frontal lobe (slight) lt. parietal lobe (slight)	De la Sayette et al. [12]
2	M	73	CMPF VL	Amnesia Aphasia	lt. thalamus (moderate) lt. frontal lobe (moderate) lt. parietal lobe (slight)	Von Giesen et al. [13]
3	M	43	CMPF VL	None	lt. thalamus (loss) lt. frontal lobe (slight)	Present case 1999

^a DM: dorsomedial; CMPF: centromedian parafascicular; VL: ventrolateral; SPECT: single photon emission computed tomography; PET: positron emission tomography.