

## Myocardial infarction, seizure and an abnormal head CT scan

Nithianandam Selvaraj, David A Drachman, Paula Ravin, John R Knorr

A 60-year-old woman was admitted with acute substernal chest pain. Electrocardiographic findings and creatine kinase values were consistent with an acute anteroseptal myocardial infarction. She underwent a coronary angiogram and percutaneous transluminal coronary angioplasty (PTCA) with stent placement. Two hours following the procedure, the patient developed right-sided partial motor seizures with secondary generalisation. A head computed tomography (CT) scan was obtained immediately to rule out a stroke.

Her medical history was significant for coronary heart disease, hypertension, asthma and seizures. Her last seizure was almost 10 years ago. She had taken an anti-epileptic medication in the past and had stopped it on her doctor's advice. There was also a remote history of alcohol and intravenous drug abuse. Prior to this admission, she was taking zestril, metoprolol, bupropion for smoking cessation, premarin, and steroid inhalers. After admission, she received aspirin, ticlid, intravenous nitroglycerin and abciximab (ReoPro). Abciximab was started during her PTCA.

When examined four hours after her seizure, she was alert and oriented. Her speech and language functions were normal. Cranial nerve examination did not reveal any abnormalities. On motor testing, she was noted to have a right pronator drift. Her muscle strength was entirely normal. Sensation was preserved throughout. Muscle stretch reflexes were 2+ and symmetrical. Babinski sign was present on the right side. The left plantar reflex was normal. Coordination was intact. No signs of meningeal irritation were present.

University of  
Massachusetts Medical  
Center, 55 Lake  
Avenue North,  
Worcester, MA 01655  
USA  
Department of  
Neurology  
N Selvaraj  
D A Drachman  
P Ravin  
Department of  
Radiology  
(Neuroradiology)  
J R Knorr

Accepted 14 May 1999

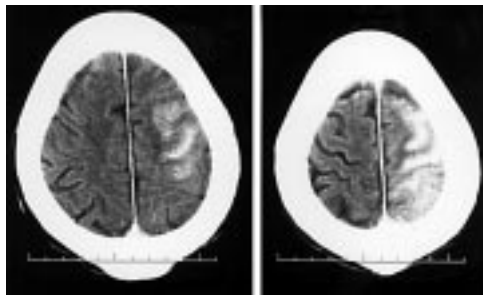


Figure 1 CT scan

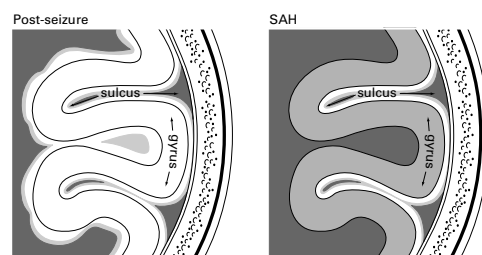
### Questions

- 1 What is the radiological diagnosis, taking into account the patient's hospital course?
- 2 What are the possible aetiologies of her seizure?
- 3 What is the further management?

## Answers

### QUESTION 1

The CT scan of the head shows hyperdensity involving the left cerebral hemisphere. Although this was meant to be an unenhanced CT, the fact that the patient had received a contrast agent (Hypaque) for her coronary angiography makes this CT, in fact, a contrast-enhanced study. It is important to recognise this when interpreting the abnormal findings. To the inexperienced eye this may look like subarachnoid haemorrhage or a haemorrhagic cerebral infarction. On close examination, however, it is evident that the hyperdensity involves mainly the white matter rather than filling the sulci (see figure 2).



**Figure 2** As shown in this schematic diagram, the CT appearance in our patient is not subarachnoid haemorrhage (SAH) because the hyperdensity mainly occupies the gyri and not the sulci

The absence of sulcal enhancement and the absence of blood in the interpeduncular cistern makes the diagnosis of subarachnoid haemorrhage unlikely. As the lesion does not correspond clearly to a vascular territory and has both diffuse white matter and cortical involvement, the diagnosis of a haemorrhagic infarct is less likely. Furthermore, the radiographic findings are out of proportion to the patient's relatively normal neurological status. This also has to be taken into account when interpreting the abnormal CT findings.

### QUESTION 2

The aetiology of the seizures in this patient is unclear. The differential diagnosis is shown in the box.

#### Differential diagnosis

- contrast medium-induced seizure
- relapse of a pre-existing seizure disorder
- bupropion-induced seizures
- abciximab-induced seizures

The patient had a history of generalised seizures many years ago. She has been seizure-free for at least 10 years without any medications; in

the past seizures may have been related to alcohol withdrawal. Hence, it is unclear if this seizure was related to the history of seizures.

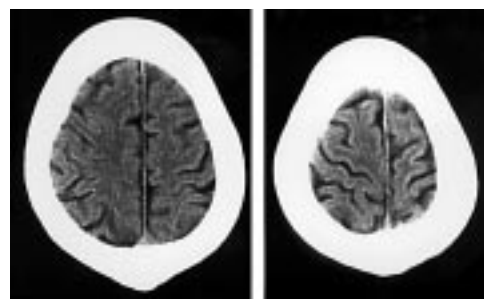
Bupropion is known to cause seizures in 0.1–0.4% of patients taking the drug. The risk in patients with a history of seizures may be even higher. We do not know if the drug was causally related to the current episode.

Abciximab (ReoPro) is being used increasingly in cardiac patients. It is the Fab fragment of the chimeric human–murine monoclonal antibody 7E3. It binds to the glycoprotein IIb/IIIa receptor of human platelets and inhibits platelet aggregation. It is used as an adjunct to PTCA for the prevention of acute cardiac ischaemic complications. Nervous system side-effects reported include cerebral ischaemia (0.3%) and coma (0.4%). Although it is theoretically possible that cerebral ischaemia can predispose to seizures in patients taking abciximab, seizures have not been reported with the use of this drug.

Neurotoxicity from intravascular contrast, in particular the ionic high-osmolar agents has been described previously. Contrast medium-induced seizures are also well described in the literature and it is probably the most likely aetiology for seizures in our patient, although a combination of mechanisms is possible.

### QUESTION 3

One reasonable approach would be to monitor the patient clinically and if her neurological status did not change, repeat a non-contrast CT in 24 hours. In our patient, a non-contrast CT repeated the next day (figure 3) was entirely normal.



**Figure 3** Non-contrast CT scan

The hyperdensity noted in the initial CT had completely disappeared. The minor residual neurological deficits noted post-ictally (Todd's paralysis) completely resolved over 24 hours. As the CT changes were unilateral, we presumed that the ictal activity originated from the left hemisphere. However, an electroencephalogram (EEG) obtained to look for a left hemispheric focus was completely normal. The patient was discharged home after her cardiac status was stable. Phenytoin treatment was begun as the aetiology of her seizures was unclear, pending further evaluation.

## Discussion

Contrast-enhanced CT scans of the brain obtained on patients soon after seizures are often abnormal. The changes on CT may be either hypodensities or hyperdensities. Various authors have described reversible radiographic signs after seizures.<sup>1-3</sup> All these changes typically disappear over time, most within 1–2 weeks. The underlying mechanism is believed to be a transient disruption of the blood–brain barrier (BBB).

*In vitro* studies have shown that both electrically and pharmacologically induced seizures cause transient breakdown of the BBB.<sup>4</sup> During prolonged seizure activity, BBB disruption leads to increased water content in brain tissue (cerebral oedema), especially in the hypothalamus and hippocampus. Both local and systemic changes account for the cerebral oedema. Relative hypoxia due to increased ictal metabolism, with an increase in local pCO<sub>2</sub> and lactate, results in local vasodilatation and loss of autoregulation.<sup>5</sup> Systemically there is an increase in blood pressure and decrease in blood pH, again resulting in decreased cerebral autoregulation and local hyperaemia.<sup>6</sup> It has also been reported that the degree of disruption of the BBB is proportional to the duration of seizure activity. Systemic hypertension during seizures, in combination with disrupted BBB, can lead to cerebral oedema, causing hypodense lesions and, in the presence of contrast agents, abnormal-appearing hyperdensities on CT scanning.

Sage and colleagues have demonstrated increased permeability of the BBB after large intracarotid contrast injections.<sup>7</sup> Scott has previously reported that intravenous administration of contrast material for head CT may precipitate generalised seizures, especially in cases of metastatic neoplasm of the brain.<sup>8</sup>

Neurologic complications after cardiac catheterisation are well known. Contrast agent neurotoxicity presenting with focal seizures with CT head findings similar to subarachnoid haemorrhage has also been reported.<sup>9</sup> Contrast-medium-induced seizures are well described in the literature and their incidence has been reported to be about 0.2–0.5%.<sup>10</sup> They are typically self-limiting and do not require prolonged anticonvulsant treatment.

In our patient, the hyperdensity noted in the CT done soon after the seizure was probably due to leakage of contrast agent through the disrupted BBB. It does not indicate a cerebral infarction or haemorrhage. The patient's relatively intact neurological status and the resolution of the abnormalities on CT within 24–48 hours confirm our conclusions. The unilateral CT changes make one wonder if the ictal activity originated from the left hemisphere. However, an EEG performed 32–48 hours after the ictus failed to reveal any left hemispheric seizure focus. It is arguable that the EEG might have shown an abnormality if the study had been done soon after the ictus.

It is important to be aware of this possibility when interpreting abnormal CT scans performed soon after seizures. Failure to recognise this may lead to erroneous diagnosis and unwarranted expensive investigations. Proper diagnosis is not only cost-effective but will also avoid unnecessary distress both for the patient and the physician.

## Final diagnosis

Anteroseptal myocardial infarction, contrast medium-induced seizure, and false-positive CT abnormalities due to post-seizure disruption of the blood–brain barrier.

**Keywords:** seizure; myocardial infarction; blood–brain barrier; contrast media

1 Goulatia RK, Verma A, Mishra NK, *et al*. Disappearing CT lesions in epilepsy. *Epilepsia* 1987;28:523–7.

2 Clarke HB, Gabrielson TO. Seizure induced disruption of the Blood brain barrier demonstrated by CT. *J Comput Assist Tomogr* 1989;13:889–92.

3 Kramer RE, Luders H, Lesser RP, *et al*: Transient focal abnormalities of neuroimaging studies during focal status epilepticus. *Epilepsia* 1987;28:528–32.

4 Lee JC, Olszewski J. Increased cerebrovascular permeability after repeated electroshocks. *Neurology* 1961;11:515–9.

5 Lee SH, Goldberg HI. Hypervascular pattern associated with idiopathic focal status epilepticus. *Radiology* 1977;125:159–63.

6 Plum F, Posner JB, Troy B. Cerebral metabolic and circulatory responses to induced convulsions in animals. *Neurology* 1968;18:13.

7 Sage MR, Drayer BP, Dubois RJ, *et al*. Increased permeability of brain blood barrier after carotid Renografin 76. *Am J Neuroradiol* 1981;2:272–4.

8 Scott WR. Seizures: a reaction to contrast media for computed tomography of the brain. *Radiology* 1980;137:359.

9 Sharp S, Stone J, Beach R. Contrast agent neurotoxicity presenting as subarachnoid hemorrhage. *Neurology* 1999;52:1503–5.

10 Nelson M, Bartlett RJV, Lamb JT. Seizures after intravenous contrast media for cranial computed tomography. *J Neurol Neurosurg Psychiatry* 1989;52:1170–5.