

Aggravation of Poststroke Sensory Symptoms after a Second Stroke on the Opposite Side

Jong S. Kim

Department of Neurology, University of Ulsan, Asan Medical Center, Seoul, Korea

Key Words

Sensation · Pain · Contralateral · Cerebrovascular disease · Central poststroke pain

Abstract

The role of the ipsilateral hemisphere in sensory functions remains unknown. The author describes 5 patients who presented with hemisensory symptoms due to unilateral strokes occurring in the left putamen, left thalamus, right putamen, right lateral medulla and left thalamic-internal capsular area, respectively. Sensory symptoms had gradually improved or remained stable after the initial events. However, when another stroke occurred on the contralateral thalamic-occipital, frontoparietal, lateral medulla, temporoparietal and pontine areas, respectively, previous sensory symptoms significantly worsened and became painful. These observations suggest that ipsilateral sensory pathways play a role in the modulation of sensory functions.

Copyright © 1999 S. Karger AG, Basel

Sensory symptoms usually, though not always [1, 2], occur on the side contralateral to the brain lesions. In this report, the author describes 5 patients with hemisensory symptoms due to unilateral strokes that improved to some extent. When another stroke occurred in the contra-

lateral hemisphere, the previous sensory symptoms worsened. The patients are briefly described below and summarized in table 1.

Report of Patients

Patient 1

A 64-year-old hypertensive woman suddenly developed right hemiparesis. On examination, she had dysarthria, right facial palsy and flaccid hemiplegia. Sensation was normally perceived, but she had paresthesias in the right limbs. Brain CT showed a left putaminal hemorrhage (fig. 1, A1). Motor power gradually improved to II/V (arm) and IV/V (leg), but mild paresthesias remained in the right limbs, more marked in the leg. Three months later, she developed left hemiparesis. Examination also showed left homonymous hemianopia. In addition, the motor deficit of the right limbs was found to be worsened to I/V (arm) and III/V (leg). Sensations of pinprick, cold, vibration and position were moderately decreased on the left side including the face. Objective sensation remained intact in the right limbs, and no dysesthesias were noted. Surprisingly, however, she started to complain of 'squeezing' painful paresthesias over the right hemibody, most marked in the leg. She had never described the paresthesias as 'painful' before. Although the right limbs became more spastic than before, rotation of her joints did not aggravate the pain. Brain CT showed an old left putaminal hemorrhage and a new infarct involving the right thalamus and the temporo-occipital area (fig. 1, B1). Amitriptyline (75 mg/day) and carbamazepine (600 mg/day) partially relieved the pain. Ten months later, when she was last followed up, she remained bed-ridden, but the pain was so far relieved as not to require medication.

Fig. 1. A Images indicating previous strokes. **B** Images indicating secondary strokes. **A1** Patient 1. CT shows a left putaminal hemorrhage. **B1** CT shows new infarcts on the right temporo-occipital area and thalamus. Left paraventricular lesion indicates old stroke (far right image). **B2** Patient 2. CT shows an old stroke in the left thalamus (left image) and a new hemorrhage in the right frontoparietal cortical-subcortical area (right image). **A3** Patient 3. T₂-weighted MRI shows a hemorrhage in the right putamen. **B3** An infarct is shown in the left lateral medulla. **A4** Patient 4. T₂-weighted MRI shows infarcts in the right lateral medulla and the cerebellum. **B4** CT shows an infarct in the left temporoparietal cortex. **A5** Patient 5. T₂-weighted MRI shows an infarct in the left posterior thalamus-internal capsular area. **B5** T₂-weighted MRI shows paramedian right pontine infarct.

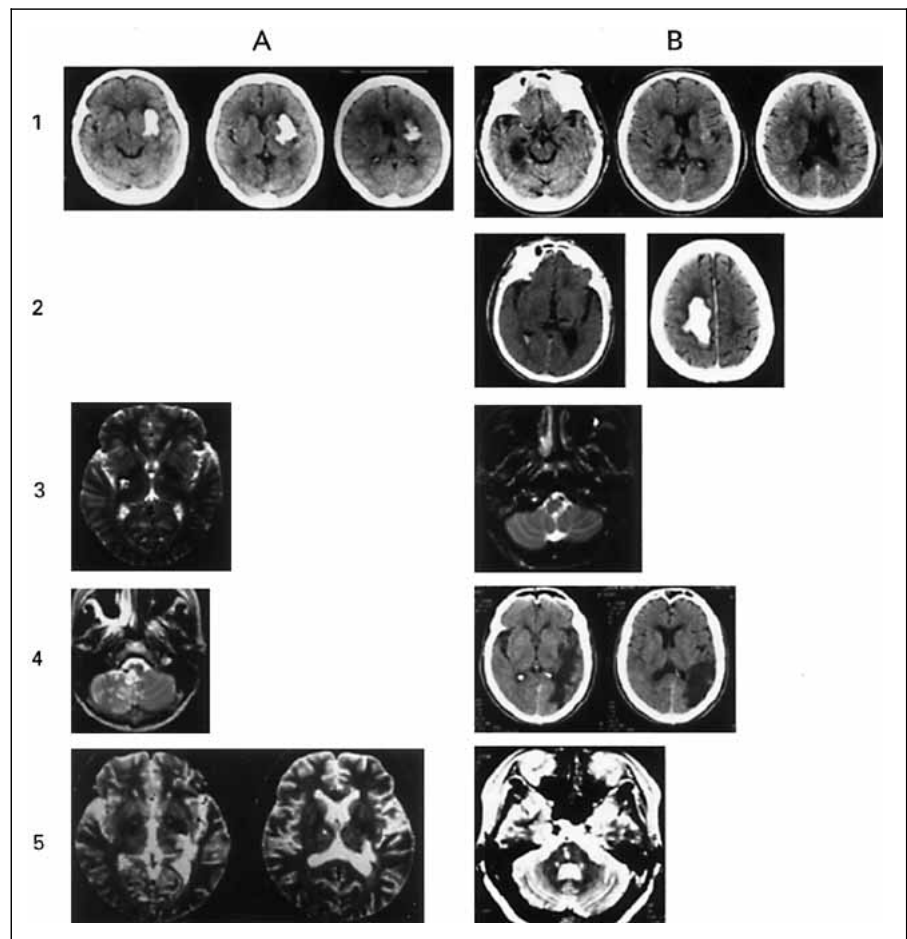


Table 1. Demography and clinical features of the patients

No./sex/ age ¹	Initial lesion/ nature	Initial symptom/sign	Interval months	Secondary lesion/ nature	New symptom/ sign	Worsened previous symptom/sign
1/F/64	lt. putamen hem.	rt. motor, sensory	3	rt. thalamus, occ. inf.	lt. motor, sensory, visual field	motor, spasticity, sensory (requires new pain medication)
2/M/68	lt. thalamus ?	rt. motor, sensory	84	rt. frontoparietal hem.	lt. motor	motor, spasticity, sensory (requires new pain medication)
3/M/39	rt. putamen hem.	lt. motor, sensory	20	lt. lateral medulla inf.	vertigo, ataxia, nystagmus	sensory (lesser effect on current medication)
4/F/70	rt. lateral medulla cerebellum	ataxia, dysphagia, nystagmus, lt. sensory bilateral facial sensory	26	lt. temporoparietal inf.	aphasia	sensory (requires previously withdrawn pain medication)
5/F/53	lt. thalamus, internal capsule inf.	rt. motor, sensory, visual field	12	rt. pons inf.	lt. motor, sensory	sensory (requires new pain medication)

Lt. = Left; rt. = right; hem. = hemorrhage; inf. = infarction; occ. = occipital.

¹ Age at the time of first stroke.

Patient 2

A 68-year-old hypertensive man suddenly developed right hemiparesis. Detailed initial neurological findings were unavailable, but he gradually recovered and became able to walk with slight limping. He also had mild residual paresthesias on the right side. Seven years later, he developed sudden left hemiparesis. Examination revealed marked dysarthria, dysphagia and dense, flaccid left hemiplegia. Motor power of the right limbs was IV/V (arm) and III/V (leg), which, according to the patient and his family, had worsened. The right limbs were spastic, and a Babinski sign was present on both sides. Sensations on the left were apparently normal. Compared to the left side, the senses of pinprick, cold, vibration and position were moderately decreased on the right. He also complained of severe and constant pain (described as 'squeezing' or 'markedly numb') in the right hemibody. Rotating his joint in the right limb provoked pain, but the painful paresthesias were largely unrelated to the joint pain. Brain MRI showed an old infarct in the left thalamus and a new hemorrhage in the right frontoparietal lobe (fig. 1, B2). His pain was partially relieved by amitriptyline (75 mg/day) and carbamazepine (400 mg/day). Spasticity of the right limbs, improved with baclofen (15 mg/day), which, however, did not alleviate the pain. Six months later, the sensory symptom was milder in the right limbs and the painful paresthesias much improved.

Patient 3

A 39-year-old hypertensive man suddenly developed hemiparesis and paresthesias in the left half of his body including the face. Detailed neurological findings were unavailable. The weakness gradually improved but there remained paresthesias in the left half of his body and limbs. Eight months later, when he was referred to the author, his muscle strength was normal and sensations of pinprick, vibration and touch were mildly (about 90% of the intact side) decreased in the left half including the face. Brain MRI showed an old right putaminal hemorrhage (fig. 1, A3). He was given carbamazepine (300 mg/day) and amitriptyline (20 mg/day), and there remained persistent but mild tingling sensations. Twenty months after the onset of the first stroke, he suddenly developed headache, vertigo and gait ataxia. On examination, he exhibited right-beating nystagmus, left-sided gait ataxia and a Horner sign on the left. On the left side of the face and hemibody, pinprick, temperature and touch senses were decreased to roughly 50% of the right side. He stated that the paresthesias on the left were much worse even though he continued to take the same medications. Brain MRI revealed a new infarct in the left posterolateral medulla (fig. 1, B3), and angiogram showed an occlusion of the left posterior inferior cerebellar artery. His vertigo and gait ataxia rapidly resolved, while his sensory signs improved slowly. Three weeks later, the sensation was only slightly (90% of the normal side) decreased in the left face and body/limbs. The patient reported that although the paresthesias had also improved, they were still worse than previously. His symptoms remained persistent when he was last followed up 4 years later.

Patient 4

A 70-year-old woman with a history of coronary heart disease suddenly developed vertigo, nausea and gait disturbances. On examination, she exhibited mild dysphagia, hoarseness, a right-sided Horner sign, left-beating nystagmus and gait ataxia. Muscle strength was normal. Sensations of pinprick, temperature and light touch were markedly decreased over the left body/limbs (roughly 10% of normal side). Trigeminal sensations were also moderately decreased bilaterally.

Brain MRI showed infarcts in the right lateral medulla and the cerebellum (fig. 1, A4). An angiogram showed occlusion of the right vertebral artery. Her symptoms gradually improved. Two months later, however, she began to feel 'salt and pepper' paresthesias over the face bilaterally and in the left hemibody. These were partially relieved by amitriptyline (20 mg/day). The medication was discontinued at 1 year of follow-up when the paresthesias became mild, and examination showed no objective sensory deficit. Forty-one months after the initial stroke, she suddenly developed sensory aphasia, with considerable difficulties in naming and understanding. Examination showed that pinprick and temperature senses were markedly decreased (10% of the normal side) in the left body and limbs. She did not have sensory deficits on the right side, including cortical sensations (graphesthesia and extinction). She also complained of paresthesias over the perioral area bilaterally and in the left hemibody which were described as even worse than the severest she had experienced previously. Brain CT showed a new infarct in the left temporo-parietal area (fig. 1, B4). Amitriptyline was tried again, and the objective sensory deficits and painful paresthesias were moderately improved at 6 months of follow-up.

Patient 5

A 53-year-old hypertensive woman suddenly developed dysarthria, right hemiparesis, hemiparesthesias and upper quadrantanopia. Detailed neurological findings were unavailable, but her motor power improved rapidly. However, there remained persistent paresthesias, more marked in the leg. Brain MRI revealed an infarct involving the left posterolateral thalamus, the most posterior portion of the posterior limb of the internal capsule and the adjacent structure (fig. 1, A5). One year later, she suddenly experienced worsening of the paresthesias in the right leg. She also noted mild weakness and numbness in the left limbs. Examination showed mild hemiparesis (IV/V) without objective sensory deficits in the left. In the right limbs, however, there was hyperpathia to cold stimuli, and severe paresthesias, most marked in the leg. Brain MRI showed a new infarct in the right pons (fig. 1, B5). MR angiogram showed multiple stenoses in both middle cerebral arteries and the left posterior cerebral artery. Amitriptyline (30 mg/day) and carbamazepine (600 mg/day) partially relieved the sensory symptoms.

Discussion

The 5 patients described here had hemisensory symptoms and other neurological deficits due to initial strokes (table 1), which gradually improved. Strikingly, new strokes occurring in the contralateral brain aggravated the previous sensory symptoms. Since sensory symptoms are subjective, one may argue that worsening of sensory symptoms may not be entirely reliable. Indeed, the symptoms may at least in part be influenced by depression or harassment in response to their recurrent strokes. However, I believe that the patients' symptoms were truly worsened for the following reasons.

First, the second strokes produced new symptoms on the side contralateral to the lesion (table 1), of which the

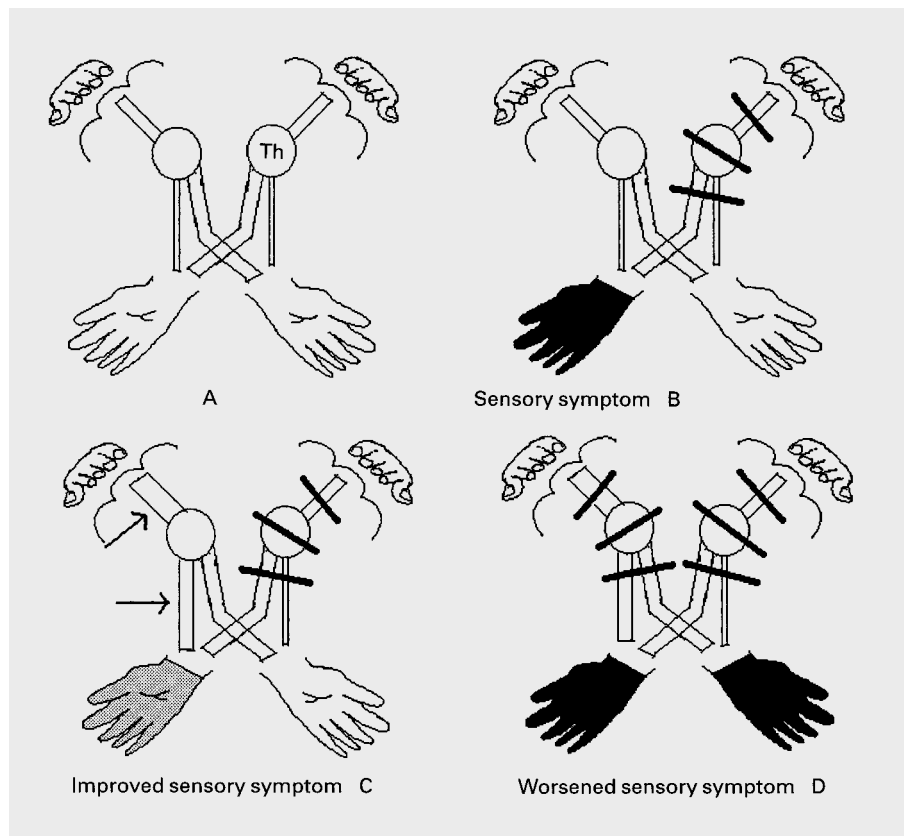


Fig. 2. Schematic drawing of the possible pathogenic mechanism. **A** A majority of the sensory inputs are carried to the opposite sensory cortex, but ipsilateral pathways also exist in a smaller amount. **B** An initial lesion anywhere in the central sensory tract produces sensory symptoms on the contralateral side. **C** Functional enhancement of the ipsilateral sensory pathways (arrows) improves the sensory symptoms. **D** A secondary lesion in the ipsilateral sensory tract worsens the previously improved sensory symptoms. Th = Thalamus.

patients were well aware. Yet, the patients' main concern was the worsening of the previous sensory symptoms, not the newly developed ones. Patients 3, 4 and 5 even believed that a new problem had occurred in the 'previously sick' limbs. Second, the aggravated sensory symptoms were described as 'painful', and pain-relieving medications were required which had been discontinued (patient 4) or had not been used previously (patients 1, 2 and 5). Third, in patients 3 and 4, a clear worsening of the objective sensory deficit was noted, which gradually returned to the previous state. Finally, no patients were considered to be significantly depressed as to require psychiatric evaluation or treatment.

In patient 3, it was unusual that the new infarct on the lateral medulla did not produce sensory symptoms/signs on the contralateral body/limbs. It may be speculated that the presence of anomalous sensory tract had produced ipsilateral sensory symptoms. Indeed, ipsilateral sensorimotor deficit following thalamic-capsular hemorrhage has been reported, which was attributed to anomalous ipsilateral-dominant sensorimotor fibers [3]. However, this was not the case in our patient because the previous

intracerebral hemorrhage produced sensory symptoms on the side contralateral to the lesion. Therefore, the patient's lesion belongs to the unusual type of lateral medullary infarct without sensory symptoms in the contralateral body/limb [4]. Although caudal medullary lesions may produce ipsilateral lemniscal sensory symptoms by way of involvement of either the dorsal column or the decussating fibers [5, 6], this also is a quite remote possibility considering that the patient had impairment of spinothalamic but not lemniscal sensations.

What is the mechanism for the worsening of previous sensory symptoms after the stroke occurring in the contralateral brain? Reappearance or worsening of hemiplegia by a second stroke occurring in the opposite hemisphere has been well documented [7, 8]. Indeed, our patients 1 and 2 showed worsening of motor deficits that had been improving since their first strokes. The most plausible explanation for this phenomenon has been that there are uncrossed motor pathways accounting for approximately 25% of the fibers in the corticospinal tract of human beings and primates [9]. If these fibers have a role in the recovery of muscle strength [10–12], a second stroke

affecting the contralateral hemisphere would not only produce a hemiparesis on the side contralateral to the new lesion, but also worsen the previous motor symptoms. Similarly, it has been shown that a considerable portion of the spinothalamic tract ascends ipsilaterally [13]. Unilateral sensory stimulation may lead to bilateral electrophysiological activation in the somatosensory areas [14, 15]. If we speculate that the sensory symptoms due to the first stroke had improved due to enhanced usage of ipsilateral sensory tracts, a new stroke damaging these pathways would worsen the previous sensory symptoms (fig. 2). Noticeably, patients 2 and 4 did not have sensory symptoms/signs contralateral to the new lesions. These patients may have had either subclinical involvement of the sensory tract or subtle sensory symptoms/signs that could not be assessed reliably when the sensory symptoms/signs were severe in the opposite hemibody.

In patient 4, the worsened objective sensory deficit was to a degree identical to the severest one the patient had shown. In patients 2 and 3, however, this was unclear because they had not been examined by the author at the time of the initial stroke, which was one of the limitations of this study. Regarding subjective symptoms, all the patients described them as even severer and more painful than the symptoms they had experienced. Indeed, as stated above some of them needed new pain-relieving medications. However, it is also possible that they did not

memorize the exact degree of the previous sensory symptoms. Moreover, although aggravated motor deficits and increased spasticity were unlikely to be related directly to the painful sensory symptoms (see descriptions of patients 1 and 2), the possible impact of these factors on their overall sensory complaint cannot be completely excluded. Therefore, although the new strokes clearly worsened the previous sensory symptoms, whether or not the symptoms were even worse than the previous ones remains less certain. If the new strokes indeed provoked severer and more painful symptoms, it would be suggested that the ipsilateral hemisphere plays a role in the modulation of central poststroke pain. Previous literature has described bilateral central pain after unilateral cerebral lesions [16–18].

In summary, our patients demonstrated that aggravation of preexisting sensory symptoms occurs after additional strokes on the opposite side. Although this phenomenon has not been reported previously, I suspect that it occurs more often than previously realized. The present observation suggests that the ipsilateral hemisphere plays a role in the modulation of sensory dysfunctions, and possibly, central poststroke pain. Further studies with a large number of patients are required for clearer understanding of the role of the ipsilateral hemisphere in human sensory function.

References

- Critchley M: The Parietal Lobes. New York, Hafner, 1953.
- Kim JS: Bilateral perioral sensory symptom: Does it have a localizing value? *J Neurol Sci* 1996;140:123–128.
- Hosokawa S, Tsuji S, Uozumi T, Matsunaga K, Toda K, Ota S: Ipsilateral hemiplegia caused by right internal capsule and thalamic hemorrhage: Demonstration of predominant ipsilateral innervation of motor and sensory systems by MRI, MEP, and SEP. *Neurology* 1996;46:1146–1149.
- Kim JS, Lee JH, Lee MC: Patterns of sensory dysfunction in lateral medullary infarction: Clinical-MRI correlation study. *Neurology* 1997;49:1557–1563.
- Kim JS, Lee JH, Lee MC: Sensory changes in the ipsilateral extremity: A clinical variant of lateral medullary infarction. *Stroke* 1995;26:1956–1958.
- Brochier T, Ceccaldi M, Milandre L, Brouchon M: Dorsolateral infarction of the lower medulla: Clinical-MRI study. *Neurology* 1999;52:190–193.
- Brodal A: Self-observation and neuro-anatomical considerations after stroke. *Brain* 1973;96:675–694.
- Fisher CM: Concerning the mechanism of recovery in stroke hemiplegia. *Can J Neurol Sci* 1992;19:57–63.
- Davidoff RA: The pyramidal tract. *Neurology* 1990;40:332–339.
- Lee RG, van Donkelaar P: Mechanisms underlying functional recovery following stroke. *Can J Neurol Sci* 1995;22:257–263.
- Chollet F, DiPiero V, Wise RJS, Brooks DJ, Dolan RJ, Frackowiack RSJ: The functional anatomy of motor recovery after a stroke in humans: A study with positron emission tomography. *Ann Neurol* 1991;29:63–71.
- Silverstrini M, Cupini LM, Placidi F, Diomedes M, Bernardi G: Bilateral hemispheric infarction in the early recovery of motor function after stroke. *Stroke* 1998;29:1305–1310.
- Westmoreland BF, Benarroch EE, Daube JR, Reagan TJ, Sandok BA: *Medical Neurosciences*, ed 3. Boston, Little, Brown & Company, 1994;133–166.
- Luders H, Lesser RP, Dinner DS, Hahn JF, Salanga V, Morris HH: The second sensory area in humans: Evoked potential and electrical stimulation studies. *Ann Neurol* 1985;17:177–184.
- Allison T, McCarthy G, Wood CC, Jones SJ: Potentials evoked in human and monkey cerebral cortex by stimulation of the median nerve. *Brain* 1991;114:2465–2503.
- Tasker RR, de Carvalho G, Dostrovsky JO: The history of central pain syndromes, with observations concerning pathophysiology and treatment. *Pain and Central Nervous System Disease*; in Casey KL (ed): *The Central Pain Syndromes*. New York, Raven Press, 1991, pp 31–58.
- Canavero S: Bilateral central pain. *Acta Neurol Belg* 1996;96:135–136.
- Kim JS: Delayed onset ipsilateral sensory symptoms in patients with central post-stroke pain. *Eur Neurol* 1998;40:201–206.

Copyright: S. Karger AG, Basel 1999. Reproduced with the permission of S. Karger AG, Basel. Further reproduction or distribution (electronic or otherwise) is prohibited without permission from the copyright holder.

Copyright: S. Karger AG, Basel 1999. Reproduced with the permission of S. Karger AG, Basel. Further reproduction or distribution (electronic or otherwise) is prohibited without permission from the copyright holder.