



Case report

Transcortical sensory aphasia due to a left frontal subcortical haemorrhage

SHINICHIRO MAESHIMA†,
TOSHIKAZU KUWATA†,
OSAMU MASUO†, HIROO YAMAGA†,
RYUJI OKITA†, FUMINORI OZAKI†,
HIROSHI MORIWAKI†
and PETER ROGER‡

† Department of Neurological Surgery, Hidaka General Hospital, Wakayama, Japan

‡ School of Communication Sciences and Disorders, University of Sydney, NSW, Australia

(Received 13 May 1999; accepted 8 June 1999)

A case of transcortical sensory aphasia caused by a cerebral haemorrhage in the left frontal lobe is presented. A 72-year-old right-handed woman was admitted to the hospital, with a history of acute onset of speech disturbance and headache. On initial assessment, her spontaneous speech was fluent. She had no difficulty initiating speech, articulated normally, and did not exhibit logorrhea. Her ability to repeat phonemes and short sentences (5-6 words) was fully preserved, however she had severe difficulty with visual recognition of words, and with aural comprehension at the word level, although she was able to read words aloud. Computed tomography and magnetic resonance imaging showed cerebral haemorrhage in the left frontal lobe, involving the superior and middle frontal gyrus. Single photon emission CT revealed a wider area of low perfusion over the entire left frontal lobe, including the superior, middle and inferior frontal gyrus. The aphasia symptoms, mainly poor comprehension, disappeared quickly several weeks after the event. This may have been due to a reduction in the size of the haematoma and a resolution of the oedema around the haematoma. Clinically, the transcortical sensory aphasia in this case was indistinguishable from that caused by damage to the posterior language areas. Further case reports of transcortical sensory aphasia associated with frontal lobe lesions would help to confirm whether a relatively rapid recovery is characteristic in cases such as this.

Introduction

Transcortical sensory aphasia is characterized by fluent speech, poor comprehension, and preserved repetition. The lesion responsible for the aphasia is thought to be located in the posterior language area [1], that is, the left temporo-occipital lobe or left parieto-occipital lobe, but it has also been found in the basal ganglia [2] and the thalamus [3]. There have been very few reports of transcortical sensory aphasia caused by lesions in the frontal lobe [4-6]. This paper reports on a case of transcortical

Correspondence to: Shinichiro Maeshima, M.D., Ph.D., Department of Physical Medicine and Rehabilitation, Wakayama Medical College, 811-1, Kimiidera, Wakayama 641-0012, Japan.

tical sensory aphasia caused by subcortical haemorrhage in the left frontal lobe, and the relationship between the lesion and language deficit is discussed.

Case report

A.N. is a 72 year-old right-handed housewife with 9 years of school education. She had a history of mild hypertension, but no prior history of neurological problems. This patient suddenly began to exhibit speech disturbance with headache and nausea on 5 July 1997. She was referred for diagnosis to the hospital on 9 July 1997. Initially, she was completely conscious with normal orientation. No anomalies were detected in her eyesight or visual fields. Slight paralysis in the right half of her face was accompanied by minor right hemiparesis, but there was no apparent sensory disturbance.

Neuropsychological findings

The patient's spontaneous speech was fluent. She had no difficulty initiating speech, articulated normally, and did not have logorrhea. Echolalia was observed, but phonological structure was clear. Although no paraphasic errors were heard in her spontaneous speech, she made literal paraphasic errors and there was some perseveration as she performed picture-description tasks. This was in contrast to the full preservation of her ability to repeat phonemes and short sentences (5–6 words). She had severe difficulty with visual recognition of words and with aural comprehension at the word level, but she was able to read aloud words in both Kanji (Chinese-based characters) and Kana (syllable-based characters). Agraphia was almost total for Kanji but was 60% for Kana. The Western aphasia battery (WAB) was administered 2 weeks following the onset of symptoms, and the results are given in table 1. In addition, A.N. demonstrated constructional apraxia but not oral, ideomotor, or ideational apraxia. On the Weschler Adult Intelligence Scale-Revised (WAIS-R), her performance intelligence quotient (IQ) was 79. Verbal IQ was unmeasurable because of the aphasia.

Neuroradiological findings

The computed tomography (CT) scan performed on admission showed a high density area in the left frontal lobe (figure 1). Magnetic resonance imaging (MRI) revealed a cerebral haemorrhage in the left frontal lobe, involving the superior and middle frontal gyrus (figure 2). Cerebral angiography was performed via trans-

Table 1. The scores of the subsets in the Western Aphasia Battery

		2 weeks post-onset	5 weeks post-onset
I.	Spontaneous speech (/20)	16	19
II.	Comprehension (/10)	4.6	8.75
III.	Repetition (/10)	10	10
IV.	Naming (/10)	2.8	7.8
V.	Reading (/10)	3.4	6.1
VI.	Writing (/10)	3.8	8.8

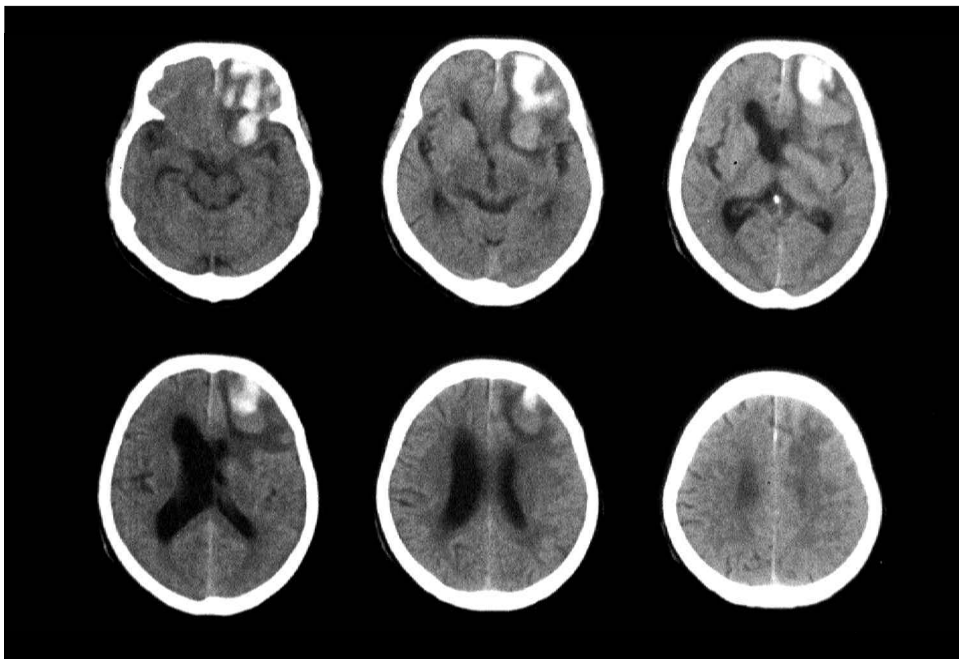


Figure 1. Computed tomography scan performed on admission showed a high density area in the left frontal lobe.

femoral catheterization of the internal carotid artery 5 days after admission, and did not reveal any lesions. Single photon emission CT (SPECT), 6 days after admission, revealed a wider area of low perfusion over the entire left frontal lobe including the left superior, middle, and inferior frontal gyrus (figure 3a) with sparing of the precentral gyrus.

Clinical course

Spontaneous speech was still limited 3 weeks later. However, there was some improvement in the patient's ability to name and to describe scenes. Paraphasia had also disappeared. Auditory verbal comprehension had improved remarkably, but was still poor at the sentence level. Agraphia had also improved significantly. The scores of the WAB 5 weeks after the onset are shown in table 1. SPECT revealed an improvement in the diminished cerebral blood flow in the frontal lobe (figure 3b). All signs of aphasia had completely resolved 8 weeks after the onset of symptoms.

Discussion

The language symptoms in this patient can be summarized as follows. Spontaneous speech was fluent, although literal paraphasic errors were observed. Disturbance of auditory comprehension was evident, and echolalia was sometimes observed. Repetition was excellent. The patient's ability to read aloud was good, but she was not able to understand what she was reading. The separation between reading aloud and comprehension was, thus, obvious. Moderate to severe disturbances in

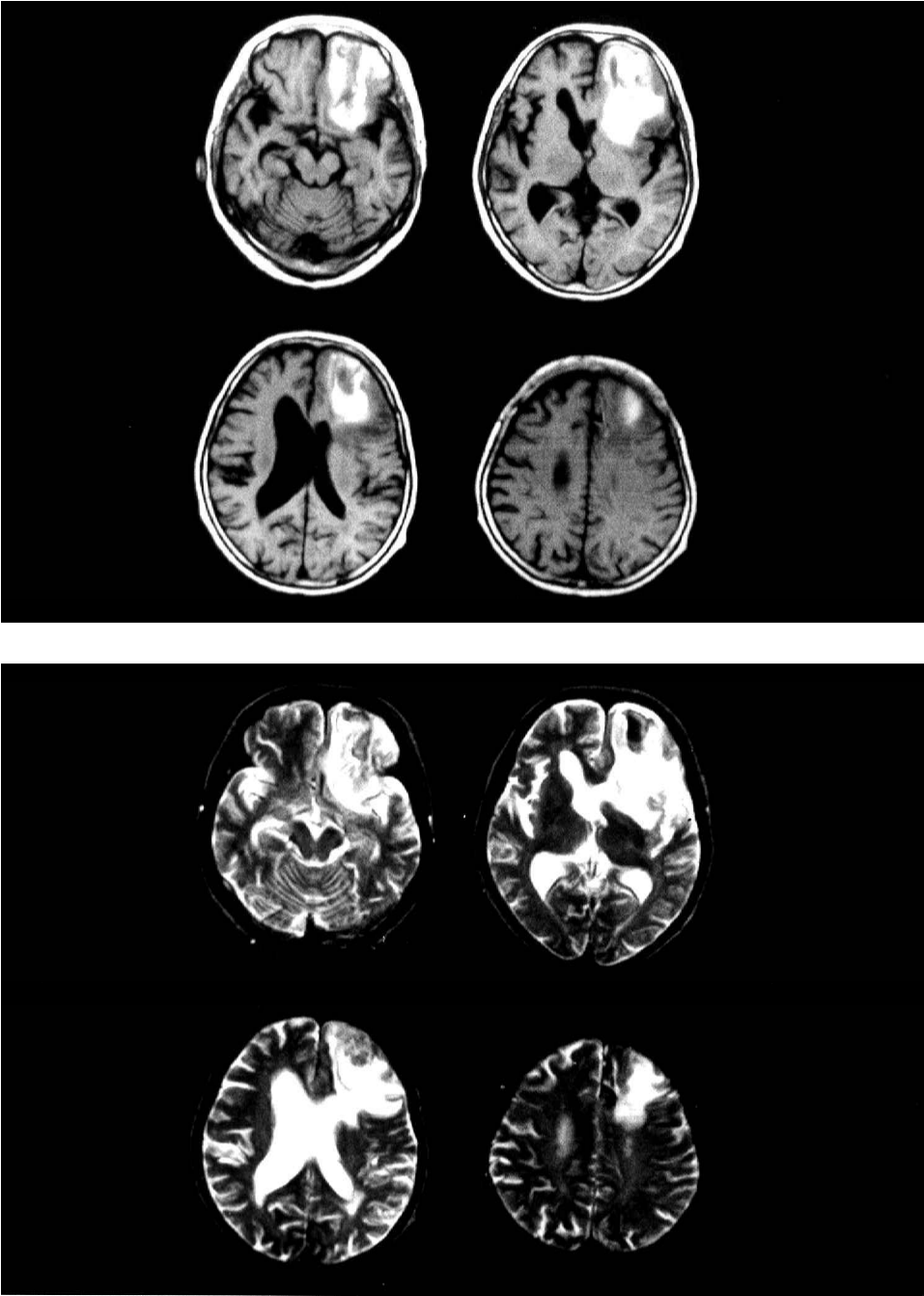


Figure 2. Magnetic resonance imaging revealed cerebral haemorrhage in the left frontal lobe, involving the superior and middle frontal gyrus.

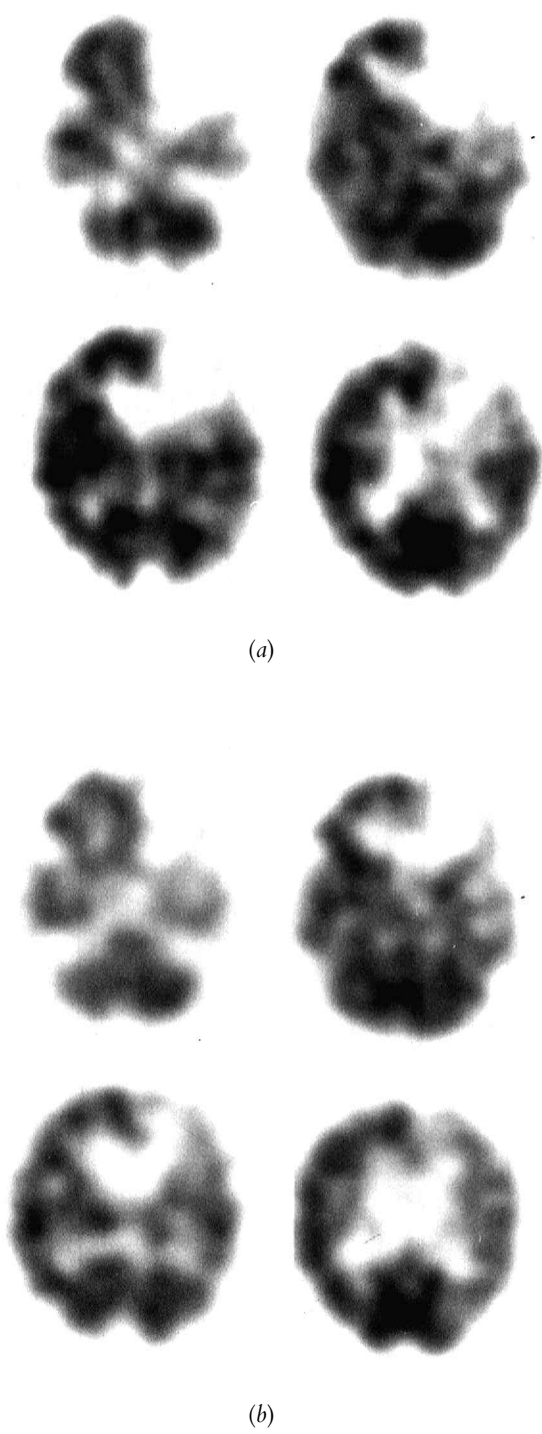


Figure 3. Single photon emission CT (a) 6 days after admission, revealing a wider area of low perfusion over the entire left frontal lobe including the left superior, middle, and inferior frontal gyrus, and (b) 5 weeks after the onset, revealing an improvement in the diminished cerebral blood flow in the frontal lobe.

object naming and writing were also observed. These characteristics were considered to represent transcortical sensory aphasia in the classical classification.

Patients with transcortical sensory aphasia usually retain not only repetition but also the ability to read aloud. Repetition and reading aloud are activities that can be carried out without any appreciation of the meaning of the corresponding phonemes as they are input auditorily or visually [5]. It seems that this case also fits this description. In contrast, naming and reading comprehension are activities which require interconversion processing of phonemes and meaning. In this case, the difficulties in the auditory comprehension of words and sentences indicate that there was a disorder involving interconversion processing in both the phoneme processing system and the semantic processing system.

The lesion responsible for transcortical sensory aphasia is generally considered to be in the posterior language area surrounding Wernicke's area. Kertesz *et al.* [1], reporting the results of a neuroradiological study using CT scan, placed responsible lesions in the left temporo-occipital lobe or left parieto-occipital lobe. Others have located the responsible lesion in the left basal ganglia or the internal capsule [2]. Yamadori *et al.* [6] have reported three cases of transcortical sensory aphasia caused by lesions in the frontal portion of the left basal ganglia. They have also reported lesions in the deep white matter of the anterior horn of the left lateral ventricle. In cases of transcortical sensory aphasia caused by thalamic lesions, damage to thalamo-cortical projection fibres has been determined to be more responsible for symptoms of the aphasia than damage to the thalamus itself [5]. In this case, the lesion was located in the white matter in the anterior horn of the left lateral ventricle and the middle frontal gyrus. Furthermore, in the cerebral blood flow (CBF) study using SPECT, no abnormalities in the left temporo-occipital lobe or parieto-occipital lobe were observed, but extensive reduction of the CBF in the cortex and subcortex of the middle frontal gyrus to the inferior frontal gyrus, including a part of Broca's area, was observed.

It is known that anarthria, the core symptom of non-fluent aphasia, does not occur in Japanese in response to exclusive damage in Broca's area, but it does occur as a result of lesions in the lower part of the precentral gyrus [7, 8]. There have been some reports of fluent aphasia caused by lesions in the frontal lobe including Broca's area, as in this case [4, 9, 10], but the CBF was not examined in these cases. It is presumed that the individual described in this case did not exhibit any non-fluent aphasia symptoms, because the CBF to the precentral gyrus was maintained.

In recent years, a relationship between frontal lobe lesions and difficulty in comprehension has been reported. Yoshimura and Soma [11], who have examined comprehension difficulties in Broca's aphasia, have reported that if lesions spread ahead of Broca's area, poor comprehension in spoken and written language occurs. Otsuki *et al.* [10] have reported that, in aphasia caused by lesions located in the frontal lobe, the lower and further outward the lesion spreads from the superior frontal gyrus, the more ability to understand deteriorates. This gives considerable weight to the connection between lesions in the middle frontal gyrus cortex/subcortex and semantic understanding disturbance (semantic aphasia). A PET study by Peterson *et al.* [12] demonstrated that an increase in the blood flow in the frontal lobe occurred during the performance of word comprehension tasks. Schaffler *et al.* [13] have reported a case in which electrical stimulation to Broca's area caused poor comprehension. The aphasia symptoms in this case, notably the poor comprehension, disappeared quickly several weeks after the pathopoiesis. This

may have been caused by a reduction in the size of the haematoma and a resolution of the oedema around the haematoma. An improvement was observed in the diminished cerebral blood flow in the frontal lobe, by SPECT. From the current case, one could not identify distinct differences between the transcortical sensory aphasia sometimes caused by damage to the posterior language area and that caused by damage to other sites. The patient in this case showed a relatively rapid recovery of language function. As the literature contains few case reports of transcortical sensory aphasia associated with frontal lobe lesions, additional cases would be of value in determining whether rapid recovery was, in fact, a more general characteristic of this particular condition.

References

1. KERTESZ, A., SHEPPARD, A. and MACKENZIE, R.: Localization in transcortical sensory aphasia. *Archives of Neurology*, 39: 475–478, 1982.
2. DAMASIO, A. R., DAMASIO, H., VARNEY, M. F. *et al.* Aphasia with nonhemorrhagic lesions in basal ganglia and internal capsule. *Archives of Neurology* 39: 15–20, 1982.
3. CAPP, S. F. and VIGNOLO, L. A.: Transcortical features of aphasia following left thalamic hemorrhage. *Cortex*, 15: 121–130, 1979.
4. ISHIGURO, S., KAWAKAMI, O., HASHIZUME, M. *et al.*: A case of transcortical sensory aphasia following a left frontal lobe lesion involving Broca's area. *Higher Brain Function Research*, (Tokyo) 16: 322–330, 1996.
5. OTSUKI, M., SOMA, Y., KOYAMA, A. *et al.* Transcortical sensory aphasia following a left frontal lesion—case report. *No To Shinkei* (Tokyo), 46: 866–871, 1994.
6. YAMADORI, A., OHIRA, T., SERIU, M. *et al.* : Transcortical sensory aphasia produced by lesions of the anterior basal ganglia area. *No To Shinkei* (Tokyo), 36: 261–266, 1982.
7. KAWAMURA, M., SHIOTA, J. and HIRAYAMA, K.: Dysarthria from a neurological point of view. *Onsei Gengo Igaku*, 31: 235–241, 1990.
8. YOSHINO, M.: Apraxia of speech. *Shinkei Kenkyu no Shinpo* (Tokyo), 38: 588–596, 1994.
9. OTSUKI, M., SOMA, Y., ONODERA, O. *et al.*: Auditory comprehension in transcortical motor aphasia due to a medial lesions of the left frontal lobe. *No To Shinkei* (Tokyo), 47: 1081–1085, 1995.
10. SOMA, Y., OTSUKI, M., YOSHIMURA, N. *et al.*: Fluent aphasia with lesions in Broca's aphasia. *Neurological Medicine* (Tokyo), 41: 385–391, 1994.
11. YOSHIMURA, N. and SOMA, Y.: The correlation between the auditory comprehension capability and the brain lesion site in patients with Broca's aphasia: A CT study. *Higher Brain Function Research*, (Tokyo) 13: 224–229, 1993.
12. PETERSON, S. E., FOX, P. T., POSNER, M. I. *et al.*: Positron emission tomographic studies of the cortical anatomy of single-word processing. *Nature*, 331: 585–589, 1988.
13. SCHAFFLER, L., LUDERS, H. O., DINNEN, D. S. *et al.*: Comprehension deficits elicited by electrical stimulation of Broca's area. *Brain*, 116: 695–715, 1993.