



## Case Reports

# Tuberous Sclerosis Associated With MDR1 Gene Expression and Drug-Resistant Epilepsy

Alberto Lazarowski, PhD\*,  
Gustavo Sevlever, MD, PhD†,  
Analía Taratuto, MD‡,  
Mario Massaro, MD‡, and  
Adrián Rabinowicz, MD§

Intractable seizures are the most common manifestation in severe cases of tuberous sclerosis. Multidrug resistance type 1 (MDR1) gene expression is directly linked to the resistance of tumor cells to chemotherapy as the major cause of treatment failure, but it has not been reported in tuberous sclerosis cells nor has the relationship between the MDR1 gene and antiepileptic drugs been described. A 4-month-old female is described with poorly controlled seizures secondary to tuberous sclerosis. The patient was treated with antiepileptic drugs, including phenytoin, phenobarbital, and lorazepam, without improvement of symptoms. Phenytoin blood levels were invariably subtherapeutic and ranged from 0.45 to 3.55  $\mu\text{g/mL}$ , despite several consecutive intravenous loading doses. Surgical treatment with total resection of the brain lesions was performed as a last resort. Immunohistochemical analysis of the resected tissues revealed high levels of P-glycoprotein 170 expression, the product of the MDR1 gene. Both MDR1 gene expression and persistently low phenytoin levels likely share a common pathway liable to induce drug-resistant epilepsy. © 1999 by Elsevier Science Inc. All rights reserved.

From the \*Clinical Chemistry Laboratory; and Departments of †Pathology; ‡Pediatrics; and §Neurology; FLENI, Instituto de Investigaciones Neurológicas "Raul Carrea"; Buenos Aires, Argentina.

Lazarowski A, Sevlever G, Analía T, Massaro M, Rabinowicz A. Tuberous sclerosis associated with MDR1 gene expression and drug-resistant epilepsy. *Pediatr Neurol* 1999;21:731-734.

## Introduction

Epilepsy is a common neurologic disorder, affecting 1-2% of the general population. Although antiepileptic therapies efficiently control seizures in most patients, it is estimated that 20-25% of the affected population fails to achieve good control with antiepileptic drug (AED) treatment [1], thus resulting in refractory or drug-resistant epilepsy.

The underlying mechanisms involved in AED resistance are still poorly understood. Isolated reports suggest that unresponsiveness to AEDs resembles the mechanism of resistance to chemotherapy in cancer cells. Refractoriness to cancer chemotherapy is attributed to the action of the P-glycoprotein 170 (Pgp-170), the product of the MDR1 gene [2,3], which acts as an energy-dependent pump that drives potentially toxic species out of cells [4,5]. Although many AEDs have structural similarities with known substrates of Pgp-170, the relationship between AEDs and Pgp-170 has not yet been investigated.

Tuberous sclerosis is an autosomal-dominant disorder affecting the central nervous system in most patients. Intractable seizures are one of the most frequent manifestations of tuberous sclerosis. Tuber cells include features of both glial and neural cells, without clearly being identifiable as one or the other. Although the clinical, neuropathologic, and genetic aspects of the tuberous sclerosis complex have been previously described [6], the presence of Pgp-170 in tuber cells has not been reported to date.

A 4-month-old infant is reported with drug-resistant epilepsy secondary to tuberous sclerosis with expression of the MDR1 gene and persistently low phenytoin (PHT) blood levels.

## Case Report

A 4-month-old female was admitted to our center with a sinusoidal dysrhythmia with no hemodynamic changes; an echocardiogram disclosed the presence of myocardial rhabdomyomas. Skin examination under Wood's light excluded the presence of hypochromic lesions. Her clinical records revealed that she had been born after an uneventful

Communications should be addressed to:  
Dr. Lazarowski; FLENI; Montañeses 2325;  
Buenos Aires 1428, Argentina.  
Received November 30, 1998; accepted June 15, 1999.

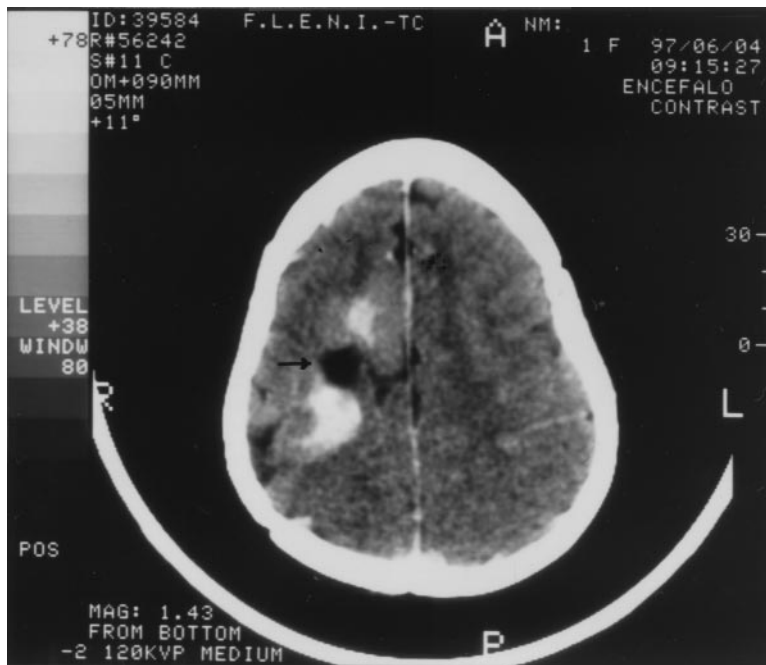


Figure 1. Right frontoparietal heterogeneous cystic lesion (arrow) with a double component: two adjacent hyperintense images.

pregnancy without neonatal complications and that she had developed partial and tonic seizures of her left upper limb at the age of 12 days.

Routine blood tests, neurometabolic profile, cerebrospinal fluid analysis, and serial interictal electroencephalography were all normal. Ictal activity during video-electroencephalography revealed epileptiform activity arising from the right temporal lobe. Cranial computed tomography revealed the presence of a lesion over the right parietal region (Fig 1). Her seizures failed to abate despite aggressive treatment with several combined AED regimes (Table 1) and evolved into several episodes of partial status epilepticus. Because of the failure of the AEDs, the patient underwent nine loading doses with intravenous PHT (15-18 mg/kg) and lorazepam (0.1 mg/kg). Because the seizures remained uncontrollable, surgical treatment, with total resection of the lesion, was performed.

Brain biopsy revealed marked cellular enlargement of both neuronal and glial components, with gliosis and dysplastic neurons, interpreted as tuberous sclerosis. The typical appearance of the tuber cells ranged from polygonal cells with ample glassy cytoplasm to more elongated ones. Giant pyramidal cells with ganglionic morphology were also observed. Abnormal cellular clustering and orientation, as well as glial cell proliferation, were also consistent features. Glial fibrillary acidic protein, neuron-specific enolase, and neurofilaments were immunoreactive in such cells.

Table 1. Different therapeutic strategies used without improvement before initiation of PHT

|   |    |      |
|---|----|------|
| Phenobarbital                                 | 55 | 2.20 |
| Valproic acid                                 | 30 | 0.93 |
| Valproic acid + clonazepam                    | 60 | 3.55 |
| Valproic acid + clobazam                      | 56 | 0.45 |
| Carbamazepine + clobazam                      | 42 | 1.59 |
| Carbamazepine + vigabatrin                    | 90 | 1.66 |
| Carbamazepine + vigabatrin + PHT + lorazepam* | 60 | 1.62 |
| Vigabatrin + lamotrigine + PHT + lorazepam*   | 72 | 2.45 |

\*Used during episodes of partial status epilepticus.

## Results

Despite receiving PHT treatment, at the time of admission, her PHT blood levels, as assessed by a fluorescence polarization immunoassay (Abbott Division, Abbott Park, IL) ranged from 0.45 to 3.55  $\mu\text{g/mL}$ , well below the therapeutic range of 10-20  $\mu\text{g/mL}$  (Table 2). Consequently, blood levels of PHT were measured at different times after a single intravenous infusion of 50 mg of PHT. Blood PHT concentrations were 6.81, 5.9, 3.7, and 0.56  $\mu\text{g/mL}$  at 0.5, 2.5, 6, and 12 hours, respectively, and the estimated half-life was 5.04 hours.

Pgp-170 was detected in tuber cells using the JSB-1 anti-P-glycoprotein monoclonal antibody (Novocastra, Newcastle Upon Tyne, UK) (Fig 2). Immunoreactivity was developed with a streptavidin immunoperoxidase kit according to the manufacturer's protocol (Biogenex, San Ramon, CA).

Table 2. PHT subtherapeutic levels after intravenous loading doses\*

| Loading Doses (mg) | Plasma PHT Levels ( $\mu\text{g/mL}$ ) |
|--------------------|--|
| 55                 | 2.20                                   |
| 30                 | 0.93                                   |
| 60                 | 3.55                                   |
| 56                 | 0.45                                   |
| 42                 | 1.59                                   |
| 90                 | 1.66                                   |
| 60                 | 1.62                                   |
| 72                 | 2.45                                   |

\*Samples were obtained as previously described [11].

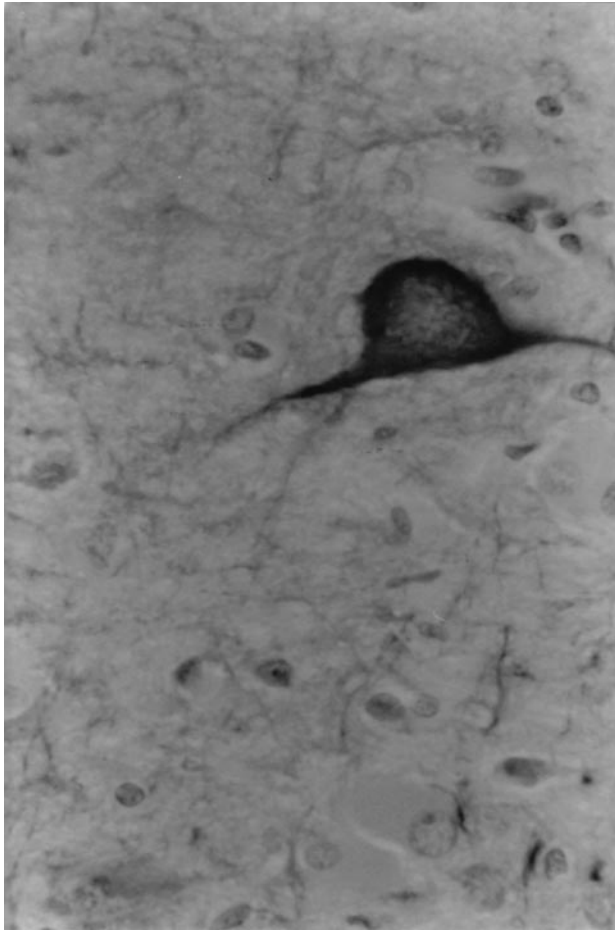


Figure 2. Immunostaining for P-glycoprotein using the JSB-1 monoclonal antibody (Novocastra) and an avidin-biotin system (Biogenex) ( $\times 1,000$ ); positive in tuber cells.

Vigabatrin and lorazepam were given as treatment after the surgical procedure, and the patient remained free of seizures 1 year after surgery.

## Discussion

Two central observations were established in the present study. First, that multidrug-resistant Pgp-170 was detected in cells of tuberous sclerosis in a patient with intractable epilepsy. Second, the ineffectiveness of the AEDs appeared to correlate with the persistently low blood levels of PHT. These findings suggest a potential link between epilepsy secondary to tuberous sclerosis and multidrug resistance caused by Pgp-170.

Drug resistance is a common complication during anti-cancer chemotherapy. Although the mechanism of anti-cancer drug resistance is not fully understood, it is widely recognized that Pgp-170 plays a major role in drug refractoriness. Pgp-170 functions as an energy-dependent efflux pump, which performs nondiscriminatory clearance of a wide spectrum of chemicals, including antitumor agents [2-5]. In normal tissues, Pgp-170 and MDR1 transcripts have been detected at the luminal surfaces of

excretory organs, such as the adrenal cortex and exocrine pancreas, and Pgp-170 is functionally expressed along the biliary canalicular surface of hepatocytes and the luminal side of proximal tubule cells in the kidney [7]. The expression of Pgp-170 in the lumen of excretory tissues supports its role as a detoxifying pump.

In the brain, it is believed that Pgp-170 is normally expressed exclusively in capillary endothelial cells [7]. However, whether Pgp-170 is expressed in cells of tuberous sclerosis has not previously been addressed. The potential involvement of Pgp-170 in AED resistance has also not been investigated.

The authors' finding that Pgp-170 is expressed in tuber cells suggests one mechanism for AED resistance in tuberous sclerosis (i.e., local depletion of AEDs). It is not clear whether Pgp-170 expression in the authors' patient reflected spontaneous (normal) transcription of the MDR1 gene or, alternatively, induction by AEDs. Indeed, it has been proposed that AEDs might upregulate MDR gene expression. Phuphanich et al. [8] have reported a few patients with brain tumors who developed resistance to chemotherapy secondary to PHT treatment. Consistent with this observation, Tishler et al. [9] recently documented overexpression of Pgp-170 in endothelial cells and astrocytes in surgical specimens from the brain of patients with AED-resistant epilepsy. In agreement with their data, patients who underwent temporal lobectomies exhibited Pgp-170 and metallothionein in mesial structures but not in the spare neocortex [10].

Additional mechanisms may also determine drug refractoriness. For example, the short half-life and persistent subtherapeutic blood levels of PHT observed in the authors' patient suggest fast drug removal [11]. Although enzymatic induction of PHT metabolism has been described, it is also plausible, although not demonstrated, that the rapid plasma turnover of PHT was caused by enhanced clearance in the excretory organs. One speculation that needs further investigation is whether PHT administration triggered a systemic MDR1 gene transcription that resulted in overfunctioning of Pgp-170 in excretory tissues (e.g., kidney and liver).

A recent study of patients with refractory cancer, who were treated with the Pgp-170 modulator SDZ PSC 833, indicated that the Pgp-170 transport substrate technetium-99m-Sestamibi was fast and selectively sequestered in the liver and kidneys [12]. It will be useful to test whether a similar approach could determine the involvement of Pgp-170 in AED clearance in refractory epilepsy.

Tuberous sclerosis is an autosomal-dominant disorder characterized by the development of unusual tumorlike growth (hamartomas) in multiple organs [13]. Depending on the nature of tuberous sclerosis cells, the transient presence of Pgp-170 might represent a normal phenotypic expression of immature cells, because it is observed in both normal bone marrow and peripheral CD34+ stem cells [14,15].

We speculate that in our patient, AED resistance and subtherapeutic PHT plasma levels might have been

secondary to overexpression of Pgp-170. Further studies are needed to confirm the involvement of Pgp-170 in the development of intractable epilepsy. Approaches aimed at eliminating Pgp-170 function may be of potential benefit during AED treatment.

#### References

- [1] **National Institutes of Health.** Consensus conference: Surgery for epilepsy. *JAMA* 1990;264:729-33.
- [2] **Biedler N, Riehm W.** Cellular resistance to actinomycin D hamster cells in vitro: Cross resistance, radioautographic, and cytogenetics studies. *Cancer Res* 1990;30:1174-84.
- [3] **Ling V.** Does P-glycoprotein predict response to chemotherapy? *J Natl Cancer Inst* 1989;81:84-5.
- [4] **Gottesman MM, Pastan I.** The multidrug transporter, a double-edge sword. *J Biol Chem* 1988;263:12163-6.
- [5] **Gottesman MM, Pastan I.** Biochemistry of multidrug resistance mediated by the multidrug transporter. *Ann Rev Biochem* 1993;62:385-427.
- [6] **Schort MP, Richardson Jr E, Haines JL, Kwiatkowski D.** Clinical neuropathological and genetic aspects of tuberous sclerosis complex. *Brain Pathol* 1995;5:173-9.
- [7] **Cordon-Cardo C.** Immunohistochemical analysis of P-glycoprotein expression in normal and tumor tissues in humans. In: Roninson IB, ed. *Molecular and cellular biology of multidrug resistance in tumor cells*. New York: Plenum Press, 1991:303-18.
- [8] **Phuphanich S, Lomartire M, DeConti R.** Is early complete response in recurrent malignant gliomas treated with cisplatin, VP-16, and vincristine related to anticonvulsant? *Ann Neurol* 1996;4:490.
- [9] **Tishler D, Weinberg K, Hinton D, Barbaro N, Germalyn A, Corey R.** MDR1 gene expression in brain of patient with medically intractable epilepsy. *Epilepsia* 1995;36:1-6.
- [10] **D'Giano C, Sevlever G, Lazarowski A, et al.** Expression of P-glycoprotein and related proteins in brain of patients with refractory temporal lobe epilepsy. *Epilepsia* 1997;38 (Suppl 87):8.
- [11] **Woodbury D.** Phenytoin: Absorption, distribution and excretion. In: Levy R, Mattson R, Meldrum B, Penry JK, Dreifuss FE, eds. *Antiepileptic drugs*. New York: Raven Press, 1989:177-95.
- [12] **Luker G, Fracasso P, Dobkin J, Piwnica-Worms D.** Modulation of the multidrug resistance P-glycoprotein: Detection with technetium-99m-Sestamibi in vivo. *J Nucl Med* 1997;38:369-72.
- [13] **Roach ES, Smith M, Huttenlocher P, Bhat M, Alcorn D, Hawley L.** Diagnostic criteria: Tuberous sclerosis complex: Report of the Diagnostic Criteria Committee of the National Tuberous Sclerosis Association. *J Child Neurol* 1992;7:221-4.
- [14] **Holyoake TL, Alcorn MJ.** CD34+ positive haematopoietic cells. Biology and clinical applications. *Blood Rev* 1994;8:113-24.
- [15] **Voigt A, Häfer R, Gruhn B, Zintl F.** Expression of CD34 and other haematopoietic antigens on neuroblastoma cells: Consequences for autologous bone marrow and peripheral blood stem cell transplantation. *J Neuroimmunol* 1997;78:117-26.