

Beneficial Effect of Piracetam Monotherapy on Post-ischaemic Palatal Myoclonus

*D KARACOSTAS, T DOSKAS, N ARTEMIS, K VADICOLIAS
AND I MILONAS*

B' Department of Neurology, Aristotelian University School of Medicine,
AHEPA Hospital, Thessaloniki, Greece

A 70-year-old hypertensive woman suffered a subarachnoid haemorrhage followed by delayed vasospasm in the basal cerebral arteries. This resulted in multiple ischaemic lesions in the right middle cerebral artery region and contralateral post-ischaemic palatal myoclonus. In this setting, piracetam administered in high doses (24 – 36 g/day), abolished the myoclonus observed in this patient. Although there is evidence from case reports and clinical trials of the therapeutic efficacy of piracetam in patients with skeletal myoclonus of various causes, to our knowledge this is the first report indicating the beneficial effect of piracetam monotherapy on post-ischaemic palatal myoclonus.

KEY WORDS: PIRACETAM; CEREBRAL ISCHAEMIA; PALATAL MYOCLONUS

***I*NTRODUCTION**

Piracetam (2-oxo-1-pyrrolidine acetamide), the prototype of 'nootropic' drugs,¹ has been widely used in Europe to treat memory and cognitive deficits in the elderly,^{2,3} to slow the progression of Alzheimer's disease,⁴ and recently in the treatment of acute ischaemic stroke.⁵ In addition, open trials have provided further evidence of the efficacy of piracetam, given either as monotherapy⁶ or in combination with other drugs, as a treatment for myoclonus of diverse causes.⁷ We report below on the use of piracetam

monotherapy to treat an elderly woman with post-ischaemic palatal myoclonus.

***C*ASE REPORT**

On 17 January 1999, a 70-year-old woman was admitted to hospital complaining of sudden occipital headache, vomiting and loss of consciousness. Her previous medical history disclosed only arterial hypertension, inadequately treated for the past 20 years. Neurological examination was normal

**Piracetam in post-ischaemic palatal
myoclonus**

except for nuchal rigidity and bilateral extensor plantar responses. An immediate brain computed tomography scan revealed a subarachnoid haemorrhage mainly located in both Sylvian fissures (Fig 1a), more marked in the right temporal lobe (Fig 1b).

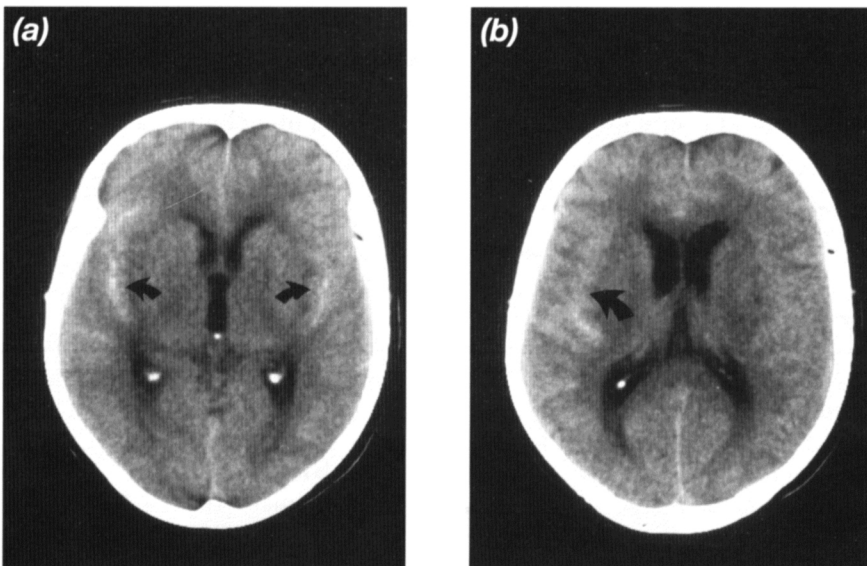
The patient was treated with a calcium channel blocker, nifedipine, by intravenous infusion at 5 ml/h (1 mg/h), with an antihypertensive, perindopril (an angiotensin-converting enzyme inhibitor), 4 mg orally daily, paracetamol 20 mg orally daily, and intravenous fluids, and showed significant improvement in both headache and nuchal rigidity over the next 13 days.

Haematological and biochemical tests, including liver, kidney and immune function tests and an electroencephalogram were normal. Transcranial doppler showed moderately increased systolic velocities

(90 – 110 cm/s) in both middle cerebral arteries. On 30 January, the patient suddenly developed a left hemiparesis along with ipsilateral hypoaesthesia, homonymous hemianopia and central facial and hypoglossal nerve palsy. An urgent computed tomography brain scan was unrevealing, but the clinical picture was thought to be due to right hemisphere ischaemia secondary to vasospasm.

The next morning on wakening, the patient had developed a continuous involuntary movement, with rhythmic contractions (100 – 120/min) affecting the left lower part of the face, the left side of the mouth, the mandible, the soft palate, occasionally spreading to the right side and also involving the tongue with irregular, slower (70 – 80/min) movements in and out of the mouth. This whole activity continued

FIGURE 1



(a) Brain computed tomography scan revealed subarachnoid haemorrhage in both Sylvian fissures (arrows). (b) The subarachnoid bleeding was more marked at the right temporal lobe (arrow).

**Piracetam in post-ischaemic palatal
myoclonus**

during sleep and the patient also complained of a rhythmic sound (like an ear-click), heard over the left side. The patient's level of consciousness was entirely normal at all times and the limbs were not involved at any time. A new electroencephalogram demonstrated a low-voltage, slow-wave activity (4 – 5 c/s) over the right fronto-temporal region but no epileptiform activity.

Intravenous infusion of piracetam, 24 g daily for 2 days, and then 36 g daily for the next 3 days, resulted initially in improvement of the involuntary movement activity and, finally, in complete cessation on the fifth day. Concomitant medication included only intravenous fluids, low-molecular-weight heparin subcutaneously and an antihypertensive (angiotensin-converting enzyme inhibitor) orally, along with nifedipine (a calcium channel blocker)

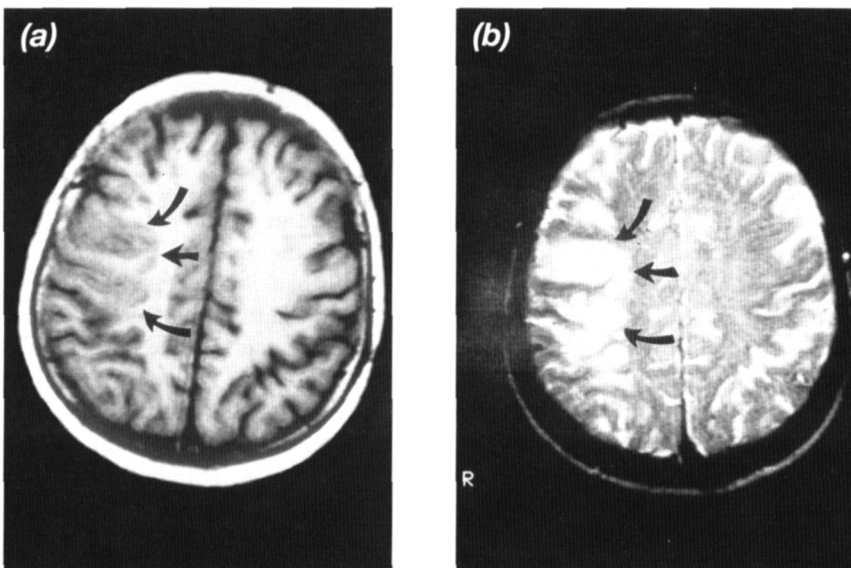
by intravenous infusion. The contractions recurred in the same areas 1 day after the piracetam infusion was discontinued. The drug was re-introduced at a dose of 36 g/day by intravenous infusion for 5 days, and the symptoms subsided and ceased again. The patient remained on piracetam 6 g/day (oral solution) and was asymptomatic at the time of discharge on 15 February.

Interestingly, a brain magnetic resonance image scan performed on 3 February (3 days after the start of the involuntary movements) demonstrated multiple ischaemic lesions in the right middle cerebral artery area (Fig. 2), both on T1- and T2- weighted images.

***D*ISCUSSION**

Since 1978,⁸ case reports and clinical trials have provided evidence for the therapeutic

FIGURE 2



Brain magnetic resonance axial imaging demonstrated multiple ischaemic lesions in the right middle cerebral artery territory (arrows) both on (a) T1- and (b) T2-weighted images.

**Piracetam in post-ischæmic palatal
myoclonus**

efficacy of piracetam, in patients with skeletal myoclonus of varying aetiologies.^{6,7,9-11}

Palatal myoclonus is a definite clinical and anatomical entity, a form of myoclonia distinct from the general group of the myoclonias.¹² Apart from its localization to the oro-facial-brachial-respiratory muscles, with occasional spread beyond this territory, palatal myoclonus has a regular rhythm, is persistent during sleep and is not accompanied by any epileptiform activity in the electroencephalogram.^{12,13} It is most often due to cerebrovascular and degenerative diseases, encephalitis, multiple sclerosis, or trauma. The responsible lesion(s) might be anywhere in the extensive functional circuit connecting the olivo-dentato-rubral triangle to the striatal system, the pallidum or the thalamus.^{12,13}

The clinical, laboratory and neuroimaging profile of our patient indicated that an initial subarachnoid haemorrhage was followed by delayed vasospasm in the basal cerebral arteries that resulted in multiple ischaemic

lesions in the right middle cerebral artery territory and contralateral post-ischæmic/hypoxic palatal myoclonus. In this setting, piracetam administered in high doses (24 - 36 g/day) abolished the myoclonus observed in this patient. Although the mode of action of piracetam is uncertain, we suggest that the beneficial effect observed was probably due to the neuromodulatory effect of piracetam,¹⁴ either as a result of its cholinergic-enhancing⁴ or γ -amino-*n*-butyric acid-inhibiting⁶ action. To our knowledge, this is the first report indicating the beneficial effect of piracetam monotherapy, on post-ischæmic palatal myoclonus.

ACKNOWLEDGEMENTS

The authors would like to thank Dr Ioannou UCB-Hellas, for kindly providing references, as well as for his critical help, and Mrs Dimitra Ladikou for typing the manuscript.

REFERENCES

- 1 Giurgea C: The nootropic concept and the pharmacologic originality of piracetam. *Essentialia* 1986; **1**: 1 - 15.
- 2 Pereu G, Spignoli G: Neurochemical actions of 'nootropic drugs'. In: *Advances in Neurology*, vol. 51 (Wurtman PJ, ed). New York, Raven Press, 1990; pp247 - 252.
- 3 Friedman E: Clinical response to choline plus piracetam in senile dementia: relation to red-cell choline level. *N Engl J Med* 1981; **304**: 1490 - 1491.
- 4 Croisile B, Trillet M, Fontanari J, *et al*: Long-term and high dose piracetam treatment of Alzheimer's disease. *Neurology* 1993; **43**: 301 - 305.
- 5 De Deyn P, de Reuck J, Deberdt W, *et al*. for members of the piracetam in Acute Stroke Study (PASS) Group: Treatment of acute ischaemic stroke with piracetam. *Stroke* 1997; **28**: 2347 - 2352.
- 6 Obeso JA, Artieda J, Luguin MR, *et al*: Antimyoclonic action of piracetam. *Clin Neuropharmacol* 1986; **9**: 58 - 64.
- 7 Obeso JA, Artieda J, Rothwell JC, *et al*: The treatment of severe action myoclonus. *Brain* 1989; **100**: 455 - 487.
- 8 Terwiunghe G, Daumerie J, Nicaise C, *et al*: Effect therapeutique du piracetam dans un cas de myoclonie d' action post-anoxique. *Acta Neurol Belg* 1978; **78**: 30 - 36.

**D Karacostas, T Doskas, N Artemis
et al.**

**Piracetam in post-ischaemic palatal
myoclonus**

- 9 Brown P, Steiger MJ, Thompson DD, *et al*: Effectiveness of piracetam in cortical myoclonus. *Mov Disord* 1993; **8**: 63 – 68.
- 10 Karacostas D, Artemis N, Karoutas G, *et al*: Piracetam for the treatment of myoclonus secondary to herpes simplex encephalitis. *Acta Therapeutica* 1988; **14**: 293 – 299.
- 11 Karacostas D, Giannopoulos S, Artemis N, *et al*: Effect of piracetam on myoclonus secondary to electrocution. *Acta Therapeutica* 1993; **19**: 401 – 404.
- 12 Brazis PW, Masdeu JC, Biller J: *Localization in Clinical Neurology*, 3rd edn. London: Little Brown and Co, 1996; pp436 – 438.
- 13 Bonduelle M: The myoclonias. In: *Handbook of Clinical Neurology*, vol. 25 (Vinken PJ, Bruyn GW, eds). Amsterdam: North Holland Publ Co, 1975; pp761 – 778.
- 14 Karacostas D, Artemis N, Giannopoulos S: Cortical myoclonus: a valid human model for the demonstration of the neuromodulatory effects of piracetam. *Acta Therapeutica* 1995; **21**: 77 – 84.

**D Karacostas, T Doskas, N Artemis, K Vadicolas
and I Milonas**

**Beneficial Effect of Piracetam Monotherapy on
Post-ischaemic Palatal Myoclonus**

The Journal of International Medical Research
1999; **27**: 201 – 205

Received for publication 14 June 1999

Accepted 16 June 1999

© Copyright 1999 Cambridge Medical Publications

Address for correspondence

DR D KARACOSTAS

B¹ Department of Neurology, Aristotelian University School of Medicine, AHEPA Hospital,
Thessaloniki, Greece.