

Parietal and cingulate processes in central pain. A combined positron emission tomography (PET) and functional magnetic resonance imaging (fMRI) study of an unusual case

R. Peyron^{a,b,*}, L. García-Larrea^c, M.C. Grégoire^c, P. Convers^a, A. Richard^b, F. Lavenne^c,
F.G. Barral^d, F. Mauguière^c, D. Michel^a, B. Laurent^{a,b}

^aNeurological Department, Bellevue Hospital, 42055 Saint-Etienne, France

^bPain Center, Bellevue Hospital, 42055 Saint-Etienne, France

^cCERMEP, Neurological Hospital, 59 Bd Pinel, 69003 Lyon, France

^dDepartment of Neuroradiology, Bellevue Hospital, 42055 Saint-Etienne, France

Received 26 January 1998; received in revised form 28 June 1999; accepted 15 July 1999

Abstract

Parietal, insular and anterior cingulate cortices are involved in the processing of noxious inputs and genesis of pain sensation. Parietal lesions may generate central pain by mechanisms generally assumed to involve the ‘medial’ pain system (i.e. medial thalamic nuclei and anterior cingulate cortex (ACC)). We report here PET and fMRI data in a patient who developed central pain and allodynia in her left side after a bifocal infarct involving both the right parietal cortex (SI and SII) and the right ACC (Brodmann areas 24 and 32), thus questioning the schematic representation of cortical pain processing. No rCBF increase was found in any part of the residual cingulate cortices, neither in the basal state (which included spontaneous pain and extended hypoperfusion around the infarct), nor during left allodynic pain. Thus, as previously observed in patients with lateral medullary infarct, neither spontaneous pain nor allodynia reproduce the cingulate activation observed after noxious pain in normal subjects. Conversely, both PET and fMRI data argue in favour of plastic changes in the ‘lateral discriminative’ pain system. Particularly, allodynia was associated with increased activity anteriorly to the infarct in the right insula/SII cortex. This response is likely to be responsible for the strange and very unpleasant allodynic sensation elicited on the left side by a non-noxious stimulation. © 2000 International Association for the Study of Pain. Published by Elsevier Science BV.

Keywords: Central pain; Allodynia; Post-stroke central pain; Positron emission tomography (PET); Functional magnetic resonance imaging (fMRI); Anterior cingulate cortex

1. Introduction

Parietal, insular and anterior cingulate cortices are known to have consistently regional cerebral blood flow (rCBF) increase during pain sensation in normal subjects (Talbot et al., 1991; Jones et al., 1991; Derbyshire et al., 1994, 1997; Coghill et al., 1994; Casey et al., 1994, 1996; Hsieh et al., 1995b,c; Craig et al., 1996; Vogt et al., 1996; Rainville et al., 1997; Xu et al., 1997; Svensson et al., 1997; May et al., 1998; Iadarola et al., 1998; for a review, see Laurent et al., 1999).

Parietal or insular lesions have been shown to be associated with central pain (Michel et al., 1990; Schmähmann and Leifer, 1992; for a review, see Boivie, 1994). In these

patients, the anterior cingulate cortex (ACC), which is the major site for projection of medial thalamic nuclei, has been supposed to be involved, as a part of the ‘medial’ pain system, in central pain genesis (Boivie, 1994). This theory has led to bilateral surgical lesions of the ACC or its projections (cingulotomy) to treat chronic pain (for a review, see Bouckoums, 1994). Here we report the case of one patient questioning this schematic representation of pain processing where anterior cingulate activity would be associated with pain sensation and cingulate lesion would alleviate pain.

In addition to a parietal infarct involving the parietal cortex (SI and SII), in a localization known to be associated with central pain, this unusual patient had a second lesion in the ACC (Brodmann areas, BA 24 and 32). She had a long-lasting central pain including, on the left side, hypaesthesia to noxious and thermal stimuli, spontaneous pain, hyperpathia and allodynia. We can infer from these anatomical

* Corresponding author. Tel.: +33-04-77-42-78-05; fax: +33-04-77-42-05-43.

E-mail address: r-peyron@cismun.univ-lyon1.fr (R. Peyron).

data that (i) lesion of the right cingulate does not prevent contralateral central pain and (ii) central pain generation on the left side of the body does not involve the right infarcted ACC. This observation leads us to alternative explanations: over-activation in the residual right ACC, mirror plastic changes in the left ACC, or reorganization involving other sites of pain integration.

These hypotheses were addressed using a combined PET and fMRI study where we investigated (1) the basal rCBF at rest, as a correlate for spontaneous pain, and (2) the rCBF changes in conditions involving the same stimulus (innocuous rubbing of the skin with a cold object) that did (left) or did not (right) trigger allodynia. Our hypothesis was that brain regions would be recruited during allodynia additionally to the regions which were activated by the innocuous rubbing of the skin on the non-painful side. The goal of the study was to determine, in this unusual combination of lesions, the site(s) where activity could be associated with spontaneous and/or allodynic pain sensations.

2. Case report

A 56-year-old woman was first seen 10 years ago for a right thoracic outlet syndrome which was surgically treated in May 1986. Post-operative investigations for upper-limb pain and hand ischaemia evidenced a right sub-clavian artery thrombosis treated by a carotidoaxillary bypass in October 1986. Paraesthesiae and pain were transiently observed in the anterior portion of the scapular and cervical areas and the anterior face of the right arm and were attributed to operative exposure of the brachial plexus. A deafferentation pain mechanism was suspected. Pain had spontaneously resolved 3 years later.

In 1995, a thrombosis of the bypass was evidenced and the patient was re-admitted in August to have his prosthesis changed. The surgery was complicated by arterial embolism arising from the wall of the prosthesis leading to left hemiparesis and hypaesthesia. A bifocal infarct involving the right parietal (SI and SII) and the right anterior cingulate cortices (BAs 24 and 32), respectively in the middle and the anterior carotid artery territories, was evidenced on MRI (Fig. 1). The initial left-sided hemiparesis was regressive in 2 months. Pain appeared in the left hand and foot 3 months after the stroke with progressive extension and worsening in the following months.

The patient was seen in our pain center in March 1996. She experienced abnormal pain sensations including (1) spontaneous paroxysmal pain, (2) allodynia for pressure, vibration, touch and cold stimuli (with a severe temporal summation during the repetition of stimuli) and (3) pinprick hyperpathia according to the three components of the IASP criteria (Merskey and Bogduk, 1994). She could walk alone but had signs of lemniscal dysfunction on the left side of the body (abnormal position sense, touch, pallesthesia, blind search of the left digit and stereognosia). Somatosensory

evoked potentials (SEPs) disclosed decreased amplitude of the N20 parietal response after stimulation of the left median nerve and delayed response after stimulation of the left tibial nerve. Quantitative sensory analysis (Medoc® TSA-2001) disclosed severe left hypaesthesia to warm and heat temperature (discriminative threshold 34°C and 33°C on the right side, 47°C and 39°C on the left side, for hand and foot respectively), and also to cold stimuli. Neuropsychological testing showed only moderate impairment of frontal lobe function with decreased verbal fluences, perseverations in the Wisconsin Card Sorting Test (WCST), slowing in the Trail Making test and moderate deficit in recall in Grober and Buschke memory test corrected by cues. However, a severe impairment of attentional performances was noted by her husband in daily activities, with a severely decreased decision making and initiative. The patient was treated with antidepressive drugs (clomipramine 100 mg/day) and benzodiazepines (clonazepam 2 mg/day) which could not be discontinued longer than 24 h because of rebound effect. Medications were stopped 18 and 15 h respectively before the PET and fMRI recordings, i.e. before the occurrence of a possible rebound effect. Informed consent was obtained from the patient to undergo the following PET and fMRI studies which have been accepted by the local ethic committee.

3. PET study

3.1. PET acquisition

Acquisitions were performed in 3D mode with a CTI/Siemens HR+ tomograph. Patient movements were constrained by fitting the head with a thermoplastic custom-moulded face mask (TRUE SCAN, Annapolis, MD). After a 9 mCi i.v. injection, the 60 s scan started when the true count rate reached 400% of pre-recorded background activity. Scans were corrected for attenuation using a ⁶⁸Ge transmission scan prior to emission data collection. The total irradiation dose was 7 mSv (Brihaye et al., 1995). Images were reconstructed using a filtered backprojection method (PROMIS) with a Hamm filter. The transverse and axial resulting resolution was respectively 6.3 and 6.8 mm, and voxel size was 2.025 × 2.025 × 2.425 mm³. No arterial catheter was used, so the regional blood flow variations were evaluated as differences in measured activity, assuming a linear correlation between these two quantities in the observed range (Herscovitch et al., 1983). Therefore, responses reported here are changes in radiation distribution but will be referred to as changes in blood flow.

Three conditions were studied with PET in a visually and auditory-deprived patient after injection of H₂¹⁵O in the ante-cubital vein on the non-painful side. RCBF was deliberately assessed, first at rest (six consecutive repetitions) in a single block to avoid contamination from stimulation conditions. Particularly, the allodynic condition which included a

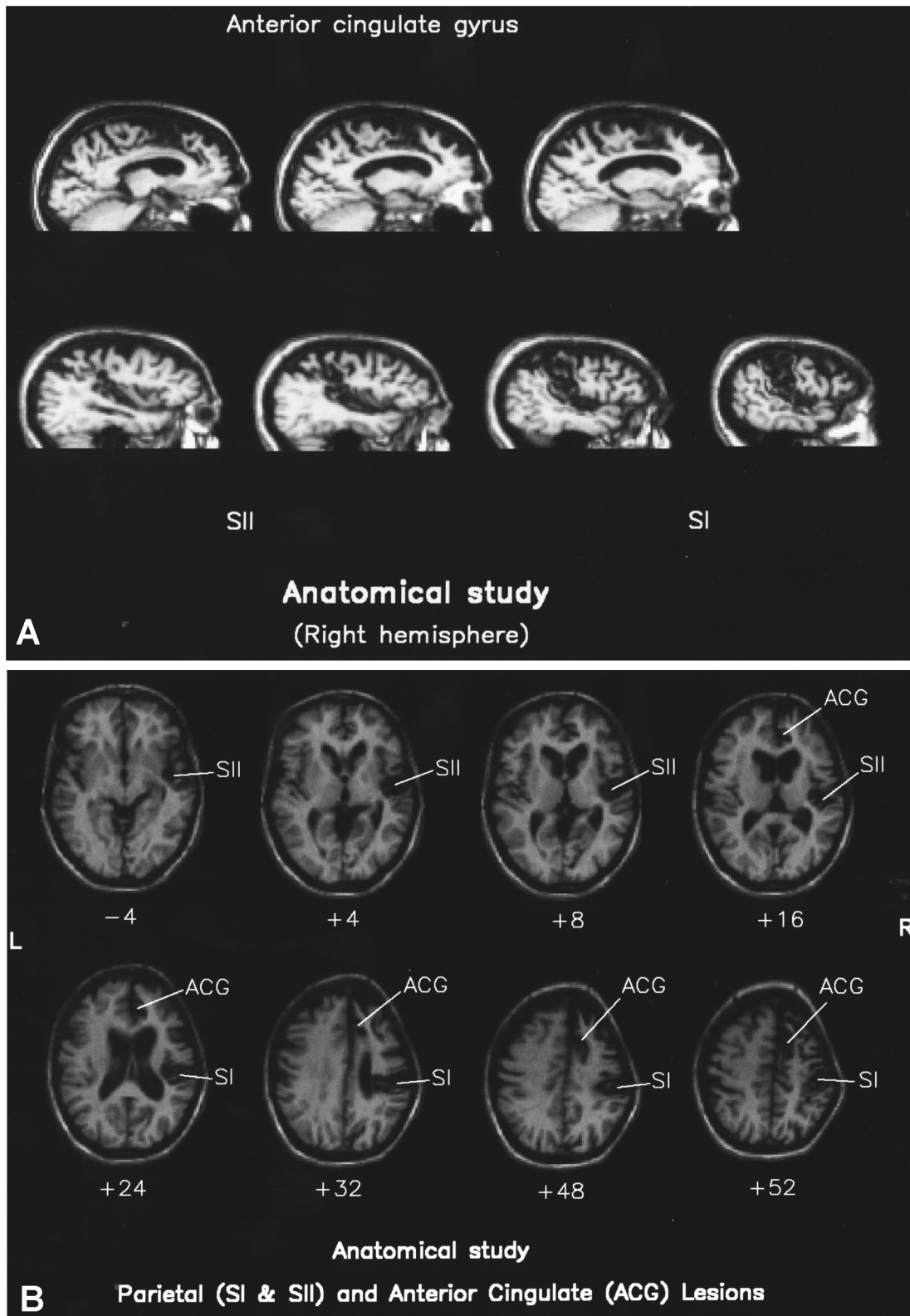


Fig. 1. Magnetic resonance imaging. (A) T1-weighted sagittal MRI showing the antero-posterior extent of the right anterior cingulate infarct. (B) T1-weighted transverse MRI normalized according to the stereotaxic atlas (Talairach and Tournoux, 1988), at the level of the right parietal and the cingulate infarct.

phenomenon of temporal summation was therefore suspected to induce possibly long-lasting haemodynamic

effects, especially in the anterior cingulate cortex which was an a priori target of our study. Then, in a second

block, to minimize time effects which might also modify the activity of anterior cingulate, the two following conditions (six repetitions) were recorded in a randomized order (1-1-2-2-1-1-2-2-2-2-1), each one being separated from the previous one by 10 min.

1. *Non-painful cold* (control condition): A cold non-noxious and non-painful stimulus (frozen water in a flat plastic container) was moved on the *right* non-hypaesthetic thigh.
2. *Allodynia*: The same stimulus, moved comparatively on the painful *left* hypaesthetic thigh was associated with an allodynic sensation. This stimulation was tested before the PET procedure in order to ensure that it was scored as painful on visual analog scale (VAS) and could be tolerated for 1 min.

Pain was evaluated in each condition of the PET procedure using two distinct parameters evaluated with a VAS: the score of the ‘average pain sensation’ during the 60 s of PET recordings and a complementary score assessing the sensation of ‘unpleasantness’ evoked by the stimulation.

3.2. PET data analysis

Data analysis was performed using the Statistical Parametric Map (spm96) software developed at the FIL (Functional Imaging Laboratory, London, UK). Patient movement between scans was corrected by a realignment procedure, then data were spatially normalized (Friston et al., 1995a) according to a stereotaxic space (Talairach and Tournoux, 1988). In order to localize accurately the activations on individual anatomy, the personal 3D T1-weighted MRI volume was co-registered to the mean PET image and normalized to the same space. The normalized PET images were then smoothed with a 3D-gaussian filter (FWHM 15 mm). Effects of variations in global activity were removed by means of a proportional scaling. The effects of the different conditions were estimated using a general linear model (Friston et al., 1995b) for each and every pixel. For each linear contrast, the resulting set of voxel values (*t*-map) was then transformed to the unit normal distribution (*Z*-map). The foci were then characterized in terms of peak height and cluster area at a given threshold ($Z = 3.09$, corrected $P \leq 0.05$).

Conditions 1 and 2 were successively compared to rest and directly compared to each other using subtraction analyses. To assess directly rCBF changes in the anterior part of insula, known to respond contralaterally to a painful stimulation in allodynic patients after lateral medullary infarct (Peyron et al., 1998), a second analysis based on regions of interest (ROIs) was performed using a 2-tailed paired-*t*-test to compare radioactive counts in the three PET conditions. In a complementary study, a subtraction analysis was performed using non-normalized PET and co-registered MRI data to exclude possible effects related to the normalization procedure.

4. fMRI study

4.1. fMRI acquisition

Acquisitions were performed on a Siemens® Magnetom Impact 1 Tesla echo-planar MRI, generating 10 brain slices (5 mm thick, voxel size $3.3 \times 3.3 \times 5$ mm) every 3 s. Brain slices were recorded according to the bi-commissural (AC-PC) plane using a 3 mm interslice gap to cover the whole brain except cerebellum. To allow correlations between PET and fMRI data, the same stimulus (rubbing of the skin with a cold plastic container) was used in both experiments. Thus, the two conditions of our PET study, namely allodynia (left thigh) and non-painful cold (i.e. control on the right thigh) were replicated in the two sessions of our fMRI paradigm. Thirty second periods of either non-painful cold (session 1) or allodynic (session 2) stimulations were alternated with 30 s periods without any stimulation (basal condition). Each 30 s condition allowed the recording of 10 brain volumes and was repeated three times within the two sessions. To avoid surprise and movement at the beginning of the stimulation, each condition was tested inside the magnet before the recording. As for the PET study, the patient was asked to keep her eyes closed during the recording and to score the mean pain sensation (30 s) on a VAS. A 3D T1-weighted MRI was recorded as the anatomical reference for both PET and fMRI studies.

4.2. fMRI data analysis

Data analysis was also performed using the spm96 software. Movement between scans was corrected by a realignment procedure. Then, the scans were normalized spatially according to the stereotaxic space (Talairach and Tournoux, 1988) and smoothed using a 10 mm filter. Allodynia and non-painful cold conditions were successively compared to basal condition as two different sessions and using a subtraction analysis and a delayed box-car model for response. Data were thresholded for peak height and cluster area at a $Z \geq 3$ value with a corrected $P \leq 0.1$. Results of the statistical maps were superimposed on the normalized personal 3D T1-weighted MRI of the patient. As for the PET study, the same comparisons were also performed on non-normalized scans to evaluate possible effects related to spatial normalization.

5. Results

5.1. Anatomical study

The stereotaxic localization of the lesion on normalized MRI (Talairach and Tournoux, 1988) showed that the infarct involved (a) the right SI cortex (Post-central gyrus, BA 3, 2 and 1), (b) a cortical area compatible with the localization of SII (anteriorly to BA40 in the upper bank of the sylvian fissure), (c) a small anterior and inferior part

of the inferior parietal lobule (BA40), (d) the rostral part of anterior cingulate gyrus (BA 24, 32) and the posterior part of medial frontal cortex (BA 8/9/10) and (e) the medial and upper frontal cortex (BA 6), an area compatible with the localization of the supplementary motor cortex.

5.2. Pain scores

We verified that allodynia was rated as significantly ($P \leq 0.01$, two-tailed paired-*t*-test) more painful and unpleasant (scores on VAS 4.43 (SD 1.1) and 3.43 (SD 1.58) respectively) than the control stimulation applied to the right (unaffected) side (scores on VAS 0 and 1.07 (SD 0.1) respectively). The same findings were observed during fMRI study.

5.3. PET study

PET recordings at rest showed a wide hypoperfusion including the infarct and widely extended around, within the frontal and parietal cortices (Fig. 2).

Conjunction analysis on allodynic and control conditions compared to rest showed a significant rCBF increase bilaterally in insula/SII and thalamus and in the right caudate while rCBF increase in the left SI cortex was immediately below the statistical threshold (Table 1). In the successive comparisons of the allodynic and the control conditions to

rest (Fig. 3A,B), identical rCBF increases were observed in the left thalamus and insula. Left parietal cortex, in the depth of SI, showed a significant increase of rCBF in the control condition which remained below the statistical threshold for the allodynic condition. In the allodynic condition only, the rCBF was significantly increased in the anterior insula/SII, immediately forward to the right parietal lesion (Fig. 3B). Sub-significant rCBF increases were observed in the head of the right caudate during control condition and in the right lateral thalamus during allodynia. No rCBF change, even at a sub-significant threshold, was observed in anterior cingulate cortices. No intra-cerebral significant rCBF decrease was observed. The results were unchanged when the study was performed on the non-normalized PET images.

Using ROIs analysis, the right anterior insula/SII cortex was shown to have significantly increased activity during allodynia compared to both basal (paired-*t*-test, $P = 0.02$) and non-painful cold ($P = 0.002$) conditions.

5.4. fMRI study

Conjunction analysis on allodynic and control conditions compared to rest showed significant signal changes bilaterally in the perisylvian temporo-insular region. No significant signal change was evidenced during the control (i.e. non-painful cold) condition compared to rest. The allodynic

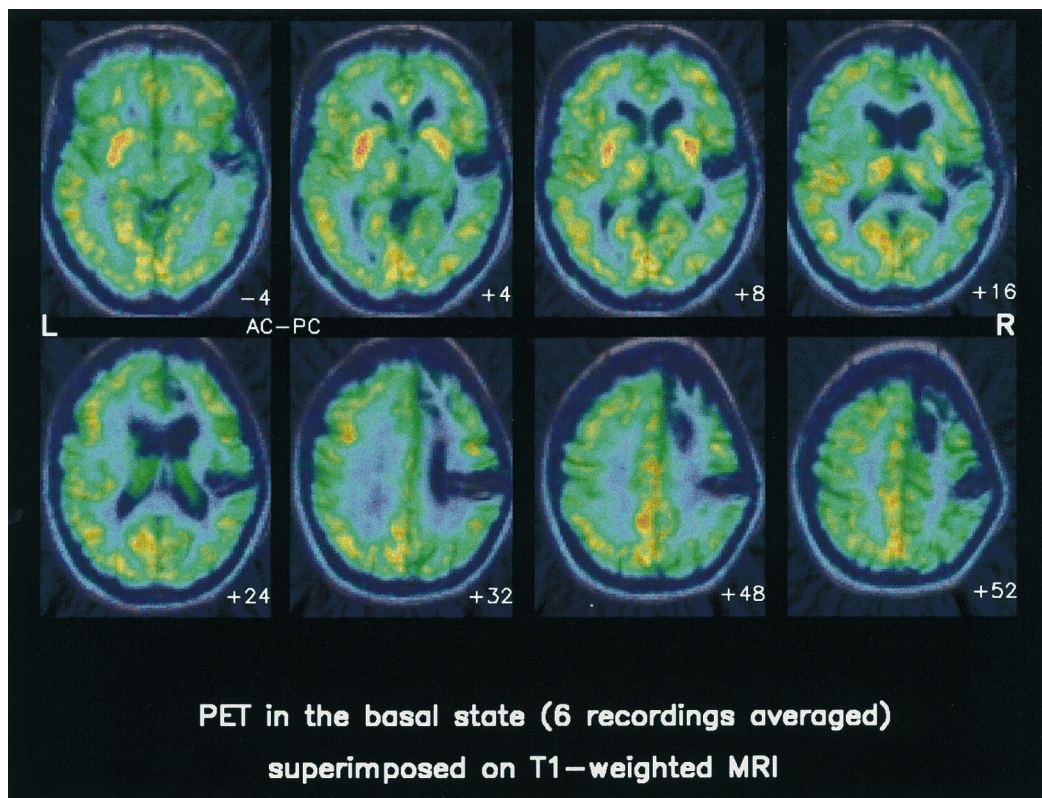


Fig. 2. PET during basal recordings (spontaneous pain). PET image obtained from the 6 basal recordings were averaged and superimposed on the three-dimensionnal MRI. The patient was at rest, with a slight (scored 0–1 on VAS) paroxysmal spontaneous pain during the recordings. Note that the extend of the hypoperfusion was larger than the anatomical lesion, particularly in the right frontal lobe. No abnormality was observed on the left cingulate cortex.

Table 1
Subtraction analysis: spm results (all comparisons performed versus basal recording)

rCBF increase										
Left										
Insula/SII			Lateral thalamus			SI			Right	
									Insula/SII	Caudate
PET	fMRI	PET	PET	fMRI	PET	PET	fMRI	PET	PET	PET
<i>Allodynia (left stimulation)</i>										
Coordinates ^a	–36, 2, –2	[–60, –4, 4] ^b	–20, –20, –2	–64, –32, 36	42, 8, 0	50, –6, 18	[54, –2, 18]	16, –22, 2	Infarct	
Z-score (peak height)	4.62	[4.86]	4.56	3.7	3.96	0.046	[4.79]	3.76	Infarct	
P (cluster)	0.002	[0.013]	0.002	n.s.	0.046	0.046	[0.02]	n.s.	Infarct	
(cluster size)	2571	[607]	2571	182	578	578	[249]	268	Infarct	
<i>Control (right stimulation)</i>										
Coordinates ^a	–36, –8, 2	–18, –22, 2	–28, –18, 32						Infarct	22, 22, 6
Z-score(peak height)	4.38	4.62	4.15						Infarct	3.98
P (cluster)	0.000	0.000	0.000						Infarct	n.s.
(cluster size)	2299	2299	2299						Infarct	332
<i>Conjunction analysis</i>										
Coordinates ^a	–34, –8, 2	[–50, –18, –2]	–20, –20, –2	–28, –16, 32	42, 8, 0	3.88	[54, 2, 16]	16, –20, 2	Infarct	
Z-score (peak height)	5.42	[5.01]	5.39	4.27	3.88	0.002	[4.68]	4.23	Infarct	4.16
P (cluster)	0.000	[0.01]	0.000	0.076	0.002	0.002	[0.035]	0.002	Infarct	0.021
(cluster size)	5421	[481]	5421	270	1867	1867	[177]	1867	Infarct	477

^a Talairach and Tournoux, 1988.

^b [] fMRI data.

condition compared to rest showed a restricted cortical area of increased signal immediately forward to the right parietal lesion, in a localization matching with PET results (Fig. 4). Increased signal in the left perisylvian temporo-insular region was also observed in a localization similar to those of the PET study except for a slight shift towards lower *z* coordinates. Results were unchanged if the study was performed on non-normalized fMRI images.

6. Discussion

This report shows that both spontaneous pain and allodynia may occur after lesions of the main cortical areas involved in pain integration, namely the SI, SII and anterior cingulate cortices (ACC). Although the association of neurological pain with parietal and SII lesions similar to those reported here has been previously described (Michel et al., 1990; Schmähmann and Leifer, 1992; for a review, see Boivie, 1994), this is to our knowledge the first report showing the association of central pain to simultaneous lesions of SI, SII and ACC.

6.1. Anterior cingulate cortex

In normal subjects, the *anterior cingulate* cortex is known to exhibit increased rCBF to pain (Talbot et al., 1991; Jones et al., 1991; Derbyshire et al., 1994, 1997; Coghill et al., 1994; Casey et al., 1994, 1996; Hsieh et al., 1995b,c; Craig et al., 1996; Vogt et al., 1996; Rainville et al., 1997; May et al., 1998) and to correlate with the ‘unpleasantness’ of pain sensation (Craig et al., 1996; Rainville et al., 1997). Left allodynic sensations provoked by capsaicin in normal subjects were associated also with a significant increase of rCBF in the right ACC (Iadarola et al., 1998), as did ongoing neuropathic pain in patients (Hsieh et al., 1995a). Therefore, it appears reasonable to hypothesize that allodynia after central lesions would also increase rCBF in ACC. Our observations that both spontaneous pain and allodynia can coexist with destruction of the contralateral ACC and this, without any sign of hyperactivity in the spared ACC despite the bilateral distribution of cingulate receptive fields (Sikes and Vogt, 1992; Dostrovsky et al., 1995), argues against this view. These findings suggest that the neural mechanisms of pain and allodynia substantially differ in normal subjects and in patients with central lesions. This is consistent with previous findings in a sample of patients with Wallenberg’s syndrome (Peyron et al., 1996, 1998) and suggest (i) that increased ACC blood flow is not necessary for allodynia to occur, but also (ii) that a decreased (or at least a failure to increase) rCBF in this structure may be significantly associated with the allodynic experience of patients with central pain.

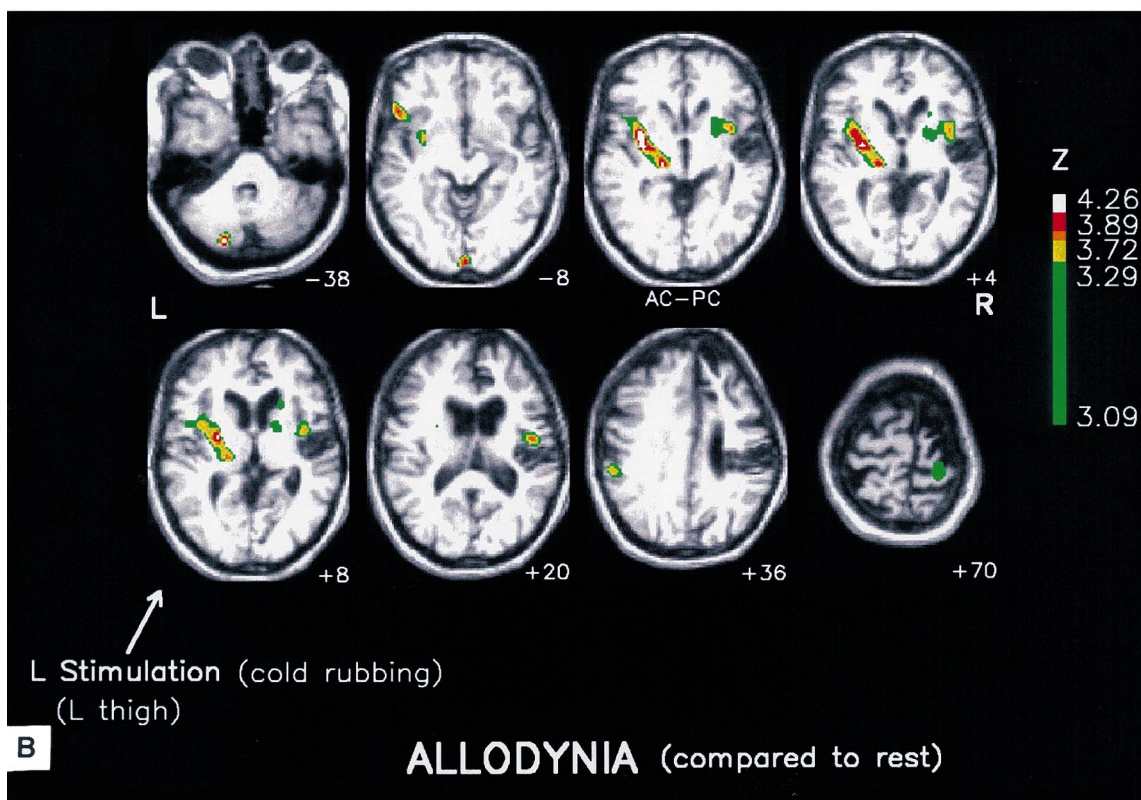
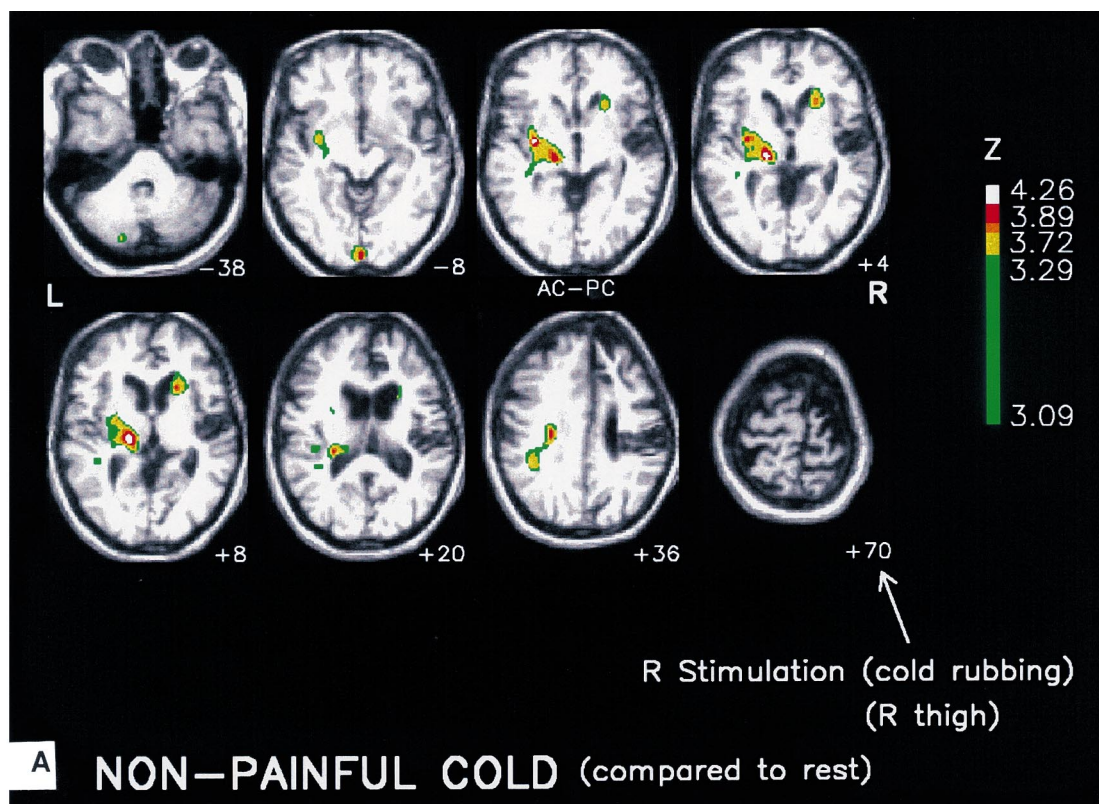
6.2. Insular and secondary somato-sensory cortices

A very different behaviour was observed in the *insular*

and *secondary somato-sensory* regions involved by the lesion, since allodynia induced significant rCBF increase at the boundaries of the insular/SII infarct (Figs. 3B and 4). This activity could not depend on artefact from PET data analysis (i.e. partial volume effect, stereotaxic normalization or realignment misfit) since it was consistently obtained with both PET and fMRI, using both normalized and non-normalized data, and since there was no overlapping between these activities and the parietal infarct (Figs. 3B and 4). Thus, in this patient, the innocuous stimuli generating abnormal allodynic sensations evoked increased rCBF in the residual contralateral SII/insula areas. Because of constraints related to the techniques (i.e. radiation doses, the need of scan repetitions for single subject analysis) and the characteristics of pain in this patient, other conditions which might have been decisive to prove the real specificity of this response to allodynia could not be added to the recording session. Thus, a non-painful (i.e. non-allodynic) left-sided stimulation could not be applied since every light touch was sufficient to induce allodynia. On the other hand, the possible use of a truly noxious stimulation to the affected side, to compare with an allodynic one, was not ethically conceivable because of severe hypaesthesia exposing to skin lesions. Consequently, the interpretation of the insular/SII response in terms of specificity for allodynia may appear as incomplete and to a certain point speculative. There are, however, a handful of arguments supporting a connection between SII/insular activity and allodynia. First, in our patient, the SII/insular activity was significantly higher during allodynia than in any of the other conditions and second, it was bilateral in the case of allodynic stimulation and strictly unilateral during cold stimulation on the normal side. This activity recalled that described in previous literature as participating to pain processing in normal subjects (Talbot et al., 1991; Coghill et al., 1994; Casey et al., 1994, 1996; Hsieh et al., 1995b,c; Craig et al., 1996; Rainville et al., 1997; Derbyshire et al., 1997; Svensson et al., 1997; Xu et al., 1997; May et al., 1998; Peyron et al., 1999). The fact that a pain-like response appears to an innocuous stimulus suggests abnormal response amplification of the stimulus transfer function from non-painful to painful ranges, as previously assumed to occur in Wallenberg patients with allodynia (Peyron et al., 1998). From this standpoint, we may speculate that the combination of increased insula/SII and decreased ACC activities to innocuous stimuli might be one pattern of brain responses ‘specifically’ associated to allodynia in central nervous system lesion.

6.3. Responses of SI cortices and regions ipsilateral to stimulation

The right *primary somatosensory* cortex was only partially deafferented as shown by the sparing of early cortical SEPs. Thus, there was a possibility that the residual SI cortex could contribute to the integration of allodynia, a



hypothesis not confirmed by our data. The low sensitivity of the PET- ^{15}O technique cannot explain this result since the

same stimulation applied on the normal side was sufficient to induce detectable rCBF increase in the contralateral SI.

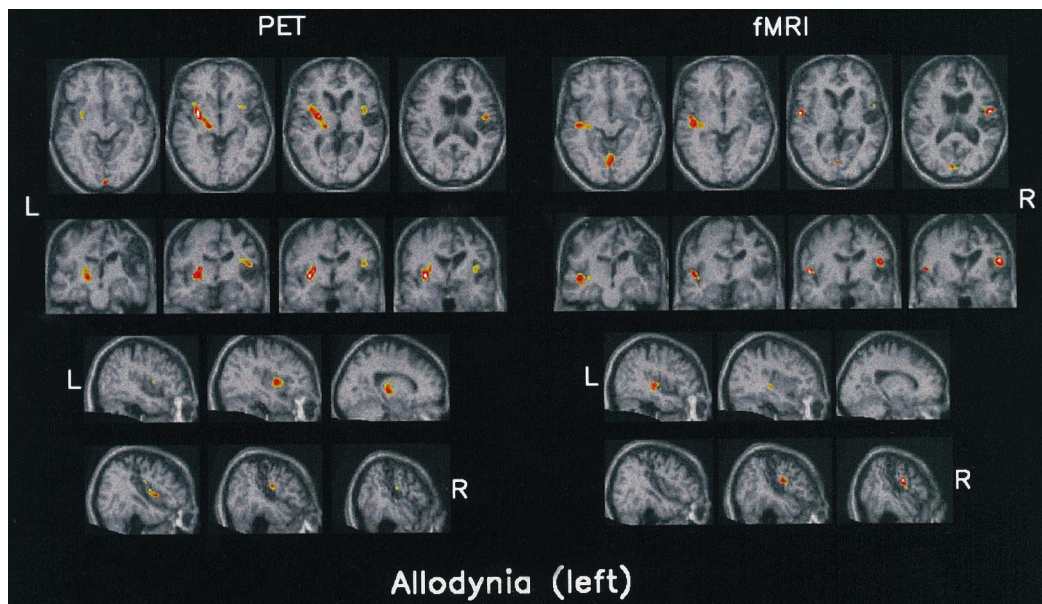


Fig. 4. PET and fMRI correlations. PET (Fig. 3B) and fMRI data are superimposed on the 3D T1-weighted MRI of the patient, normalized according to the stereotaxic atlas (Talairach and Tournoux, 1988). The same normalized slices are shown comparatively for PET and fMRI. The z positions for transverse slices with reference to AC-PC plane are -8 mm (left), -2 mm, $+6$ mm, $+20$ mm (right). Sagittal and coronal slices are centred on insular/SII activity. On illustration, for both PET and fMRI, thresholds for peak height and probability for cluster areas were $Z \geq 3$ and corrected $P \leq 0.05$, respectively. Allodynia (compared to rest): Left allodynia was associated with increased rCBF in the left thalamo-insular region. The matching fMRI signal change was located in more external location than rCBF increase and signal changes did not involve the left thalamus. Conversely, note that the localization of both signal and rCBF changes were very similar in the anterior part of the right insula/SII cortex, immediately forward to the infarct. This later response only seems particular to the allodynic painful sensation.

These findings led to the conclusion that the right SI and surrounding parietal cortices do not seem to participate in the mechanisms of allodynic pain in this patient, in accordance with previous findings of allodynia in cases with complete SI deafferentation or destruction (Schott et al., 1986; Mauguière and Desmedt, 1988; Holmgren et al., 1990; Michel et al., 1990) and with previous work showing that neuropathic pain can occur in the absence of SI activation (Hsieh et al., 1995a). SI activity contralateral to stimulation being proposed as mediating thermal (Casey et al., 1996; Craig et al., 1996) and/or moving (Jones and Derbyshire, 1995) aspects of pain discrimination, the absence of SI activity during allodynia could likely reflect, in our patient, a decreased ability to discriminate these aspects of pain sensation.

One salient feature of this patient was the presence,

during the allodynic condition, of prominent responses in the hemisphere ipsilateral to the stimulation. Such ipsilateral responses concerned the insular/SII region and the lateral thalamic area, and, at a sub-significant level, also the ipsilateral SI region. If we consider that an abnormal transfer of information on stimulus energy (i.e. switch from 'innocuous' into 'noxious' ranges) is at the basis of the allodynic sensation, then the ipsilateral rCBF increase in SII and insula could be simply interpreted as the ipsilateral component of a bilateral pain response. Although bilateral responses of SII and anterior insula are commonly observed during pain (Casey et al., 1994, 1996; Hsieh et al., 1995b,c; Derbyshire et al., 1997; Xu et al., 1997; May et al., 1998; Peyron et al., 1999), this cannot account for increased rCBF on the ipsilateral thalamus and the SI cortex. An alternative explanation of this set of ipsilateral responses would be a

Fig. 3. PET during stimulations. In the two following comparisons, 6 rCBF sets were compared to the 6 basal recordings using the spm96 software and a proportional scaling analysis. The spatial distribution of rCBF increases were superimposed on MRI slices of the patient recorded, realigned and normalized (as were PET recordings) according to the bi-commissural plane. On illustrations, thresholds for peak height and probability for cluster areas were 3 and 0.2 for Z -score and corrected P , respectively. Thresholds in the corresponding Table 1 were 3 and 0.05 for Z -score and corrected P for cluster areas, respectively. Localization of brain areas was assessed by means of a brain atlas (Talairach and Tournoux, 1988). (A) Control condition: rCBF recorded during the control conditions (non-noxious cold stimulation moved on the right thigh) was compared to the basal recordings. Stimulation was non-painful (score on VAS 0 for pain sensation and 1.07 (S.D. 0.1) for 'unpleasantness'). rCBF was significantly increased in the left thalamo-insular area, in the depth of the left SI cortex and sub-significantly in the right caudate (Table 1). (B) Allodynia: rCBF recorded during allodynia (the same cold non-noxious stimulus as used in (A), moved on the left hypaesthetic thigh) was compared to the basal recordings. Stimulation was painful (score on VAS 4.43 (S.D. 1.1) for pain sensation and 3.43 (S.D. 1.58) for the sensation of 'unpleasantness'). In addition to the left thalamo-insular rCBF increase which was also observed in the control condition, rCBF was significantly increased in the right anterior insular/SII cortices, immediately forward to the infarct (see Table 1). Only this later response seems particular to the allodynic painful sensation. Sub-significant rCBF increases were additionally observed in the left SI cortex.

plastic (mirror) reorganization of somatosensory circuits after the extensive infarct of the right hemisphere, as previously described during motor function recovery (Chollet et al., 1991) and peripheral denervation (Calford and Tweedale, 1990).

6.4. Comparisons between PET and fMRI data

Although there was in general a very good agreement between the findings with both techniques (Table 1), the left thalamic activity was not identified using fMRI, probably because of the poor sensitivity of this technique to explore deep structures. Also, the spatial matching of the left perisylvian responses was not perfect and the non-noxious cold stimulation compared to rest did not induce significant fMRI signal change. This does not admit a simple explanation unless we postulate some sensitivity bias due to our 1 T magnet, or from slight differences in the acquisition procedure. Despite these minor inconsistencies, the fMRI results obtained for the allodynic condition as well as the conjunction analysis, fit accurately with PET and this report is to our knowledge the first one to record fMRI signal changes during allodynia.

In conclusion, this study shows that spontaneous pain and allodynia may occur after simultaneous lesions of the main cortical areas involved in pain integration, namely the SI, SII and the right anterior cingulate cortices. While noxious pain in normal subjects is reliably associated with increased activity in anterior cingulate, allodynic pain does not seem to induce the same rCBF increase. This paradoxical absence of response could partly account for the subjective experience of the allodynic sensation, often described as strange, strongly unpleasant, and unknown from the biographic experience of the patient. Our study provides arguments for plastic changes after stroke on somatosensory and pain pathways with a possible 'mirror' reorganization of ipsilateral thalamo-insular, SII and SI areas. Finally, the enhanced insular/SII activity neighbouring the infarct, triggered by non-noxious stimuli, appeared particular to the allodynic sensation. This activity might reflect an abnormal transfer function between a non-noxious input and the distorted perception of the stimulus which defines allodynia.

Acknowledgements

We wish to thank the patient who accepted these PET and fMRI recordings, the CERMEP and the Department of Neuroradiology teams for PET and fMRI recordings, respectively.

References

- Boivie J. Central pain, Textbook of pain, 3rd. Edinburgh: Churchill Livingstone, 1994 pp. 871–902.
- Bouckoums AJ. Limbic surgery of pain, Textbook of pain, 3rd. Edinburgh: Churchill Livingstone, 1994 pp. 1171–1187.
- Brihaye C, Depresseux JC, Comar D. Radiation dosimetry for bolus administration of oxygen-15-water. *J Nucl Med* 1995;36:651–656.
- Calford MB, Tweedale R. Interhemispheric transfer of plastic changes in the cerebral cortex. *Science* 1990;249:805–807.
- Casey KL, Minoshima S, Berger KL, Koeppe RA, Morrow TJ, Frey KA. Positron emission tomographic analysis of cerebral structures activated specifically by repetitive noxious heat stimuli. *J Neurophysiol* 1994;71:802–807.
- Casey KL, Minoshima S, Morrow TJ, Koeppe RA. Comparison of human cerebral activation patterns during cutaneous warmth, heat pain and deep cold pain. *J Neurophysiol* 1996;76:571–581.
- Chollet F, DiPiero V, Wise RJS, Brooks DJ, Dolan RJ, Frackowiak RSJ. The functional anatomy of motor recovery after stroke in humans: a study with Positron Emission Tomography. *Ann Neurol* 1991;29:63–71.
- Coghill RC, Talbot JD, Evans AC, Meyer E, Gjedde A, Bushnell MC, Duncan GH. Distributed processing of pain and vibration by the human brain. *J Neurosci* 1994;14:4095–4108.
- Craig AD, Reiman EM, Evans A, Bushnell MC. Functional imaging of an illusion of pain. *Nature* 1996;384:258–260.
- Derbyshire SWG, Jones AKP, Devani P, Friston KJ, Feinmann C, Harris M, Pearce S, Watson JDG, Frackowiak RSJ. Cerebral responses to pain in patients with atypical facial pain measured by positron emission tomography. *J Neurol Neurosurg Psychiatry* 1994;57:1166–1172.
- Derbyshire SWG, Jones AKP, Gyulai F, Clarck S, Townsend D, Firestone LL. Pain processing during three levels of noxious stimulation produces differential patterns of central activity. *Pain* 1997;73:431–445.
- Dostrovsky JO, Hutchison WD, Davis KD, Lozano A. Potential role of orbital and cingulate cortices in nociception. In: Besson JM, Guilbaud G, Ollat H, editors. Forebrain areas involved in pain processing, Paris: John Libbey Eurotext, 1995. pp. 171–181.
- Friston KJ, Ashburner J, Frith CD, Poline JB, Heather JD, Frackowiak RSJ. Spatial registration and normalization of images. *Human Brain Mapping* 1995a;3(3):165–189.
- Friston KJ, Holmes AP, Worsley KJ, Poline JB, Frith CD, Hsieh JC, Frackowiak RSJ. Statistical parametric maps in functional imaging: a general linear approach. *Human Brain Mapping* 1995b;4(2):189–210.
- Herscovitch P, Markham J, Raichle ME. Brain blood flow measured with intravenous H₂O¹⁵ I. Theory and error analysis. *J Nucl Med* 1983;24:782–789.
- Holmgren H, Leijon G, Boivie J, Johansson I, Ilievskia L. Central post-stroke pain-somatosensory evoked potentials in relation to location of the lesion and sensory signs. *Pain* 1990;40:43–52.
- Hsieh JC, Belfrage M, Stone-Elander S, Hansson P, Ingvar M. Central representation of chronic ongoing neuropathic pain studied by positron emission tomography. *Pain* 1995a;63:225–236.
- Hsieh JC, Hägermark O, Ståhle-Bäckdahl M, Nordell B, Ericson K, Eriksson L, Stone-Elander S, Ingvar M. The urge to scratch represented in the human cerebral cortex during Itch; PET and fMRI study. *Human Brain Mapping* 1995b;(Suppl. 1):185.
- Hsieh JC, Ståhle-Bäckdahl G, Hägermark O, Stone-Elander S, Rosenquist G, Ingvar M. Traumatic nociceptive pain activates the hypothalamus and the periaqueductal gray: a positron emission tomography study. *Pain* 1995c;64:303–314.
- Iadarola MJ, Berman KF, Zeffiro TA, Byas-Smith MG, Gracely RH, Max MB, Bennett GJ. Neural activation during acute capsaicin-evoked pain and allodynia assessed with PET. *Brain* 1998;121:931–947.
- Jones AKP, Derbyshire SWG. PET imaging of pain-related somatosensory cortical activity. In: Bromm B, Desmedt JE, editors. Pain and the brain: from nociception to cognition, advances in pain research and therapy, Vol. 22, 1995.
- Jones AKP, Brown WD, Friston KJ, Qi LY, Frackowiak RSJ. Cortical and subcortical localization of response to pain in man using positron emission tomography. *Proc R Soc London, Ser. B* 1991;244:39–44.
- Laurent B, Peyron R, Garcia-Larrea L. La tomographie par émission de positons (TEP) comme moyen d'étude de l'intégration centrale de la douleur. *Rev Neurol* 1999 in press.

- Mauguière F, Desmedt JE. Thalamic pain syndrome of Déjerine-Roussy. Differentiation of four subtypes assisted by somatosensory evoked potentials data. *Arch Neurol* 1988;45:1312–1320.
- May A, Kaube H, Büchel C, Eichten C, Rijntjes M, Jüptner M, Weiller C, Diener HC. Experimental pain elicited by capsaicin: a PET study. *Pain* 1998;74:61–66.
- Merskey H, Bogduk N. Classification of chronic pain: descriptions of chronic pain syndromes and definition of pain terms, Seattle, WA: IASP Press, 1994.
- Michel D, Laurent B, Convers P, Garcia-Larrea L, Le Bas JF, Mauguière F, Schott B. Douleurs corticales. Etude clinique, électrophysiologique et topographique de 12 cas. *Rev Neurol* 1990;146:405–414.
- Peyron R, Garcia-Larrea L, Grégoire MC, Convers P, Cinotti L, Michel D, Mauguière F, Laurent B. Positron Emission Tomography (PET) evidence of Cerebral Blood Flow (CBF) abnormalities in patients with neurological pain after lateral-medullary infarct (Wallenberg's syndrome WS), VIIIth World Congress on Pain, Vancouver, August 1996.
- Peyron R, García-Larrea L, Grégoire MC, Convers P, Lavenne F, Mauguière F, Michel D, Laurent B. Haemodynamic brain responses to acute pain in humans: sensory and attentional networks. *Brain* 1999;122:1765–1779.
- Peyron R, García-Larrea L, Grégoire MC, Convers P, Lavenne F, Veyre L, Laurent B, Froment JC, Mauguière F, Michel D. Allodynia after lateral-medullary (Wallenberg) infarct. A Positron Emission Tomography (PET) study. *Brain* 1998;121:345–356.
- Rainville P, Duncan GH, Price DD, Carrier B, Bushnell MC. Pain affect encoded in human anterior cingulate but not somatosensory cortex. *Science* 1997;277:968–971.
- Schmahmann JD, Leifer D. Parietal pseudothalamic pain syndrome. Clinical features and anatomic correlates. *Arch Neurol* 1992;49:1032–1037.
- Schott B, Laurent B, Mauguière F. Les douleurs thalamiques: étude critique de 43 cas. *Rev Neurol* 1986;142:305–308.
- Sikes RW, Vogt BA. Nociceptive neurons in area 24 of rabbit cingulate cortex. *J Neurophysiol* 1992;68:1720–1732.
- Svensson P, Minoshima S, Beydoun A, Morrow TJ, Casey KL. Cerebral processing of acute skin and muscle pain in humans. *J Neurophysiol* 1997;78:450–460.
- Talairach J, Tournoux P. Coplanar stereotaxic atlas of the human brain, Stuttgart: Thieme, 1988.
- Talbot JD, Marrett S, Evans AC, Meyer E, Bushnell MC, Duncan GH. Multiple representations of pain in human cerebral cortex. *Science* 1991;251:1355–1358.
- Vogt BA, Derbyshire S, Jones AKP. Pain processing in four regions of human cingulate cortex localized with co-registered PET and MR imaging. *Eur J Neurosci* 1996;8:1461–1473.
- Xu X, Fukuyama H, Yazawa S, Mima T, Hanakawa T, Magata Y, Kanda M, Fujiwara N, Shindo K, Nagamine T, Shibasaki H. Functional localization of pain perception in the human brain studied by PET. *NeuroReport* 1997;8:555–559.