

Acute Brainstem Symptoms Associated with Cervical Syringomyelia

Saskia H. Meves Thomas Postert Horst Przuntek Thomas Büttner

Department of Neurology, St. Josef Hospital, Ruhr University of Bochum, Germany

Key Words

Syringomyelia · Brainstem symptoms · Pathomechanism

Abstract

Syringomyelia classically presents with slowly progressing dissociated sensory and upper and lower motor deficits. Atypical and acute manifestations have rarely been described. We report here on 3 patients with syringomyelia, who had acute and atypical brainstem symptoms with regard to the underlying disease. These symptoms occurred after acute elevation of the intrathoracic and intra-abdominal pressure, respectively, and remitted subsequently. Vertebrobasilar ischemia was initially suspected.

Copyright © 2000 S. Karger AG, Basel

Introduction

Syringomyelia, an abnormal cyst formation of the spinal cord, has hitherto been clinically defined as a chronic progressive neurological disorder with typical motor and sensory dysfunctions. During the last few years, attention has been focussed on patients without these former characteristic features of syringomyelia. By means of MRI and

CT, syringomyelia can be detected in earlier stages of the disease, in patients with only small cyst formations and in patients with mild or atypical symptoms [1]. Recent reports also document acute and atypical presentations of syringomyelia [2-5].

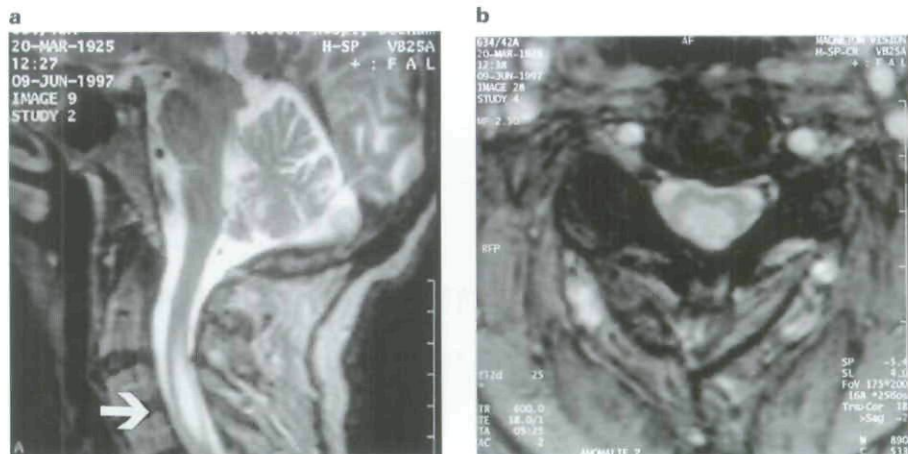
We report on 3 patients with acute brainstem symptoms which were attributable to a syringomyelia. These manifestations were acutely caused or aggravated by the same pathogenetic mechanism and were partially even reproduced by another additional exposure to this specific mechanism.

Case Reports

Patient 1

A 73-year-old man came as an emergency patient because of sudden onset of rotatory vertigo, nystagmus with a rotatory component, dysarthria and dysphagia, which lasted 4 h. After an initial rapid remission of these symptoms, he experienced a second episode 24 h later, which also resolved in the same time period. These symptoms occurred initially after a severe cough attack. He had been suffering from cervical syringomyelia for more than 30 years with typical chronic progressive sensory and motor dysfunction. Cervical MRI revealed a syrinx formation beginning at the level of the foramen magnum and reaching downwards to Th2. MRI of the brain revealed multiple small periventricular ischemic lesions of the medullary layer without presentation of an acute ischemic lesion, especially in the brainstem area, which could be related to the above-described symptoms. Furthermore, no syrinx formation was found in the brainstem.

Fig. 1. MRI of the cervical spine of patient 3. Syring formation from C1 to C3 (arrow). **a** Sagittal section (T_{2w} technique). **b** Horizontal section (T_{2*} technique).



EEG performed on different occasions was normal. The acoustic evoked potentials could not be interpreted due to the patient's partial deafness. In color-coded ultrasound, a right stenosis of the internal carotid artery of 80% was visualized, which was operated later on. Three months later, he presented himself again as an emergency case after developing similar symptoms on getting out of bed. After another 24-hour initial remission, he developed an acute attack as he got out of bed. It took him an entire day to recover from this attack.

Patient 2

A 64-year-old man first came as an emergency patient because of an acute worsening of a known slowly progressing gait disorder. He showed signs of ataxia and horizontal nystagmus which had not been previously described. In the clinical examination and the electrophysiological studies, a polyneuropathy became apparent. Furthermore, on MRI, a syring formation was found in the cervical spinal cord from C1 to C2. Ischemic lesions were not discovered in the cerebrum nor in the brainstem. EEG, extracranial color-coded duplexsonography and transcranial pw ultrasound were all normal. One year later, he came again because of an acute exacerbation of his symptoms after bending down for a bowel movement. Before this episode, he was able to walk using a cane. In this new situation, he needed two helpers to stand up straight. It took him about a week to recover from this episode.

Patient 3

A 72-year-old man was admitted to the hospital because of an acute left nerve IX and XII palsy accompanied by severe pain in the sensory dermatomes of C2 and C3, which appeared after sneezing. Besides a disturbed temperature perception in the area of the C4 dermatome on the left, no other neurological deficits were evident. MRI revealed a not previously detected syring formation extending from C1 to C3 (fig. 1). MRI of the brain was normal. EEG, extracranial color-coded duplexsonography and acoustic and visual evoked potentials provided normal findings. EMG and ENG showed signs of a discrete polyneuropathy, but the somatosensory evoked potentials failed to demonstrate a central conduction disturbance. The symptoms improved over the next week. During the following year, he was admitted twice to the hospital because of the reoccurrence of the same symptoms after sneezing.

Discussion

The pathogenetic origin and the progressive enlargement of syringomyelias have been discussed controversially in the literature. Gardner [6] assumed that the intracranial arterial pulse wave, transmitted by a gentle water-hammer effect, presses ventricular fluid through the central canal initiating a dissection and cyst formation. Williams [7] proposed that venous pressure changes cause an obstruction of the normal drainage of cerebrospinal fluid through the spinal subarachnoid space leading to an enlargement of a preexisting syring. Such pressure changes are encountered during postural changes and Valsalva maneuvers. Hall et al. [8] supported Williams' theory that transmission of thoracic pressures to the subarachnoid space might possibly lead to a compression of the syring and by that to an enlargement of the lesion. Oldfield et al. [9] suggested that coughing or sneezing could explain the occasional progression of neurological deficits in syringomyelia. The increase in intrathecal pressure during coughing, sneezing or severe straining might affect the cord surface. In our cases, the development of acute symptoms was preceded by a sudden increase in intrathoracic and intra-abdominal pressure during sneezing, coughing and straining, respectively. In 1 patient, repetitive sneezing even caused identical paroxysmal symptoms. Exercise and Valsalva maneuvers can also lead to acute presentations in syringomyelia [5].

Formerly, the diagnosis of syringomyelia was primarily based on its typical clinical presentations of varied degrees of slowly progressive motor and sensory deficits. The development of new diagnostic procedures such as MRI necessitates a new approach to syringomyelia. Especially patients with small cyst formations and without

characteristic signs have been overlooked in previous studies concerning the clinical features of syringomyelia [1]. There have been more reports on acute symptoms, which could even be the first manifestation of syringomyelia, as in one of our cases. Furthermore, a collection of atypical symptoms of syringomyelia has accumulated. Reports exist on acute respiratory failure [2], bladder disturbances [1, 3] and brainstem symptoms [4], such as we encountered in our patients. Typical symptoms, such as dissociated sensory disturbances, can even be found missing in older patients with syringomyelia [10]. Due to the relapsing course of the disease and periventricular hypodensities on MRI in elderly patients, the misleading diagnosis of encephalomyelitis disseminata [10] or of recurring cerebrovascular ischemia, as in our patients, can be made. Because of the age of our patients, we initially assumed their having ischemia in the vertebrobasilar region. In the ensuing diagnostic assessment of these patients, no cerebrovascular ischemic event could be related to their symptoms. However, we cannot definitely exclude the existence of microlacunae due to small vessel disease, which could not be demonstrated on MRI. Nevertheless, the cause of their symptoms was seen in the cervical syringomyelia mimicking vertebrobasilar ischemia.

Even though MRI facilitates the diagnosis of syringomyelia, syringobulbia might still be difficult to be detected on MRI [4] and could mimic other diseases. Anwer and Fisher [4] presented 3 cases with symptoms of the brainstem, which they explained by an extension of a cervical syrinx which would not be revealed by MRI. Zager

et al. [5] related acute brain symptoms in syringomyelia to an ischemic or mechanical distortion of the brainstem by means of an acute expansion of an existing cervical syrinx. In our 3 patients with cervical syringomyelia, acute presentations manifested after Valsalva maneuvers and time-limited affection of the brainstem due to extension of the syrinx was assumed. Low flow ischemic events in relation to Valsalva maneuvers must also be considered as a potential cause of the symptoms, but one would expect a more general reaction of the brain than those localized symptoms. An Arnold-Chiari malformation, which could also have produced the acute deficits, was missing in all 3 patients. Symptoms in these patients remained transient as the edema, caused by mechanical compression, receded. A surgical intervention was refrained from because of the only transient worsening of the symptoms and the only slowly progressive courses of the disease.

Even though syringomyelia has been known for years for its variability in presentation due to its location and extension, new aspects must be considered regarding its clinical presentations. New diagnostic procedures enable a much higher degree of insight. Cases with acute presentations also allow a better view of the pathomechanic origin of syringomyelias. On the other hand, syringomyelia may be the cause of acute neurological symptoms referring to the brainstem, which could be misdiagnosed as vertebrobasilar stroke. Acute brainstem symptoms should therefore take syringomyelia as a differential diagnosis into account, and MRI should include the upper cervical myelon to exclude a cervical syrinx.

References

- 1 Tashiro K, Fukazawa T, Moriwaka F, Hamada T, Isu T, Iwasaki Y, Abe H: Syringomyelic syndrome: Clinical features in 31 cases confirmed by CT myelography or magnetic resonance imaging. *J Neurol* 1987;235:26–30.
- 2 Alvarez D, Requenta I, Arias M, Valdes L, Pereira I, De la Torre R: Acute respiratory failure as the first sign of Arnold-Chiari malformation associated with syringomyelia. *Eur Respir J* 1995;8:661–663.
- 3 Amoiridis G, Meves S, Schöls L, Przuntek H: Reversible urinary retention as the main symptom in the first manifestation of a syringomyelia. *J Neurol Neurosurg Psychiatry* 1996;61:407–408.
- 4 Anwer UE, Fisher M: Acute and atypical presentations of syringomyelia. *Eur Neurol* 1996;36:215–218.
- 5 Zager EL, Ojemann RG, Poletti CE: Acute presentations of syringomyelia – Report of three cases. *J Neurosurg* 1990;72:133–138.
- 6 Gardner WJ: Hydrodynamic mechanism of syringomyelia: Its relationship to myelocoele. *J Neurol Neurosurg Psychiatry* 1965;28:247–259.
- 7 Williams B: The distending force in the production of 'communicating' syringomyelia. *Lancet* 1969;69:189–193.
- 8 Hall P, Turner M, Aichinger S, Bendick P, Campbell R: Experimental syringomyelia. *J Neurosurg* 1980;52:812–817.
- 9 Oldfield EH, Muraszko K, Shawker TH, Patronas NJ: Pathophysiology of syringomyelia associated with Chiari I malformation of the cerebellar tonsils. *J Neurosurg* 1994;80:3–15.
- 10 Basedow-Rajwicz B, Pöllmann W, König N: Syringomyelie, eine zu wenig beachtete Differentialdiagnose der multiplen Sklerose. *Nervenarzt* 1995;66:630–633.

Copyright: S. Karger AG, Basel 2000. Reproduced with the permission of S. Karger AG, Basel.
Further reproduction or distribution (electronic or otherwise) is prohibited without permission
from the copyright holder.