

S. Susa  
M. Daimon  
Y. Morita  
M. Kitagawa  
A. Hirata  
H. Manaka  
H. Sasaki  
T. Kato

## Acute intermittent porphyria with central pontine myelinolysis and cortical laminar necrosis

Received: 14 October 1998  
Accepted: 8 February 1999

S. Susa · M. Daimon (✉) · Y. Morita ·  
M. Kitagawa · A. Hirata · H. Manaka ·  
H. Sasaki · T. Kato  
Third Department of Internal Medicine,  
Yamagata University School of Medicine,  
2-2-2 Iida-Nishi, Yamagata 990-9585, Japan  
e-mail: mdaimon@med.id.yamagata-u.ac.jp  
Tel.: + 81-23-6285316  
Fax: + 87-23-6285318

**Abstract** Acute intermittent porphyria (AIP) is an autosomal-dominant disease caused by a deficiency of porphobilinogen (PBG) deaminase. Patients with AIP present with neurological syndromes such as autonomic neuropathy, peripheral axonal neuropathy or central nervous system dysfunction. We report serial MRI of a patient with AIP who had cortical and subcortical cerebral changes. A 29-year-old woman with a 6-month history of AIP had an attack with severe hyponatraemia and generalised convulsions, treated

with haem arginate and supportive therapy. MRI showed central pontine and extrapontine myelinolysis and cortical laminar necrosis. These are not common in AIP, but are likely to have been caused by rapid correction of hyponatraemia and by vasospasm, which could be induced by AIP.

**Key words** Porphyria, acute intermittent · Encephalopathy, porphyric · Myelinolysis, central pontine · Necrosis, cortical laminar · Magnetic resonance imaging

### Introduction

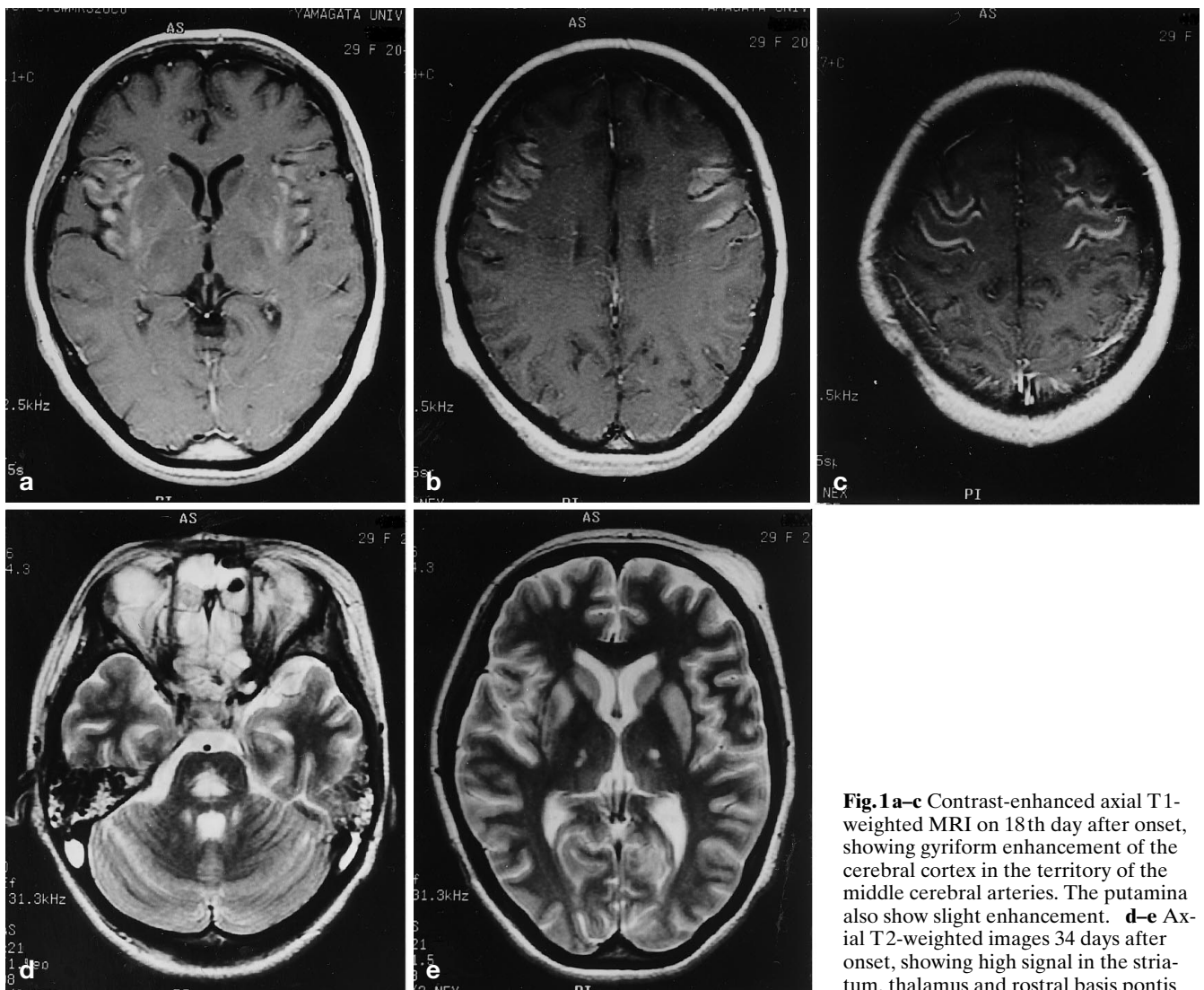
Acute intermittent porphyria (AIP), an autosomal-dominant disease, is caused by a deficiency of porphobilinogen (PBG) deaminase [1]. Patients with this disease present with a neurological syndrome which may take the form of autonomic or peripheral axonal neuropathy or central nervous system dysfunction [2]. The pathogenetic mechanisms remain unclear; metabolic abnormalities may produce diffuse neuronal dysfunction. MRI studies have suggested that ischaemic vasculopathy is a cause of porphyric encephalopathy [3–6]. We report serial MRI of a patient with AIP who showed cortical laminar necrosis and myelinolysis, not reported previously as consequences of an acute porphyric attack.

### Case report

A 29-year-old woman with a 6-month history of porphyria was admitted to hospital with severe abdominal pain, vomiting and constipation. She was treated with carbohydrate loading and chlorpromazine. Five days later, she suddenly became unconscious, with occasional tonic-clonic seizures. Laboratory tests showed hyponatraemia, with serum sodium 94 mEq/l. Treatment with hypertonic saline was initiated immediately and her serum sodium increased to 124 mEq/l in 2 days, but she did not make a good recovery.

Her pulse rate was 110/min and regular, blood pressure 135/75 mmHg. She opened her eyes in response to noise, but could not fix on a target or follow commands. Cranial nerves function seemed normal, but she had no spontaneous speech. There was diffuse muscle atrophy and a flaccid paralysis of the limbs; the deep tendon reflexes were symmetrically diminished.

Urinary  $\delta$ -aminolevulinic acid (ALA), PBG and porphyrin levels were markedly increased, confirming an acute attack of AIP. The 24 h urinary levels of ALA and PBG were 43 mg (normal < 4 mg) and 83 mg (normal < 2 mg), respectively. Red cell (RBC) PBG deaminase activity was low at 16.8 nmol uroporphyrin/ml RBC/h (normal  $29.2 \pm 5.34$  nmol). She had profound hyponatraemia (serum sodium 124 mEq/l). An electroencephalogram showed diffuse slowing but no epileptiform activity.



**Fig. 1 a–c** Contrast-enhanced axial T1-weighted MRI on 18th day after onset, showing gyriform enhancement of the cerebral cortex in the territory of the middle cerebral arteries. The putamina also show slight enhancement. **d–e** Axial T2-weighted images 34 days after onset, showing high signal in the striatum, thalamus and rostral basis pontis

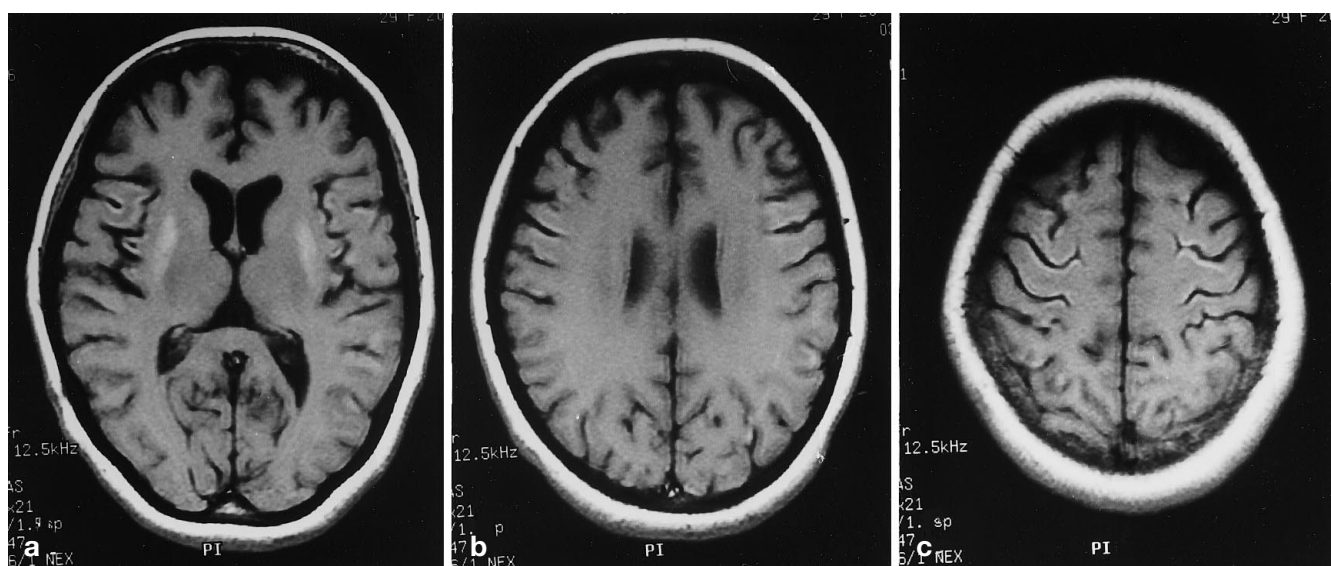
MRI, performed on the 18th day of the attack, showed no abnormal signal on T1- or T2-weighted images, but contrast-enhanced T1-weighted images revealed diffuse, predominantly gyriform cortical enhancement in the territories of the central and insular branches of the middle cerebral arteries [7], including slight enhancement of the putamina (Fig. 1a–c). On the 35th day, T2-weighted images disclosed striking increase in signal intensity in the head of the caudate nucleus, putamen, the rostral basis pontis and the thalamus bilaterally (Fig. 1d,e). On the 70th day, T1-weighted images showed high signal in the regions corresponding to the enhancing lesions described above (Fig. 2).

The patient continued on carbohydrate loading, chlorpromazine and hypertonic saline, as well as supportive therapy. Her serum sodium level recovered to 132 mEq/l in a few days, but she was still somnolent and disoriented. At 42 days after the attack, administration of haem arginate was begun, and 7 days after this she became alert and co-operative, with a mild improvement in her weakness. MRI 10 months after admission showed that the gyriform cortical lesions and a part of putamen now gave low signal on

T1- and high signal on T2-weighted images (Fig. 3a–d). No enhancing lesion was observed. The high signal on T2-weighted images was less marked in the caudate nucleus, putamen, and rostral basis pontis (Fig. 3c,e). The patient is currently able to live normally, but still has dysarthria.

## Discussion

Despite advances in the understanding of AIP, the pathophysiology of the neurological manifestations is still unclear. Two hypotheses have been proposed – neurotoxicity of ALA and haem deficiency in nervous tissue – but recent evidence suggests that multiple factors interact in causing the neurological deficits [2]. King and Bragdon [3] demonstrated cerebral cortical changes on MRI, which resolved after a few



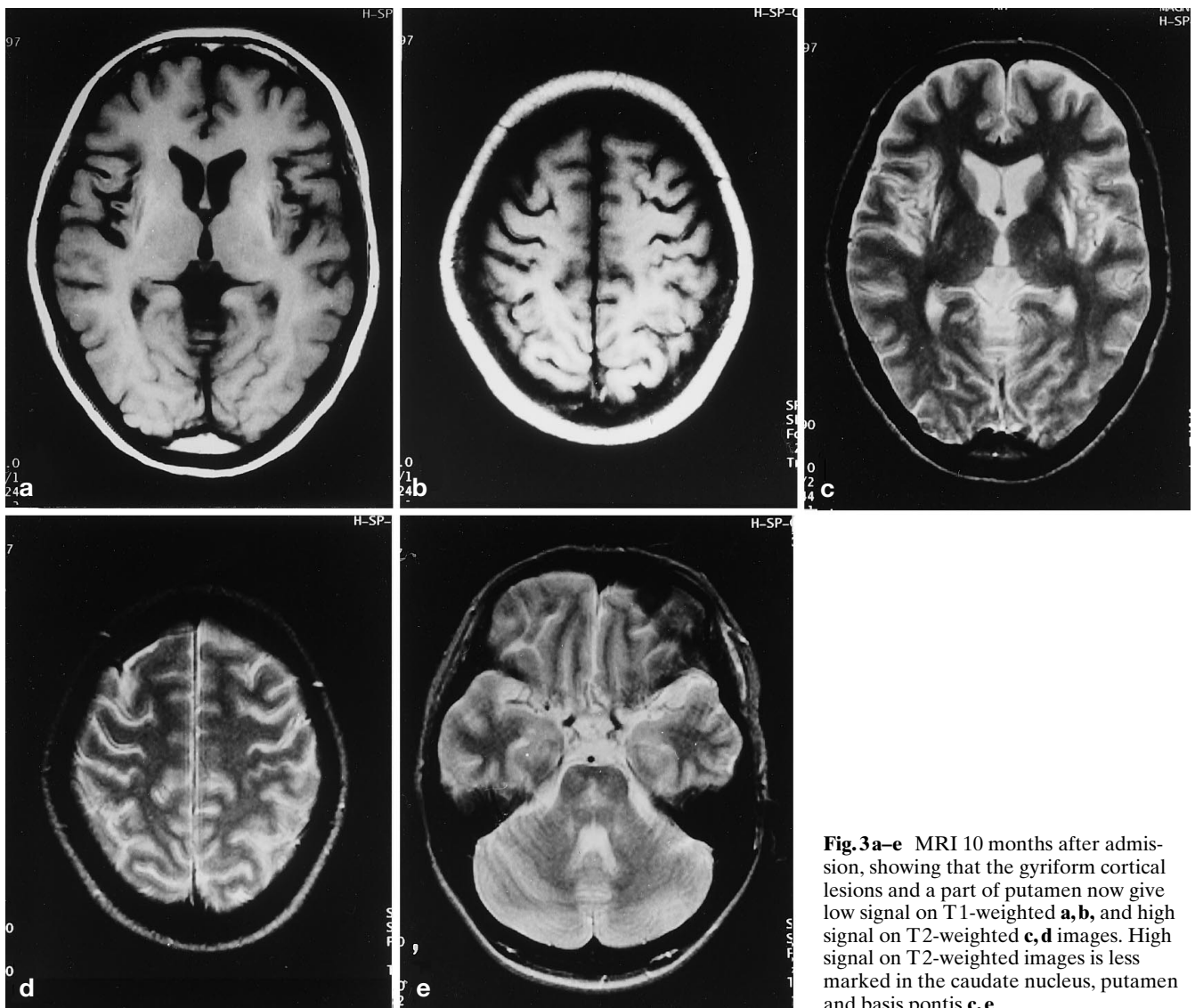
**Fig. 2a-c** Axial T1-weighted images on the 70th day showing high signal in the enhancing regions in Figure 1

days. Several groups have claimed that the neurological complications of this disease are caused by vasospasm-induced ischaemia [3–6]. In 1995, Black et al. [5] showed reversible vasospasm in porphyric encephalopathy with both MRI and conventional angiography, and Kupferschmidt et al. [6] hypothesised that severe haem deficiency might cause cerebral vasoconstriction due to a decrease in cerebral nitric oxide production.

In our patient, it seems that the MRI changes were cortical laminar necrosis resulting from hypoxia and central pontine and extrapontine myelinolysis due to rapid correction of hyponatraemia. Cortical laminar necrosis occurs as a consequence of hypoxic encephalopathy, due to ischaemia, anoxia, anaemia, histotoxicity, or hypoglycaemia [8]. Usually, at least two such factors are involved in any particular patient. In our patient, cortical laminar necrosis might possibly be due to hypoxia caused by apnoea during an attack of generalised convulsions. However, lesions caused by hypoxia are char-

acteristically predominant in the watershed zones or the parieto-occipital regions [9]. The lesions in our patient were restricted to the territory of the middle cerebral arteries. Ischaemia induced by vasospasm due to the porphyric encephalopathy therefore seems a more likely cause of the cortical laminar necrosis.

Hyponatraemia is sometimes observed in porphyric attacks and is associated with inappropriate antidiuretic hormone secretion [10] or infusion of hypotonic fluids. Our patient's serum sodium fell to 94 mEq/l and treatment with hypertonic saline was started immediately; her serum sodium was increased by 30 mEq/l for 2 days. There have been many reports of rapid correction of hyponatraemia causing demyelination in the pons and sometimes in the caudate nucleus and putamen. Stern et al. [11] reported that an increase in serum sodium by 12 mEq/l or more within 24 h tends to provoke myelinolysis. MRI has been effective in showing such lesions as low intensity on T1- and high intensity on T2-weighted images [12]. We therefore think that our patient suffered from myelinolysis in the pons and corpus striatum following the rapid correction of her hyponatraemia.



**Fig. 3a–e** MRI 10 months after admission, showing that the gyriform cortical lesions and a part of putamen now give low signal on T1-weighted **a, b**, and high signal on T2-weighted **c, d** images. High signal on T2-weighted images is less marked in the caudate nucleus, putamen and basis pontis **c, e**

## References

1. Kappas A, Sassa S, Galbraith RA, Nordmann Y (1989) The porphyrias. In: Scriver CR, Beaudet WS, Vale SD (eds) *The metabolic basis of inherited disease*, 6th edn. McGraw-Hill, New York, pp 1305–1365
2. Meyer UA, Schuurmans MM, Lindberg RP (1998) Acute porphyrias: pathogenesis of neurological manifestations. *Semin Liver Dis* 18: 43–52
3. King PH, Bragdon AC (1991) MRI reveals multiple reversible cerebral lesions in an attack of acute intermittent porphyria. *Neurology* 41: 1300–1302
4. Aggarwal A, Quint DJ, Lynch JP 3rd (1994) MR imaging of porphyric encephalopathy. *AJR* 162: 1218–1220
5. Black KS, Mirsky P, Kalina P, Greenberg RW, Drehobl KE, Sapan M, Meikle E (1995) Angiographic demonstration of reversible cerebral vasospasm in porphyric encephalopathy. *AJNR* 16: 1650–1652
6. Kupferschmidt H, Bont A, Schnorf H, Landies T, Walter E, Peter J, Krahenbuhl S, Meier P (1995) Transient cortical blindness and bioccipital brain lesions in two patients with acute intermittent porphyria. *Ann Intern Med* 123: 598–600
7. Damasio H (1983) A computed tomographic guide to the identification of cerebral vascular territories. *Arch Neurol* 40: 138–142
8. Brierley JB, Graham DL (1984) Hypoxia and vascular disorders of the central nervous system. In: Adams JH, Corsellis JAN, Duchen LW (eds) *Greenfield's neuropathology*, 4th edn. Edward Arnold, London, pp 125–156

- 
9. Takahashi S, Higano S, Ishii K, Matsumoto K, Sakamoto K, Iwasaki Y, Suzuki M (1993) Hypoxic brain damage: cortical laminar necrosis and delayed changes in white matter at sequential MR imaging. *Radiology* 189: 449–456
  10. Suarez JJ, Cohen ML, Larkin J, Kernich CA, Hricik DE, Daroff RB (1997) Acute intermittent porphyria: clinicopathologic correlation. *Neurology* 48: 1678–1683
  11. Sterns RH, Riggs JE, Schochet SS (1986) Osmotic demyelination syndrome following correction of hyponatremia. *N Engl J Med* 314: 1535–1542
  12. Dickoff DJ, Raps M, Yahr MD (1988) Striatal syndrome following hyponatremia and its rapid correction. *Arch Neurol* 45: 112–114