

S. Flacke
U. Wüllner
E. Keller
F. Hamzei
H. Urbach

Reversible changes in echo planar perfusion- and diffusion-weighted MRI in status epilepticus

Received: 2 July 1999
Accepted: 13 July 1999

S. Flacke (✉) · E. Keller · H. Urbach
Department of Radiology,
University of Bonn,
Sigmund-Freud-Strasse 25,
53105 Bonn, Germany
e-mail: flacke@uni-bonn.de,
Tel.: + 49-228-2875960,
Fax: + 49-228-2875598

U. Wüllner · F. Hamzei
Department of Neurology,
University of Bonn,
Sigmund-Freud-Strasse 25,
53105 Bonn, Germany

Abstract Perfusion imaging (PI) demonstrated increased perfusion and diffusion-weighted imaging (DWI) showed high signal limited to the left temporoparietal cortex in a 68-year-old man with nonconvulsive status epilepticus. The EEG showed a slow delta-wave focus. The patient recovered and PI, DWI and EEG changes completely resolved.

Key words Status epilepticus · Magnetic resonance imaging, diffusion-weighted · Perfusion

Introduction

Diffusion-weighted imaging (DWI) and perfusion imaging (PI) can be used to detect and monitor the evolution of ischaemic brain damage [1–3]. A reduction of the apparent diffusion coefficient (ADC) shortly after the onset of ischaemia appears to be closely related to intracellular water accumulation (cytotoxic oedema) secondary to a disturbance of the cellular energy metabolism and ion homeostasis [3]. DWI changes with reversible or irreversible reduction in ADC have been associated with electrical brain activity in animal models [4–6]. Recently, Wiesmann et al. [7] and Landsberg et al. [8] described four patients with status epilepticus and associated abnormalities on DWI, conventional MRI and MR angiography. Local hyperperfusion of brain parenchyma during epileptic activity has been demonstrated with single-photon emission computed tomography (SPECT) and MRI [8–10]. However, combined use of the MRI techniques in status epilepticus has not, to our knowledge, been described. We report a patient

with nonconvulsive status epilepticus clinically resembling acute ischaemic stroke with documented reversible changes in the ADC, DWI and PI.

Case report

A 68-year old man was admitted 3 h after onset of echolalia, paraphasia, and paresis of the right arm and leg. His medical history was notable for a myocardial infarct. Signs of receptive and motor dysphasia with stereotyped answers, weakness of the right arm and spontaneous movements of the right leg were found. Cranial nerve function appeared intact. With a working diagnosis of acute stroke; CT was performed but was normal. MRI at 1.5T demonstrated a high-signal focus in the left temporoparietal cortex on isotropic single-shot spin-echo echo-planar DWI (TR/TEd 4400, 85 ms; b = 1000 s/mm²) (Fig. 1). Region-of-interest measurements on reconstructed ADC trace images revealed an 18% decrease (paired *t*-test: *P* < 0.001) in the apparent ADC (0.75×10^{-9} m²/s) compared to the unaffected right side (ADC = 0.92×10^{-9} m²/s). Statistical analysis showed no difference in the ADC in the underlying white matter. Echo-shifted 3D-susceptibility-based perfusion imaging (TR/TE/α 18, 25 ms/8°) showed a focal increase in regional

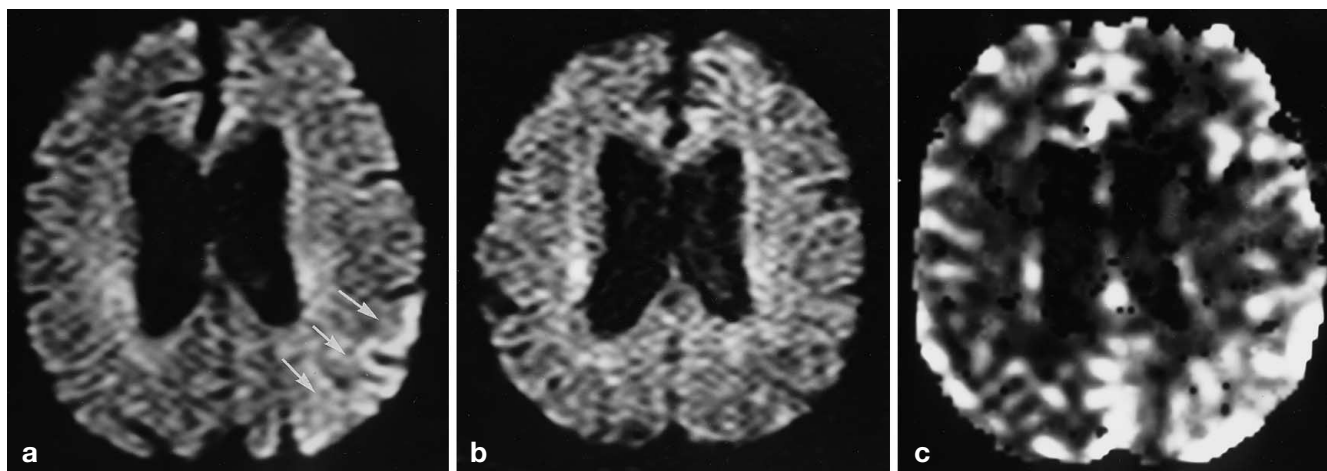


Fig. 1 **a** Initial **b** follow-up isotropic diffusion-weighted images show a completely reversible high-signal focus in the left temporoparietal region (*arrows*). **c** The reconstructed parameter map of the initial 3D-susceptibility-based perfusion imaging demonstrates increased regional cerebral blood flow index in the same area. Larger regional blood flow indices are shown as brighter colours

cerebral blood volume (rCBV; affected side/unaffected side = 1.48) with normal to slightly increased mean transit time, resulting in an 28% increased relative cerebral blood flow index (paired *t*-test: $P < 0.001$) (Fig. 1). T2-weighted imaging, including FLAIR and 3D time of flight MRA were normal. An electroencephalogram (EEG) showed slow delta-wave activity in the left temporoparietal region with multiple sharp- and sharp-slow waves (Fig. 2). The patient soon recovered with anticonvulsive treatment (mephenytoin and clonazepam) and the EEG improved continually. EEG 1 month later was completely normal, as was follow-up MRI, including DWI and PI.

Discussion

We have described reversible changes in the ADC and evidence of increased perfusion in the area of the discharging cortex in a patient with status epilepticus (s.e.). This is, to our knowledge, the first report of combined DWI and PI in s.e. These observations help to differentiate s.e. from acute nonreperfused stroke, in which a reduction in the rCBV and a prolonged mean transit time corresponding to the initial ADC reduction are commonly observed.

Early changes in ADC and reversible high signal on DWI have been described in different animal models and in humans with epilepsy [4–8]. The maximum decline in ADC in s.e. induced by inhalation of saturated flurothyl in rats was 17% and was partially reversible with pentobarbital [4]. In humans reversible ADC reduction of more than 30% has been reported [7, 8]. In our patient the neurological deficit and the fall in ADC

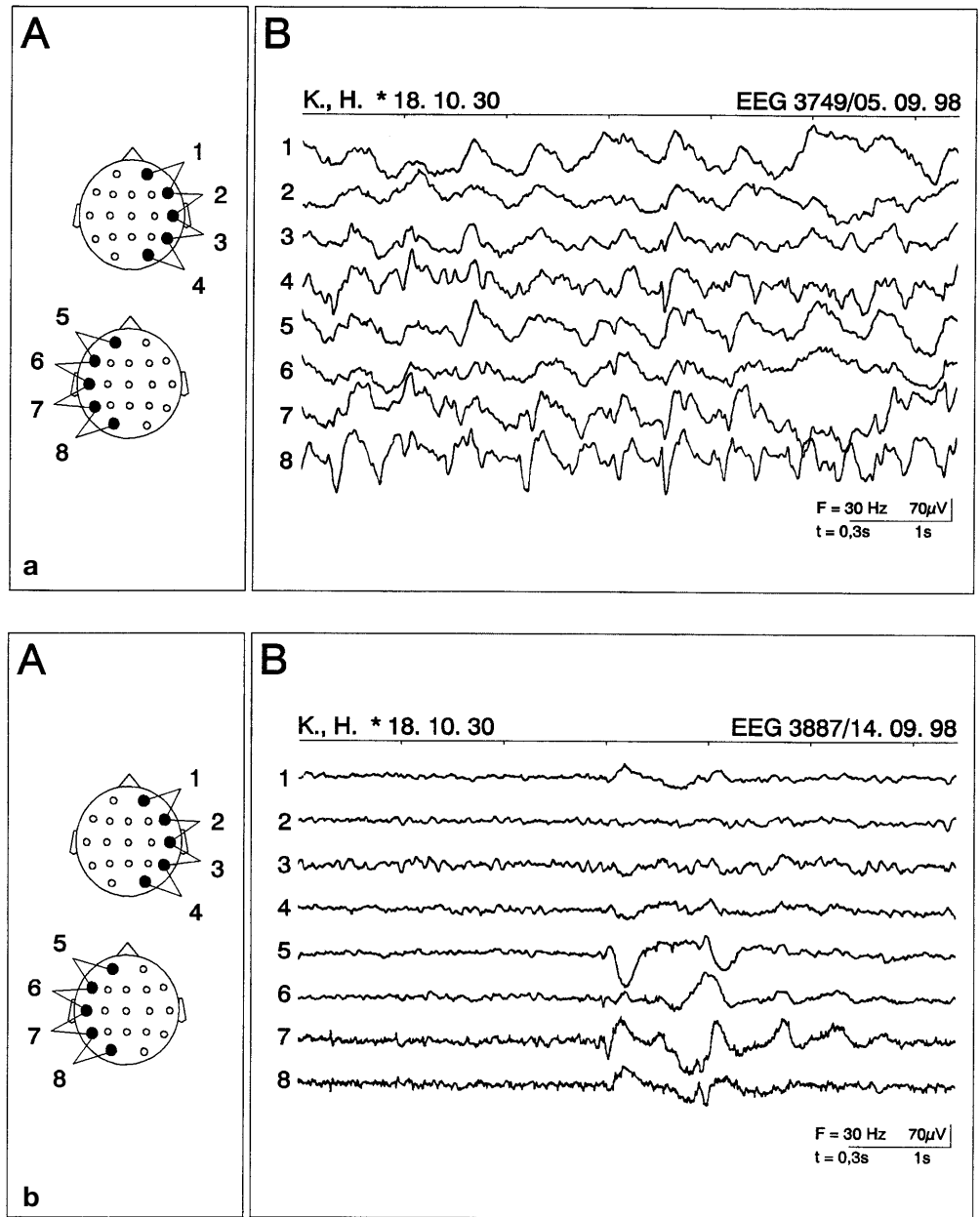
about 18% disappeared after barbiturate administration.

A correlation between the magnitude of seizure-related fall in ADC and the duration of brain activation was found in another rat model of electroshock-induced seizures. ADC decline in that model was limited to distinct areas of the brain, suggesting that they represent chronically discharging tissue [5]. The area of abnormal EEG in our patient corresponded well to the high signal on DWI. These observations are in line with the observation of substantial ADC reduction in the cortex of patients with s.e. [7, 8]. Like Lansberg et al. [8] we could not identify significant abnormalities on DWI or in ADC in the underlying white matter.

In animal studies focussing on the later phase of epilepsy, using a model of complex partial s.e. a maximum decline in ADC of 36–49% was detected. After 1 week pseudonormalisation of the ADC was observed with a persistent high sodium level and signal change on T2-weighted images presumably related to increased extracellular space and tissue necrosis [6]. Persistent small abnormalities on follow-up T2-weighted images were described in one patient [8]. The duration of our patient's s.e. was a few hours, which probably accounts for the complete recovery on follow-up. Furthermore, the lack of pathological findings on CT, T2-weighted images and MRA may also be explained by the short duration of s.e. prior to the initial examination and underlines the high sensitivity of DWI to changes in the cellular microenvironment.

The ADC changes in ischaemia and s.e. coexist with quite different profiles of cerebral blood flow (CBF) and metabolism. However, the similarity of ADC characteristics in epilepsy and cerebral ischaemia [1–3] raises the question of a common underlying mechanism. In cerebral ischaemia a significant compromise of blood supply leads to irreversible failure of energy metabolism. Sustained seizures, on the other hand, lead to increased cerebral metabolic rate for

Fig. 2 a The initial EEG shows large, slow, irregular delta waves with additional spike discharges in the left temporoparietal region. **b** Nine days later, slow alpha (8/s) activity is seen, with occasional left temporoparietal delta waves



oxygen and glucose closely coupled to a measurable increase in CBF [9]. Cell energy state is maintained, given sufficient oxygen supply. The increased relative rCBF index observed in our patient suggests increased cerebral blood supply. It may be hypothesised that PI is more sensitive than MRA to these tissue perfusion changes, as we could not observe the asymmetry of the middle cerebral artery branches previously reported [8].

Cell-membrane function and ion homeostasis could account for the observed similarity of ADC change in ischaemia and s.e. In s.e. primary membrane perme-

ability undergoes significant change, with elevation of the extracellular potassium concentration and concomitant swelling of glial cells and neurones due to an increased influx of sodium, calcium and free water following the osmotic gradient [11, 12]. A decrease in extracellular compartment volume of up to 30% has been reported [7, 8, 12]. These changes in water compartmentation and permeability in s.e. are very similar to those in acute ischaemia. However, in ischaemic lesions loss of membrane potential and increased ion permeability with subsequent cell swelling irreversibly lead to cell death.

References

1. Welch KM, Windham J, Knight RA, Nagesh V, Hugg JW, Jacobs M, Peck D, Booker P, Dereski MO, Levine SR (1995) A model to predict the histopathology of human stroke using diffusion and T2-weighted magnetic resonance imaging. *Stroke* 26: 1983–1989
2. Barber PA, Darby DG, Desmond PM, Yang Q, Gerraty RP, Jolley D, Donnan GA, Tress BM, Davis SM (1998) Prediction of stroke outcome with echoplanar perfusion- and diffusion-weighted MRI. *Neurology* 51: 418–426
3. Norris DG, Nierendorf T, Leibfritz D (1994) Healthy and infarcted brain tissue studied at short diffusion times: the origins of apparent restriction and the reduction in apparent diffusion coefficient. *NMR Biomed* 7: 304–310
4. Zhong J, Petroff OA, Pleban LA, Gore JC, Prichard JW (1995) Barbiturate-reversible reduction of water diffusion coefficient in flurothyl-induced status epilepticus in rats. *Magn Reson Med* 33: 253–256
5. Zhong J, Petroff OA, Pleban LA, Gore JC, Prichard JW (1997) Reversible, reproducible reduction of brain water apparent diffusion coefficient by cortical electroshocks. *Magn Reson Med* 37: 1–6
6. Wang Y, Majors A, Najm I, Xue M, Comair Y, Modic M, Ng TC (1996) Postictal alteration of sodium content and apparent diffusion coefficient in epileptic rat brain induced by kainic acid. *Epilepsia* 37: 1000–1006
7. Wieshmann UC, Symms MR, Shorvon SD (1997) Diffusion changes in status epilepticus. *Lancet* 350: 493–494
8. Lansberg MG, O'Brian MW, Norbash AM, Moseley ME, Morell M, Albers GW (1999) MRI abnormalities associated with partial status epilepticus. *Neurology* 52: 1021–1027
9. Duncan R, Patterson J, Hadley D, Roberts R (1997) Ictal regional cerebral blood flow in frontal lobe seizures. *Seizure* 6: 393–401
10. Warach S, Levin JM, Schomer DL, Holman BL, Edelman RR (1994) Hyperperfusion of ictal seizure focus demonstrated by MR perfusion imaging. *AJNR* 15: 965–968
11. McNamara JO (1994) Cellular and molecular basis of epilepsy. *J Neurosci* 14: 3413–3425
12. Lux HD, Heinemann U, Dietzel I (1986) Ionic changes and alterations in the size of extracellular space during epileptic activity. *Adv Neurol* 44: 619–639