

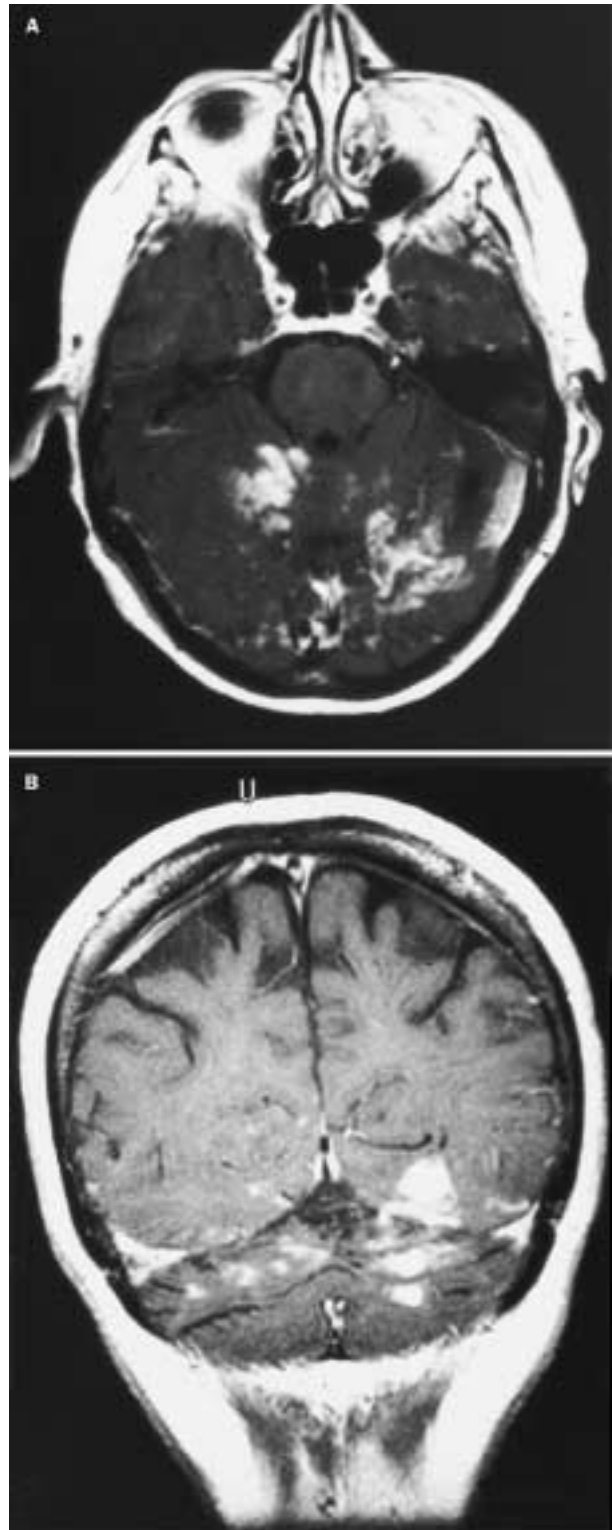
## Confused by arteritis

Martin Zeidler, Tom Hughes, Adam Zeman

A 66-year-old woman presented in June, 1998 with a 3-week history of intermittent confusion, unsteadiness, slurred speech, and fuzzy vision. She had had mild gait unsteadiness for over 1 year and for 6 months had complained of malaise and a poor appetite with 10 kg weight loss. She had had headaches for 3 weeks before admission, which she believed was a mild form of her longstanding migraine. Examination showed impaired attention and a minimal mental state examination (MMSE) score of 16/30. She was dysarthric and had a homonymous left inferior quadrantanopia. Her limbs and gait were ataxic and she needed a frame to walk. Otherwise, examination was unremarkable. Her erythrocyte sedimentation rate (ESR) was 63 mm/h. Magnetic resonance imaging (MRI) showed widespread signal changes in the cerebellar hemispheres, posterior thalamus, and occipital lobes with some enhancement with gadolinium (figure). Although the abnormalities were confined entirely to the territory of the vertebrobasilar circulation, they were not typical of thromboembolic cerebrovascular disease, and the possibilities of infiltrating cancer and central nervous system vasculitis were raised by the neuroradiologists. Cerebrospinal fluid contained 5 white blood cells per  $\mu\text{L}$ , no cancer cells and a slightly raised protein (0.62 g/L). Additional investigation failed to provide evidence for any underlying cancer, or autoimmune or infective condition, but raised serum IgA, IgG, and complement concentrations were noted. She showed no clinical or radiological improvement over the next 3 weeks and her ESR remained raised.

We considered brain biopsy, but opted for a temporal artery biopsy. The specimen showed an active arteritis characterised by a focal transmural chronic inflammatory cell infiltrate associated with intimal hyperplasia. A connective tissue stain (Elastic Van Gieson) showed extensive disruption of the intimal elastic lamina. 5 days after starting treatment with intravenous methylprednisolone, followed by oral prednisolone, her MMSE score had improved to 23/30 and she was able to walk out without aid. She continued to improve over the next 8 months. Her MMSE score when reviewed in March 1999 was 29/30; she had a mild restriction of her left visual field, slight dysarthria, and difficulty with tandem gait. Repeat MRI showed persistence of the previous abnormalities but without any contrast enhancement.

Giant-cell arteritis is a systemic inflammatory disease that typically affects the medium and large cranial arteries of patients over age 50 years.<sup>1</sup> Characteristic presenting features include headache, scalp tenderness, jaw claudication, monocular visual loss, and diplopia. These



Post-gadolinium T1-weighted axial (A) and coronal (B) images showing serpiginous bilateral enhancement of the folia of the cerebellar hemispheres (A) and the gyri of the occipital lobes (B).

were not prominent in this patient, but, in retrospect, her weight loss, malaise, and raised inflammatory markers were in keeping with the diagnosis. Stroke is an uncommon but well described complication of giant-cell arteritis, occurring in less than 5% of patients,<sup>2</sup> and often affects the vertebrobasilar circulation. It usually results from occlusion of cranial extracerebral vessels, but embolic occlusion of

*Lancet* 2000; **355**: 374

Department of Clinical Neurology, Western General Hospital, Crewe Road, Edinburgh, EH4 2XU, UK (M Zeidler MRCP, A Zeman DM); and Department of Clinical Neurology, University Hospital of Wales, Cardiff (T Hughes MD)

Correspondence to: Dr Martin Zeidler (e-mail: martinz@globalnet.co.uk)

smaller intracranial arteries may occur.<sup>3</sup> Vasculitis of small intracranial vessels has been documented to cause stroke rarely in giant-cell arteritis.<sup>1</sup> The cause of the vasculitis and the exact mechanism of thrombosis are unknown, as is the reason for the selective involvement of extracerebral arteries. Wilkinson and Russell<sup>3</sup> noted that the affected arteries tended to be rich in elastin, but the pathophysiological significance of this finding remains unclear. Our patient's confusion resulted from multiple ischaemic lesions in the vertebrobasilar circulation occurring as a result of arteritis. Her presentation with focal neurological signs and her unusual MRI appearances initially obscured the diagnosis. Similar MRI appearances have been reported in a few previous cases.<sup>1,4</sup> Our patient was fortunate to improve since established deficits following stroke due to giant-cell arteritis are seldom reversible with steroids.<sup>5</sup> Physicians should not allow themselves to be confused by arteritis: the possibility of giant-cell arteritis should always be considered in older patients with symptoms and signs of cerebral ischaemia, especially in the vertebrobasilar territory, and a raised ESR. We thank Stephen Wharton and Donald Collie for advice.

---

#### References

- 1 Buttner T, Heye N, Przuntek H. Temporal arteritis with cerebral complications: report of four cases. *Eur Neurol* 1994; **34**: 162-67.
- 2 Caselli RJ, Hunder GG, Whisnant JP. Neurologic disease in biopsy-proven giant cell (temporal) arteritis. *Neurology* 1988; **38**: 352-59.
- 3 Wilkinson IM, Russell RW. Arteries of the head and neck in giant cell arteritis. A pathological study to show the pattern of arterial involvement. *Arch Neurol* 1972; **27**: 378-91.
- 4 Collazos J, Garcia-Monco E, Martin A, Rodriguez J, Gómez MA. Multiple strokes after initiation of steroid therapy in giant cell arteritis. *Postgrad Med J* 1994; **7**: 228-30.
- 5 Caselli RJ. Giant cell (temporal) arteritis: a treatable cause of multi-infarct dementia. *Neurology* 1990; **4**: 753-55.